

# CLASSIFICATION OF THE CUTANEOUS MANIFESTATIONS OF COVID-19: A RAPID PROSPECTIVE NATIONWIDE CONSENSUS STUDY IN SPAIN WITH 375 CASES.

Supplementary material: Photographic atlas

C. Galván Casas\*, A. Català\*, G. Carretero Hernández, P. Rodríguez-Jiménez, D. Fernández Nieto, A. Rodríguez-Villa Lario, I. Navarro Fernández, R. Ruiz-Villaverde, D. Falkenhain, M. Llamas Velasco, J. García-Gavín, O. Baniandrés, C. González-Cruz, V. Morillas-Lahuerta, X. Cubiró, I. Figueras Nart, G. Selda-Enriquez, J. Romaní, X. Fustà-Novell, A. Melian-Olivera, M. Roncero Riesco, P. Burgos-Blasco, J. Sola Ortigosa, M. Feito Rodriguez, I. García-Doval

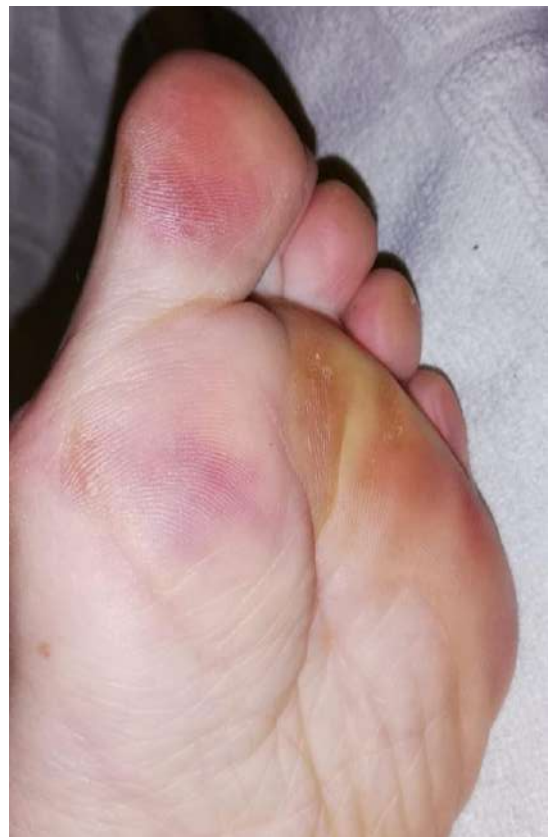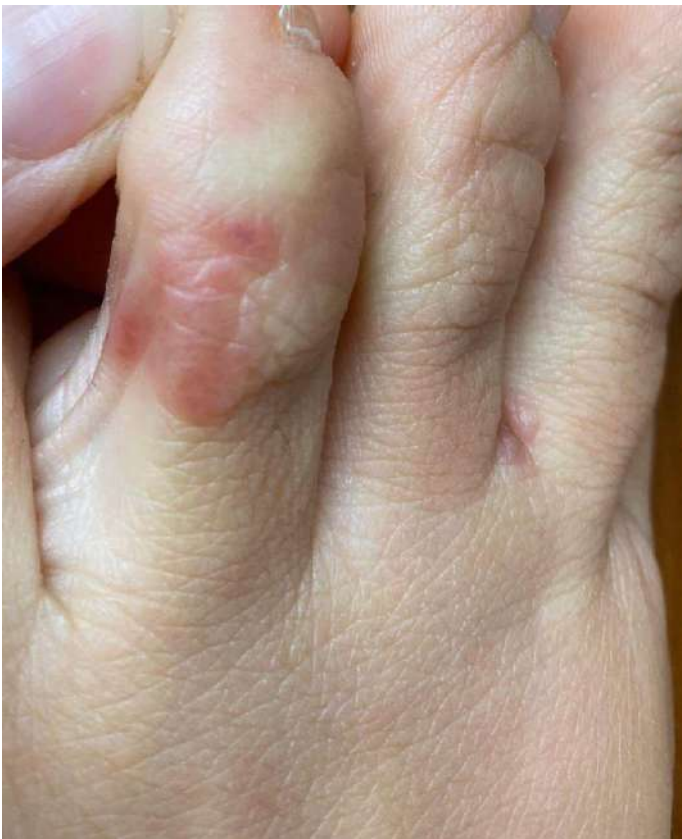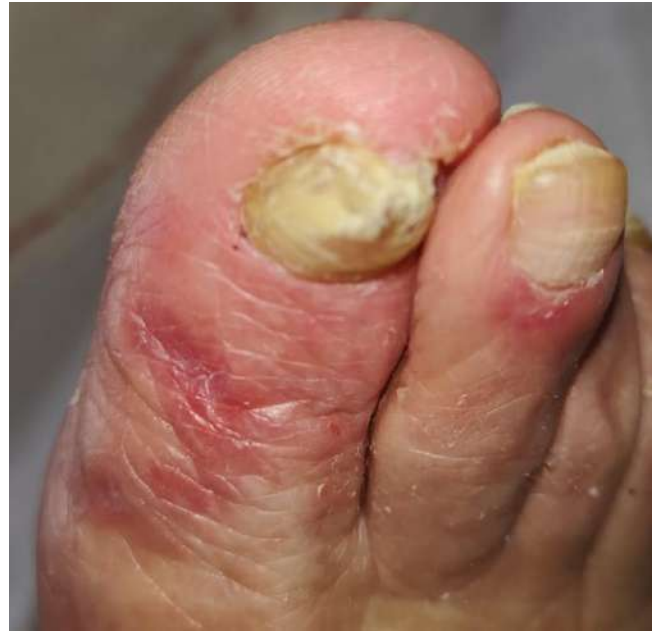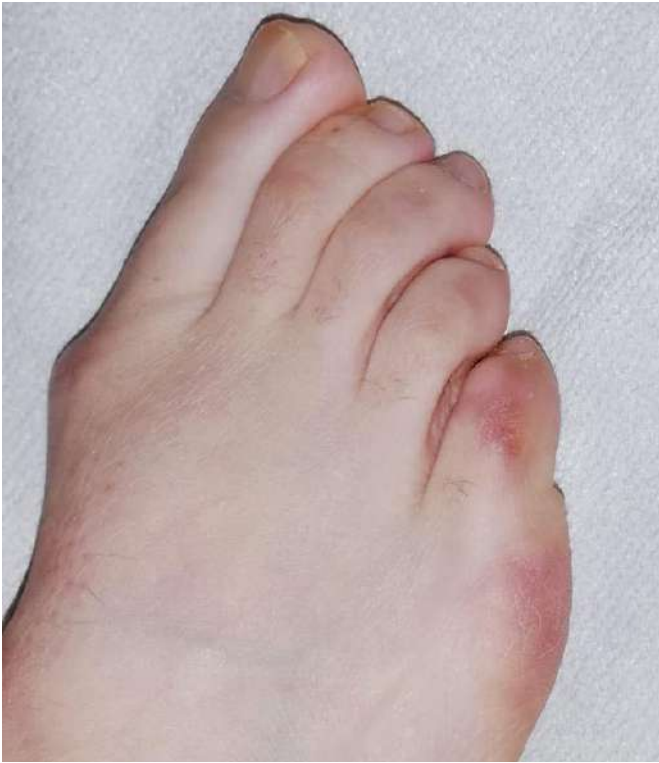British Journal of Dermatology 2020

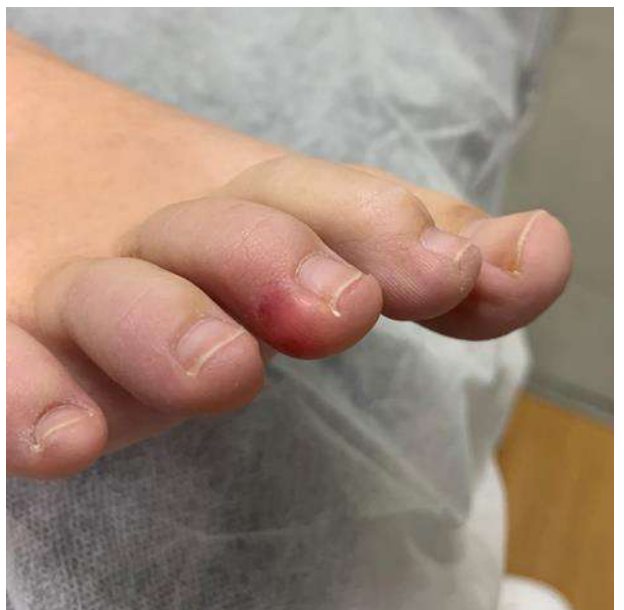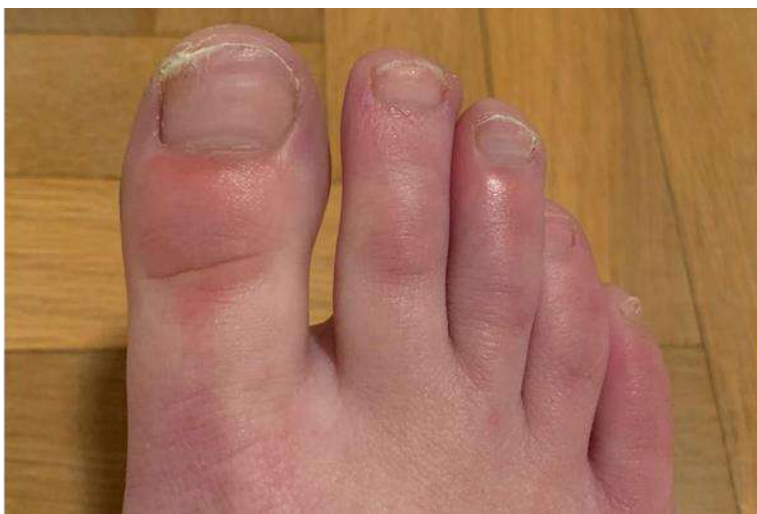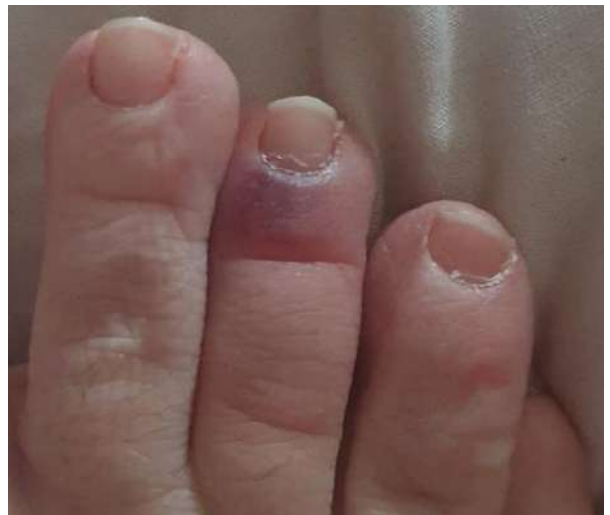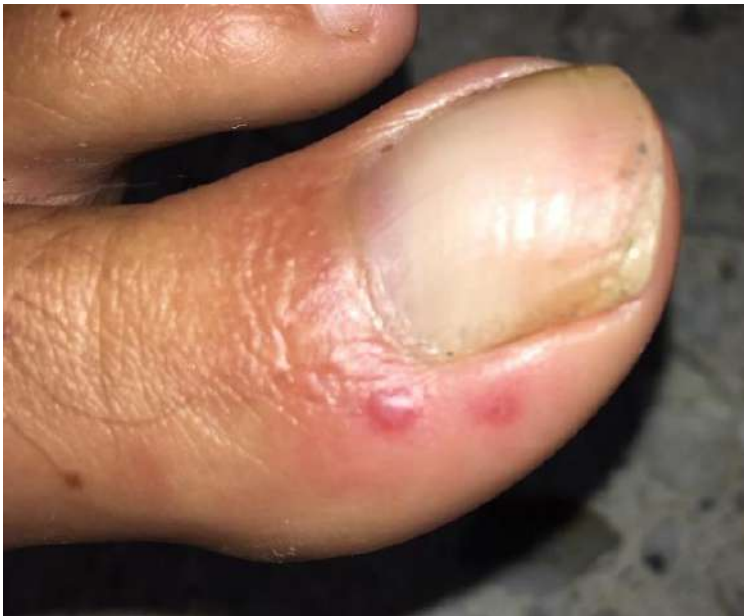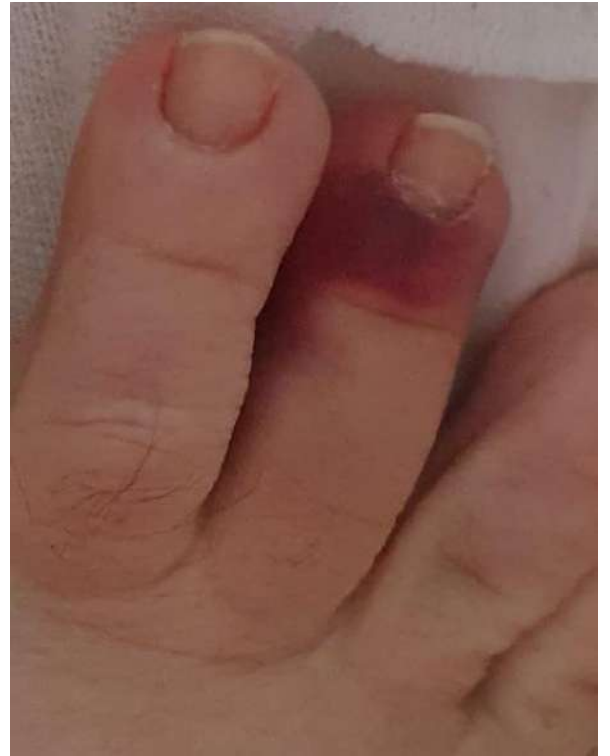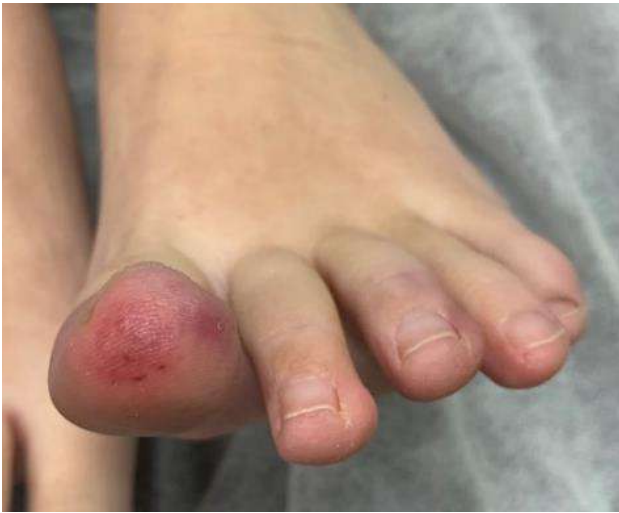©This material is subject to copyright (19th April 2020). Patients  
have authorized the reproduction for research and teaching.  
Any other use is forbidden.

## Index

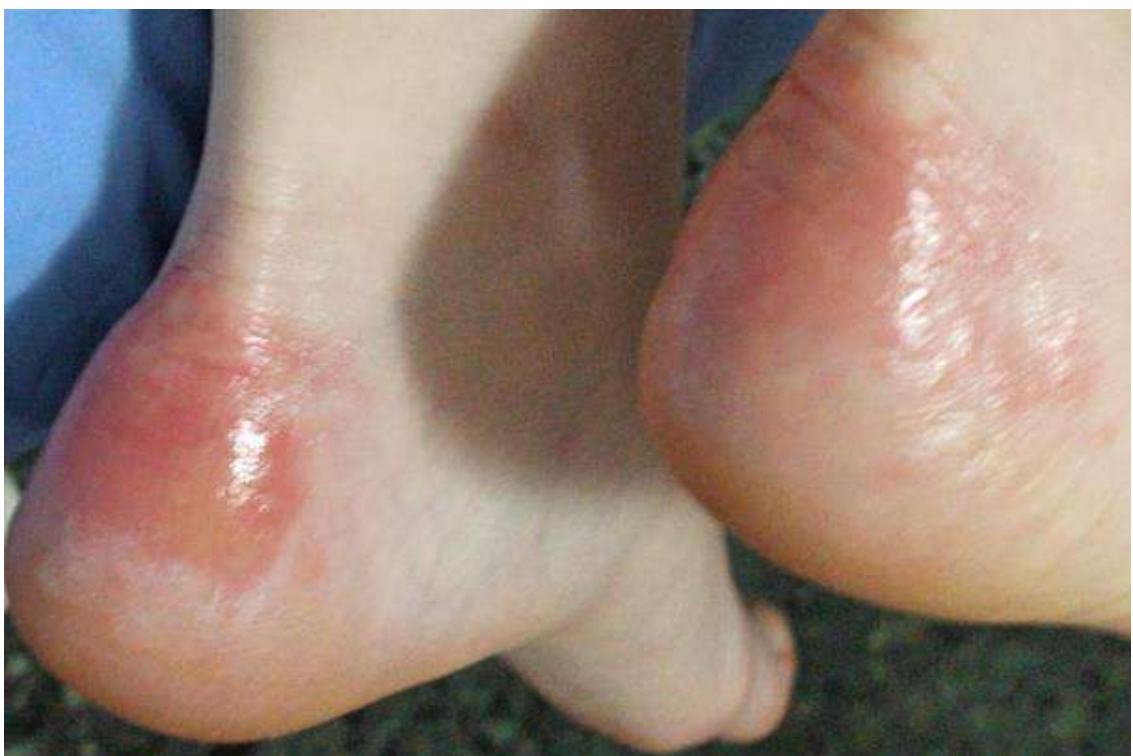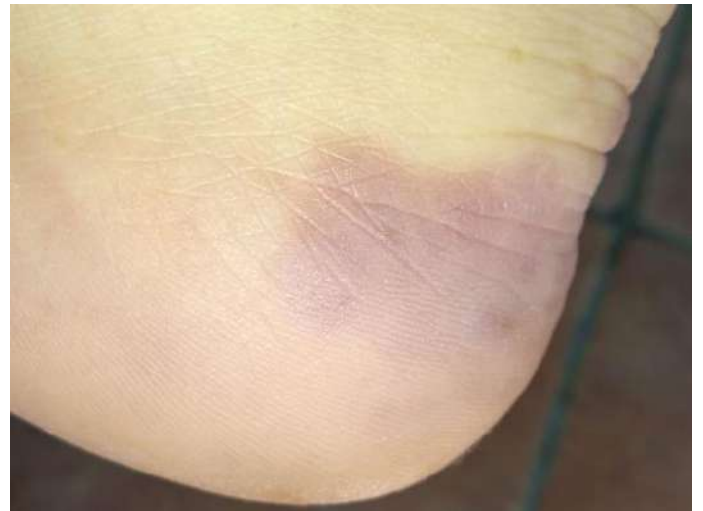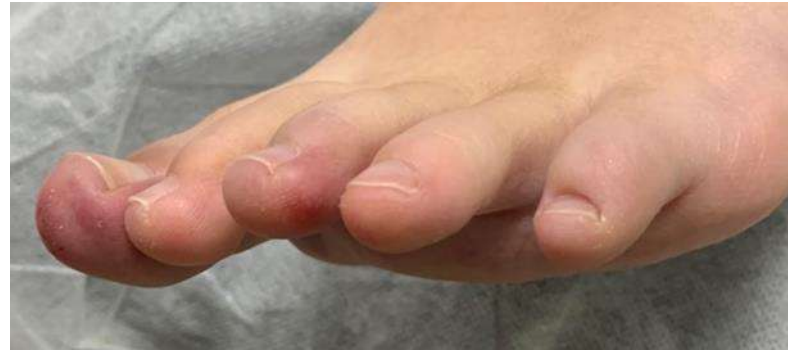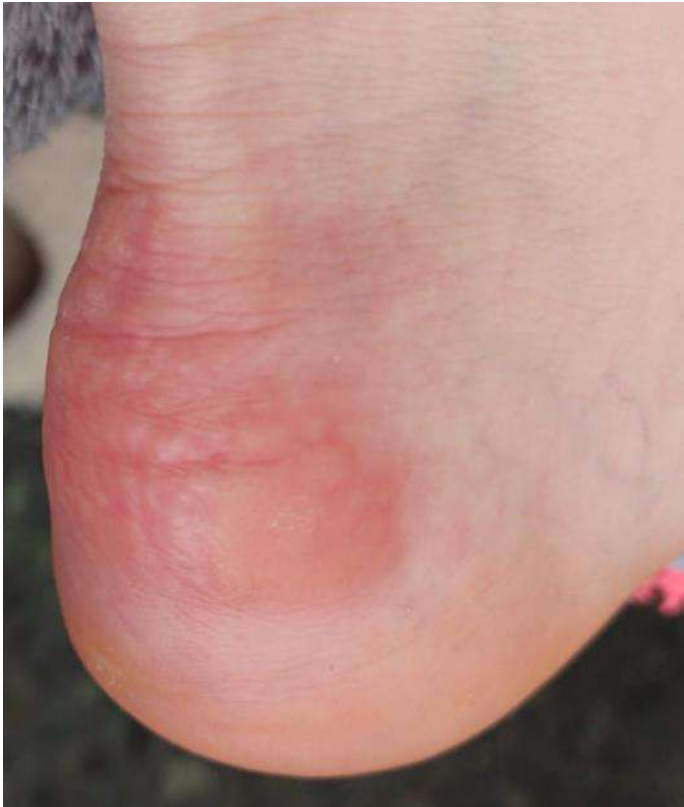Pseudo-chilblain – Confirmed cases.....	2
Pseudo-chilblain – Suspected cases .....	7
Vesicular Eruption – Confirmed cases.....	17
Vesicular Eruption – Suspected cases .....	26
Urticarial Eruption – Confirmed cases .....	39
Urticarial Eruption – Suspected cases.....	48
Maculopapular eruption – Confirmed cases.....	52
Pityriasis rosea-like .....	52
Perifollicular eruption .....	55
Erythema multiforme-like .....	57
Pseudovesicular or resembling erythema elevatum diutinum .....	59
Purpuric eruptions.....	60
Bilateral axillary purpuric eruption .....	62
Morbilliform eruptions.....	64
Palmar erythema.....	66
Erythema .....	67
Maculopapular eruption – Suspected cases .....	68
Pityriasis rosea-like.....	68
Perifollicular eruption .....	72
Erythema multiforme-like .....	74
Pseudovesicular or resembling erythema elevatum diutinum .....	77
Purpuric eruption .....	82
Bilateral axillary purpuric eruption .....	83
Morbilliform eruptions.....	84
Palmar erythema.....	86
Erythema .....	87
Livedoid or necrotic lesions - Confirmed cases.....	88
Livedoid or necrotic lesions - Suspected cases .....	94

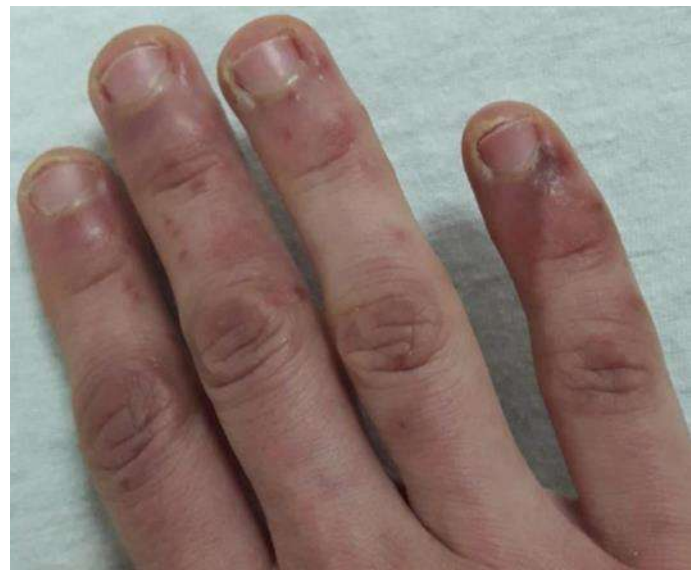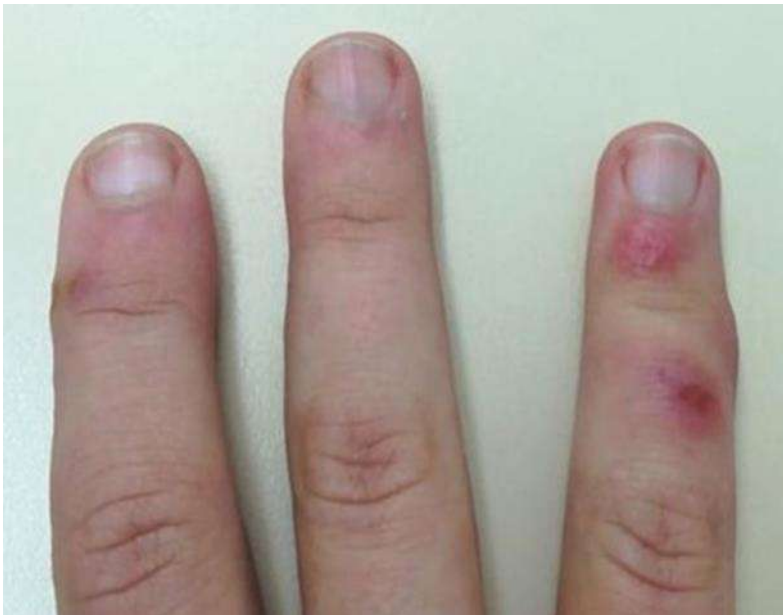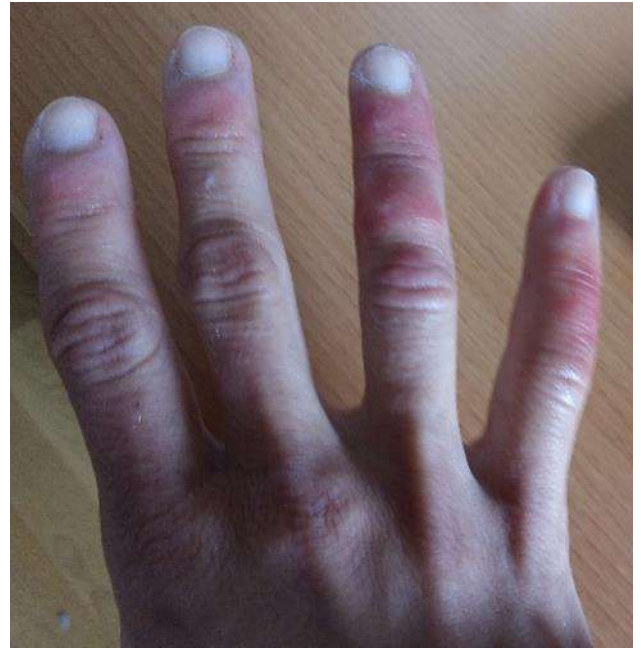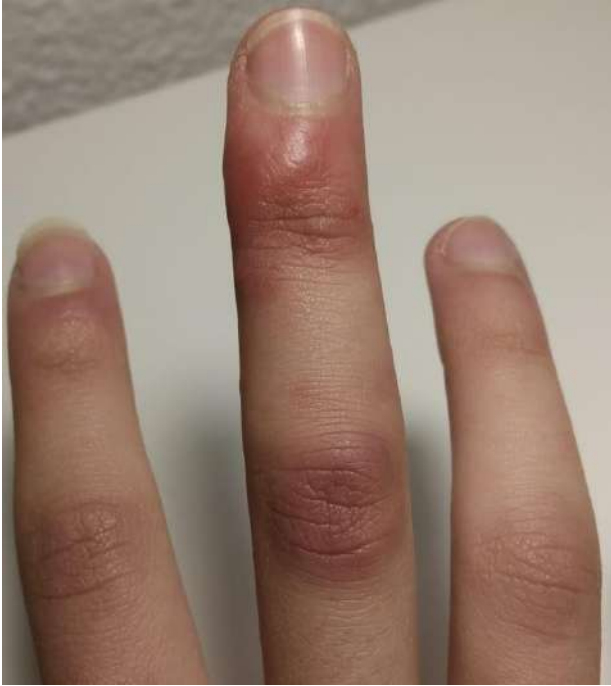## Pseudo-chilblain – Confirmed cases



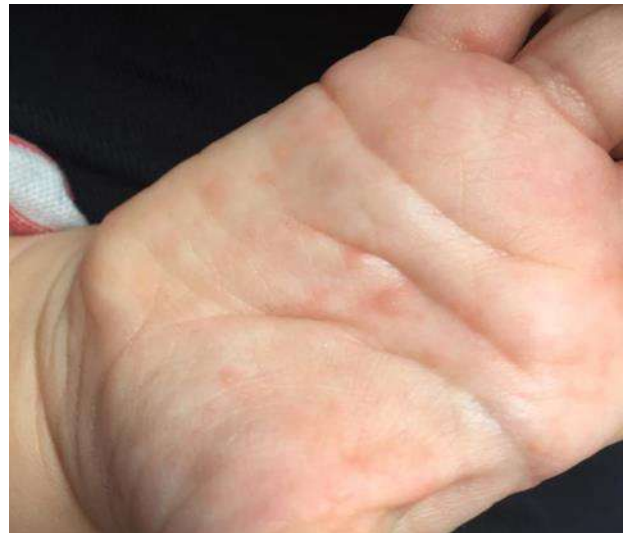
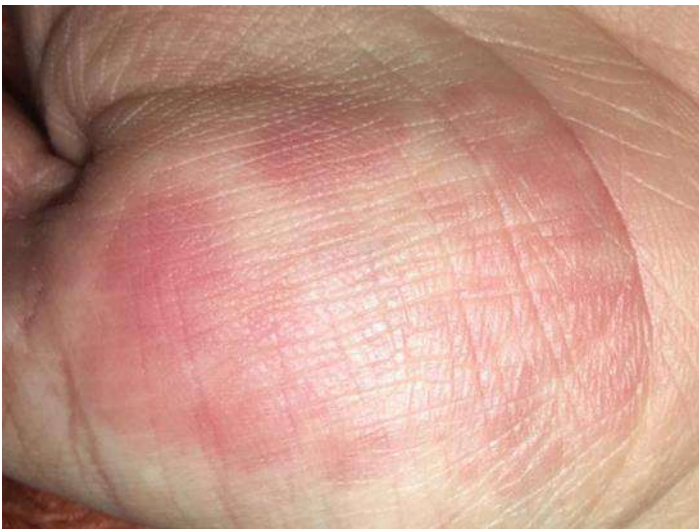
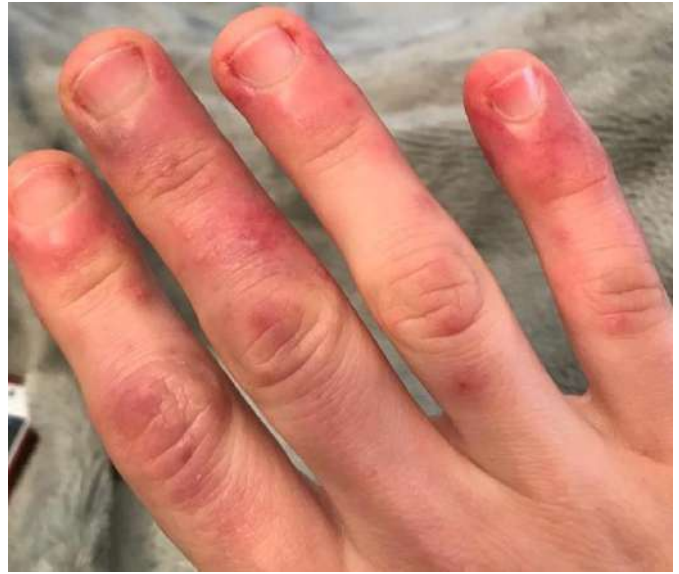
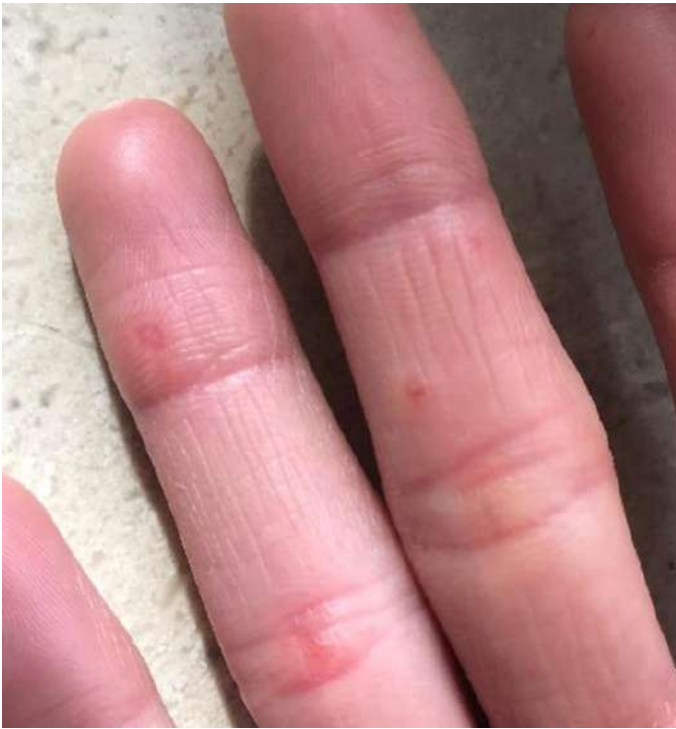




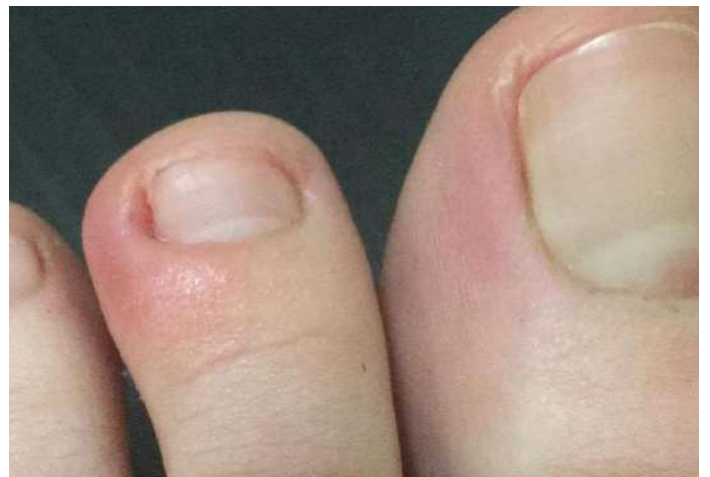
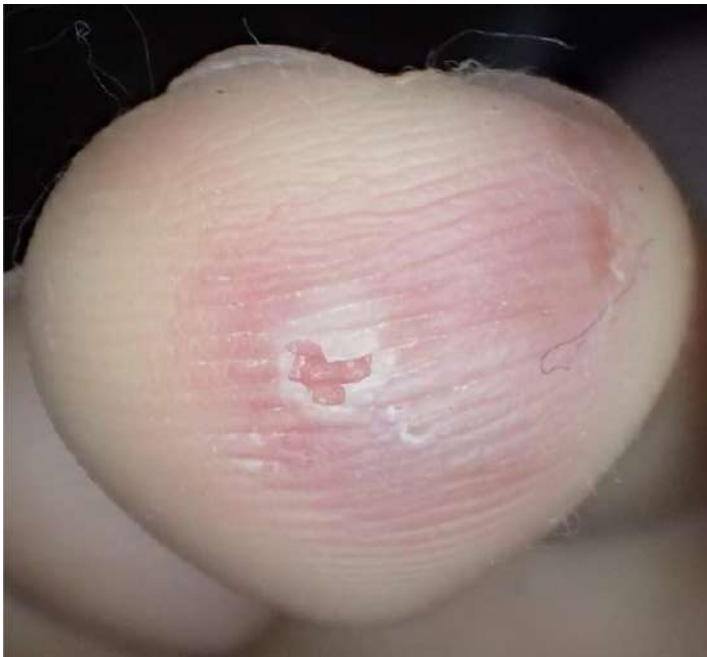
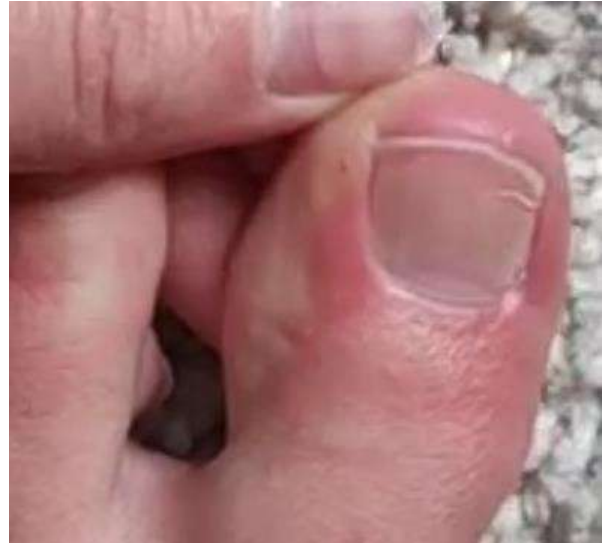
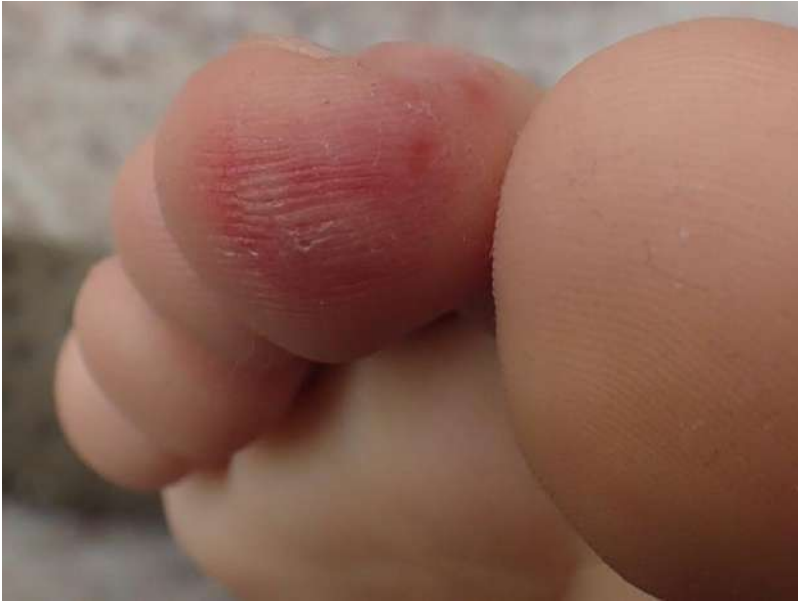
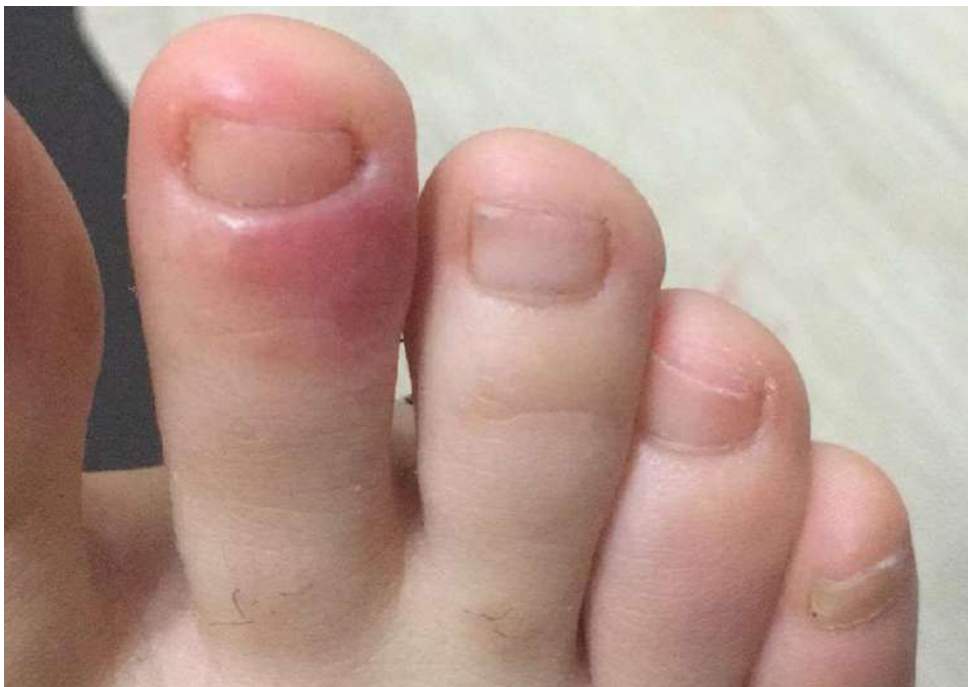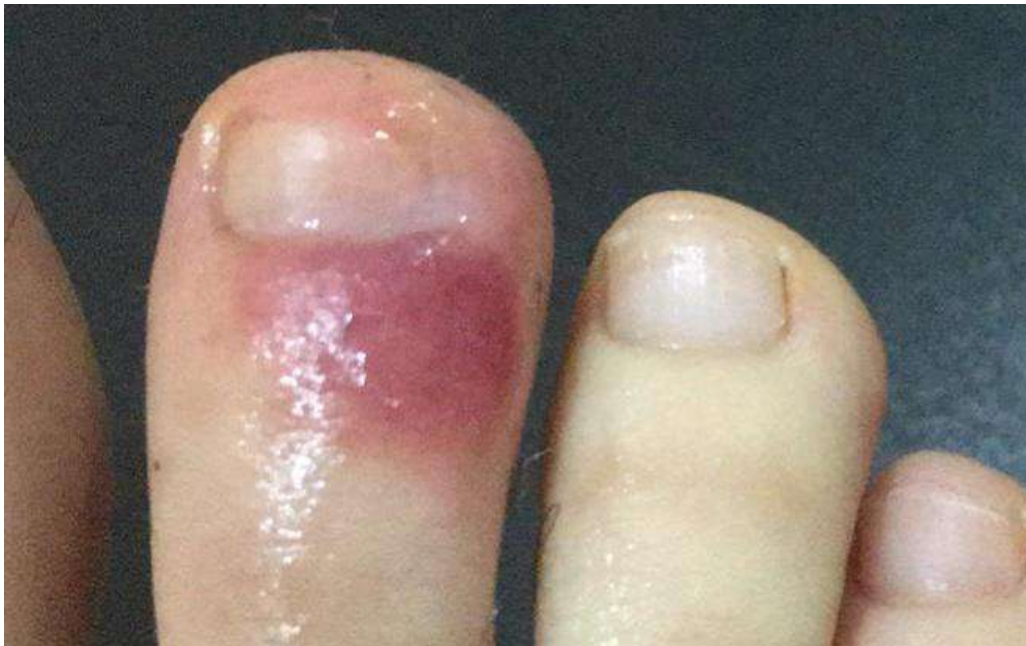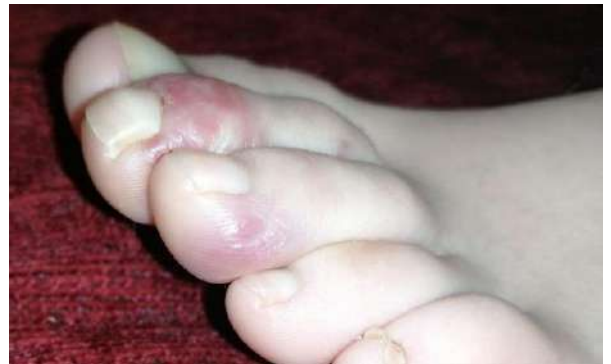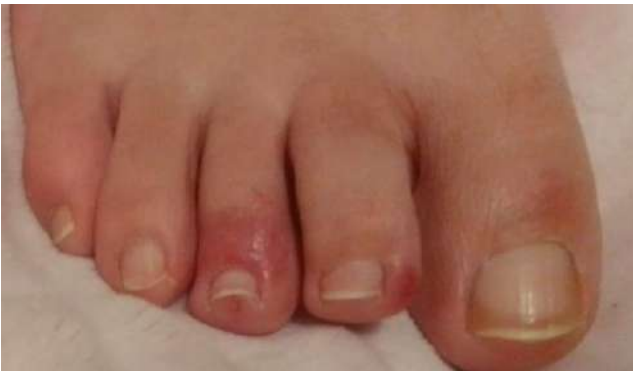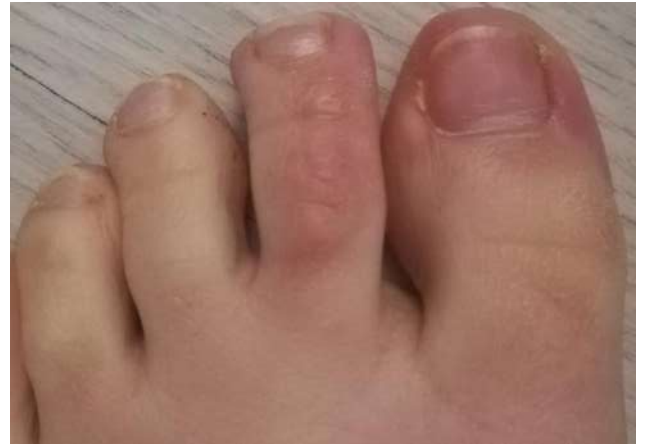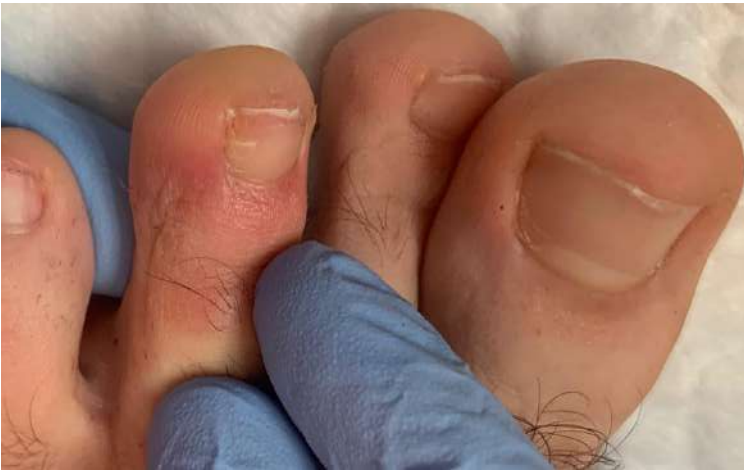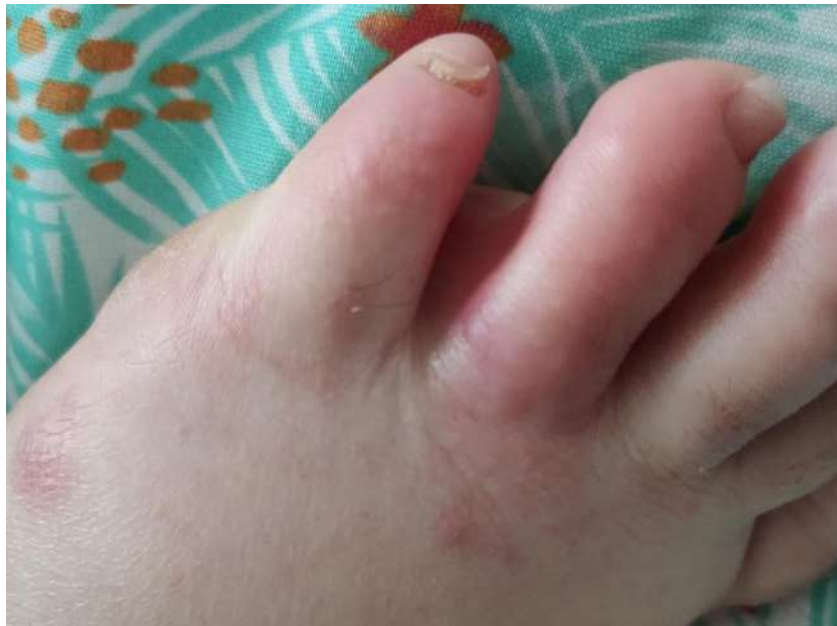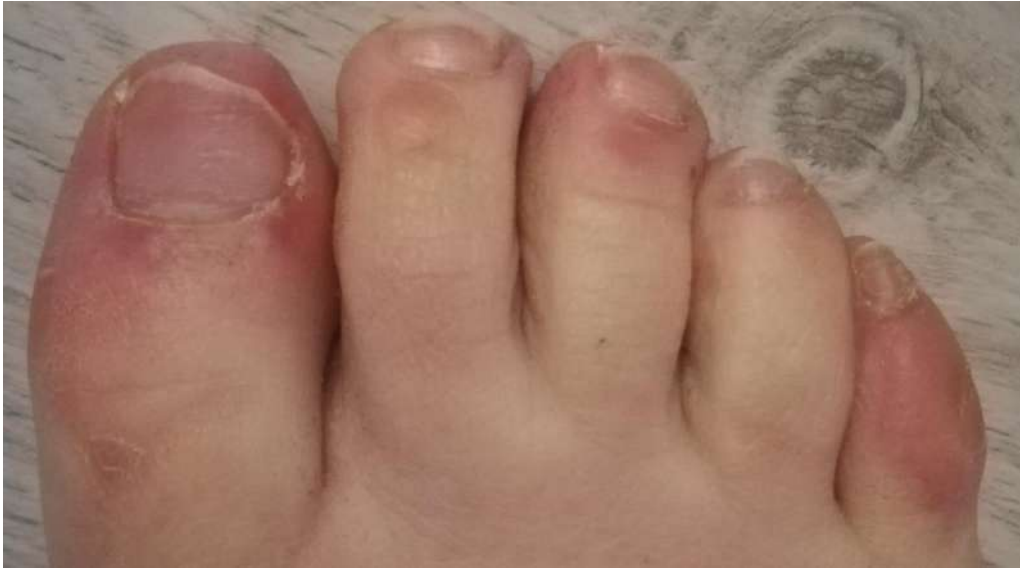## Pseudo-chilblain – Suspected cases



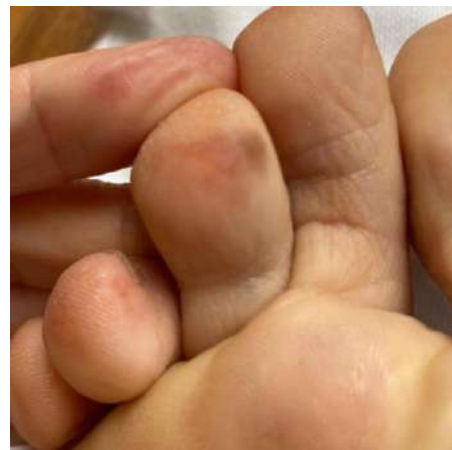
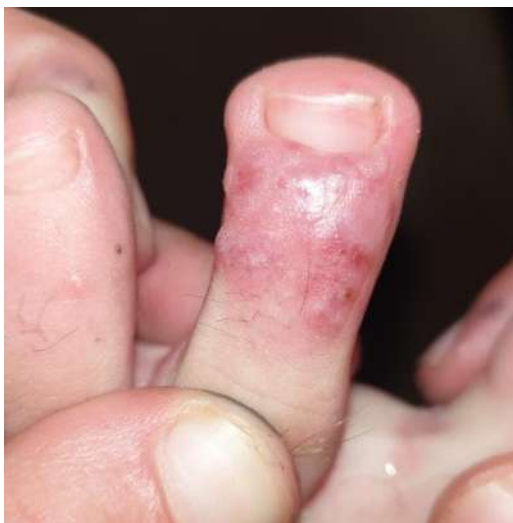
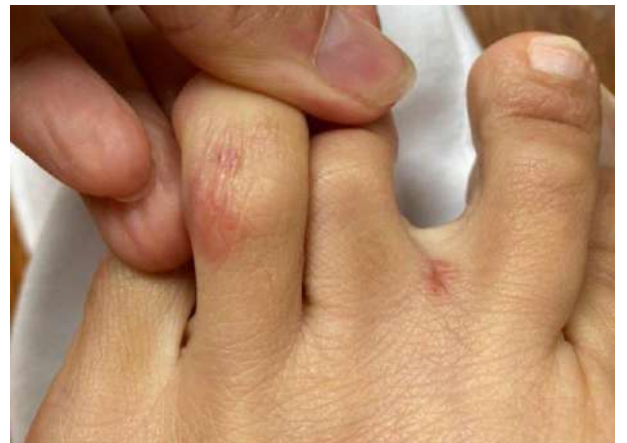
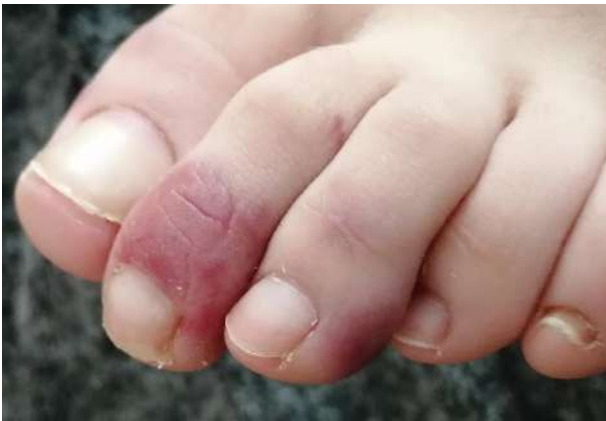
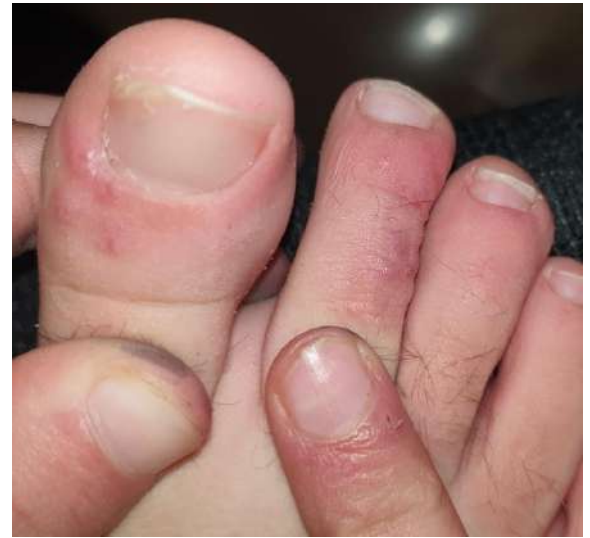
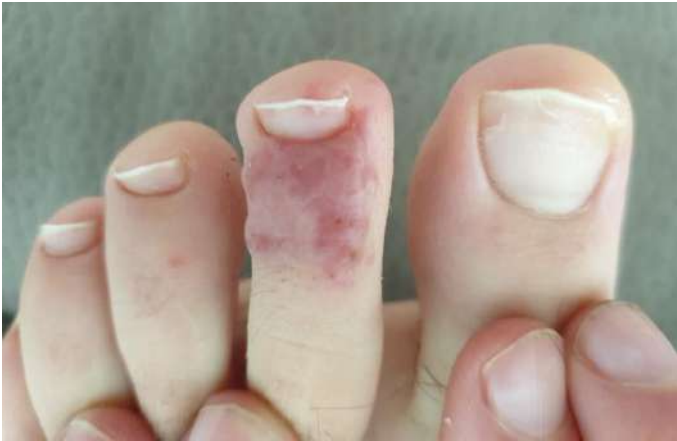


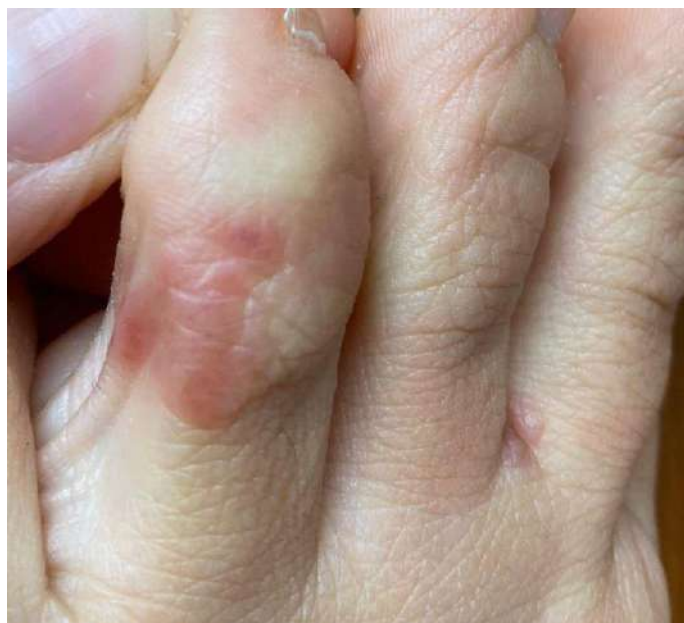
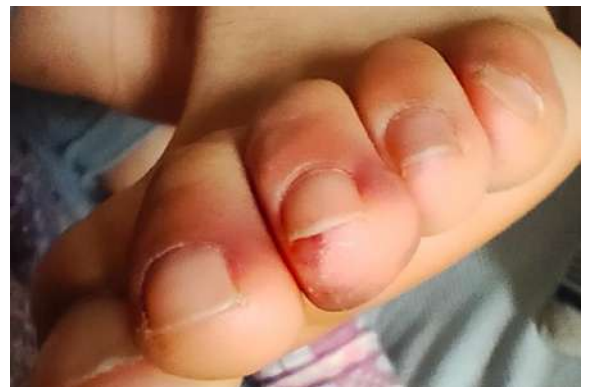
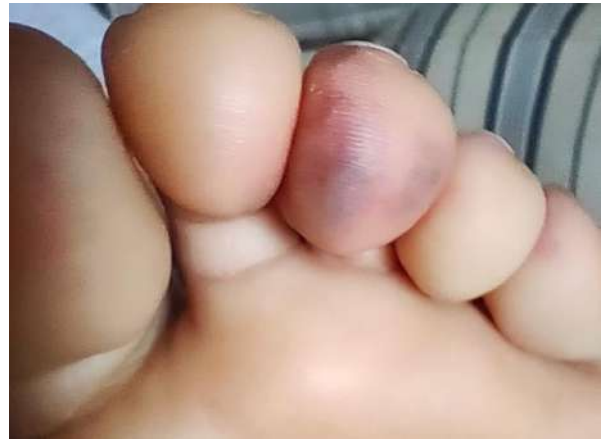
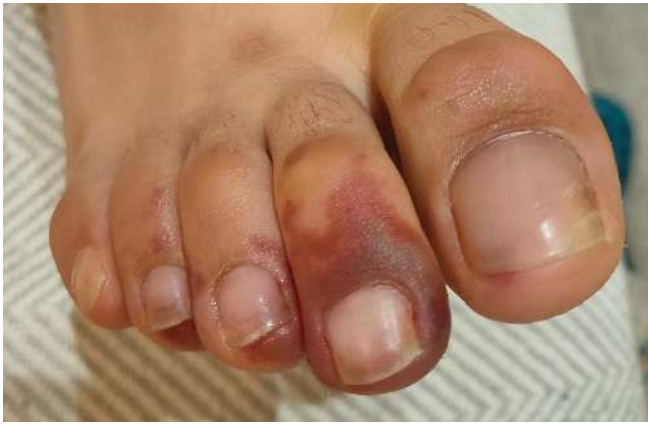


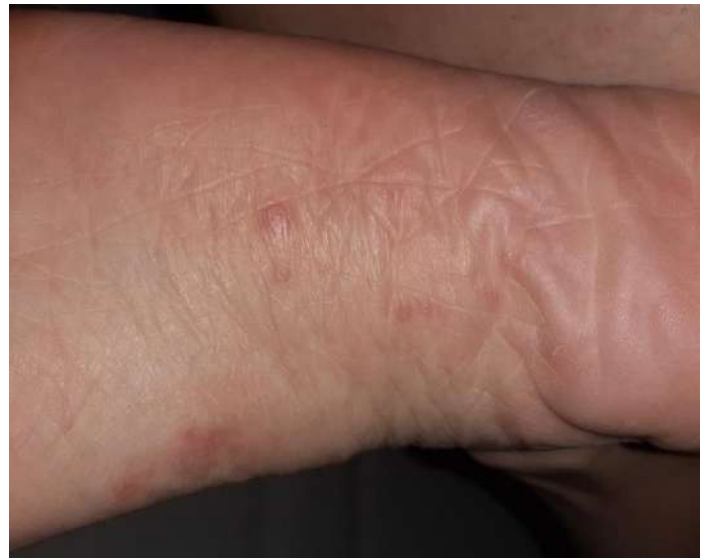
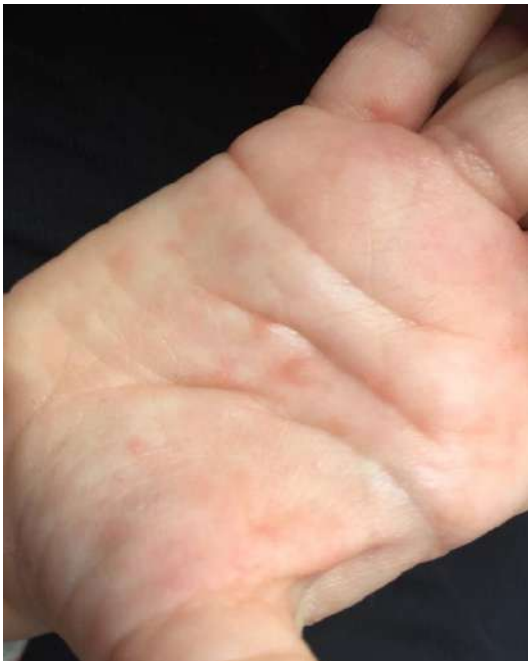
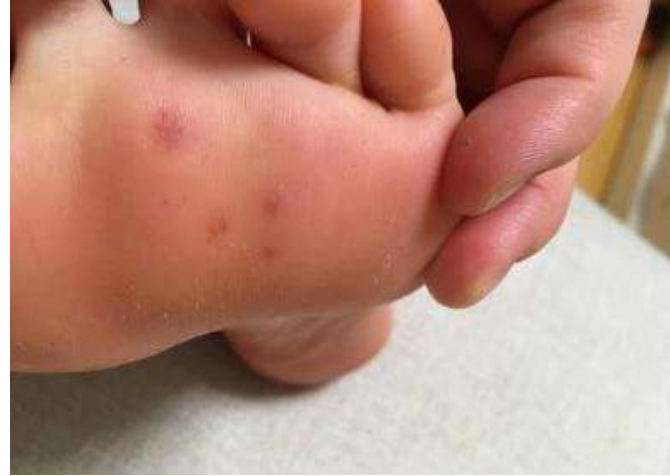
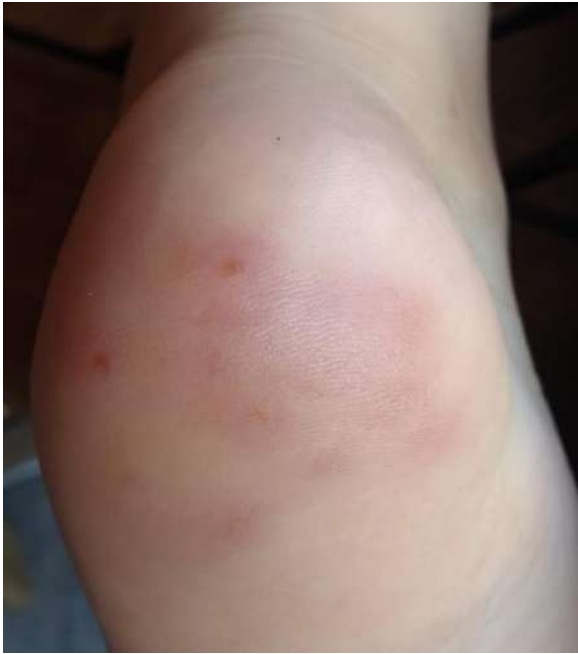




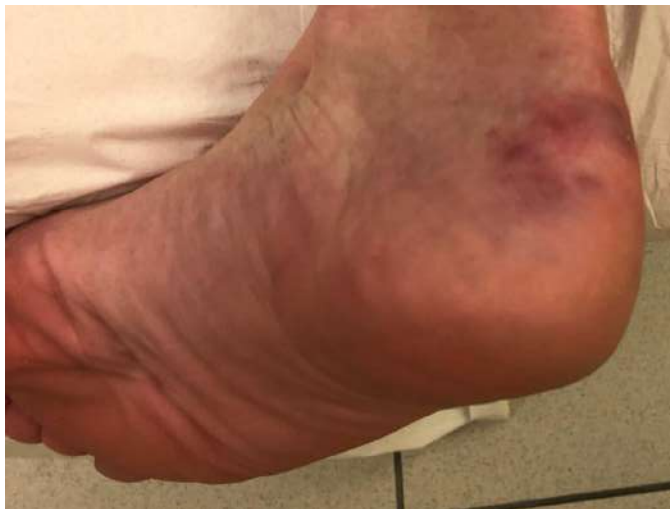
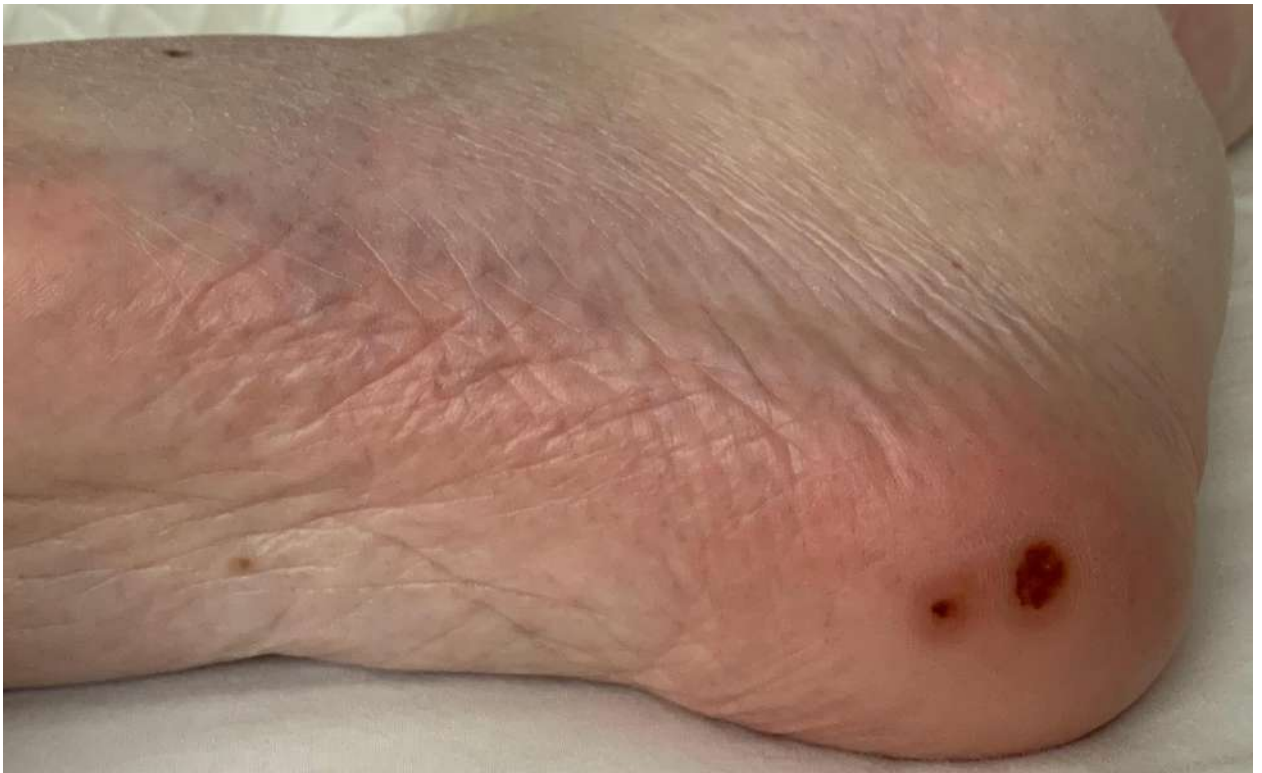


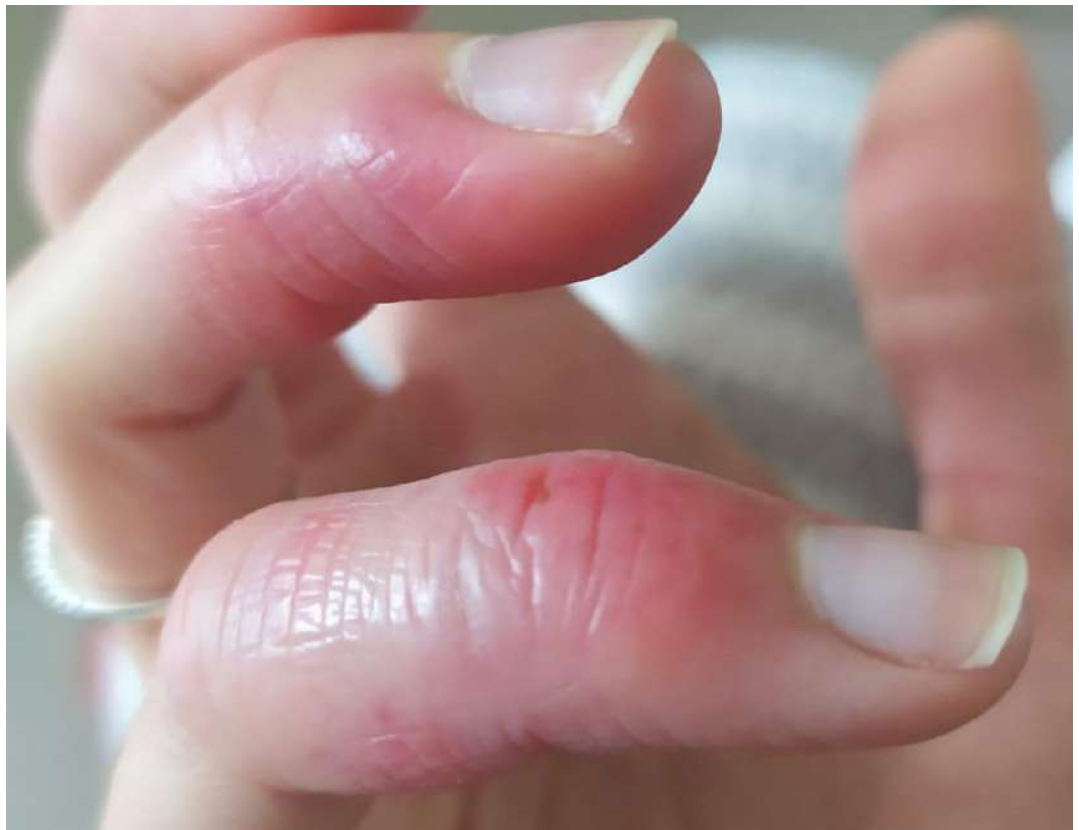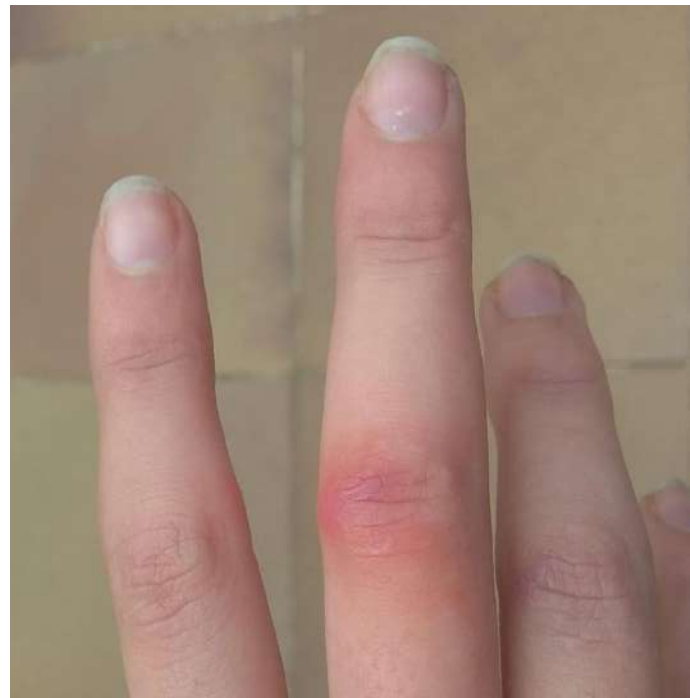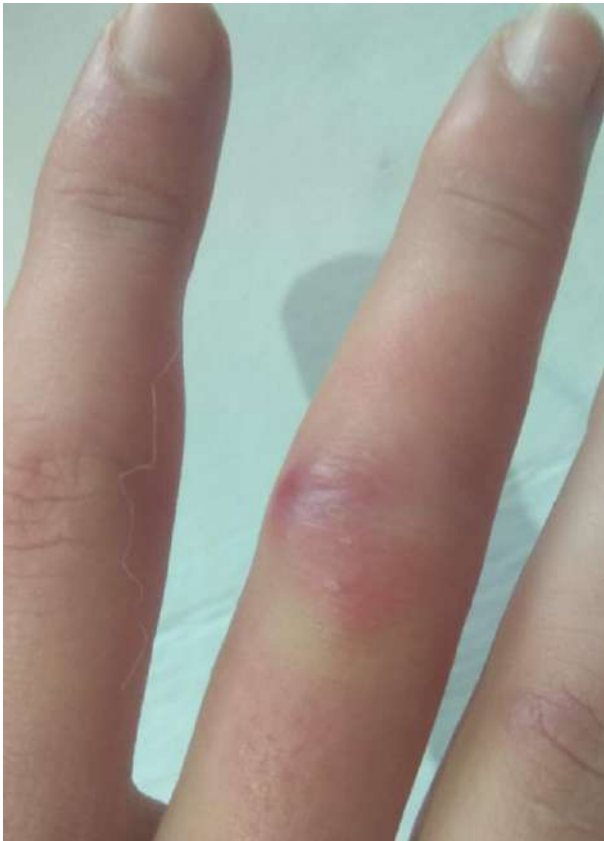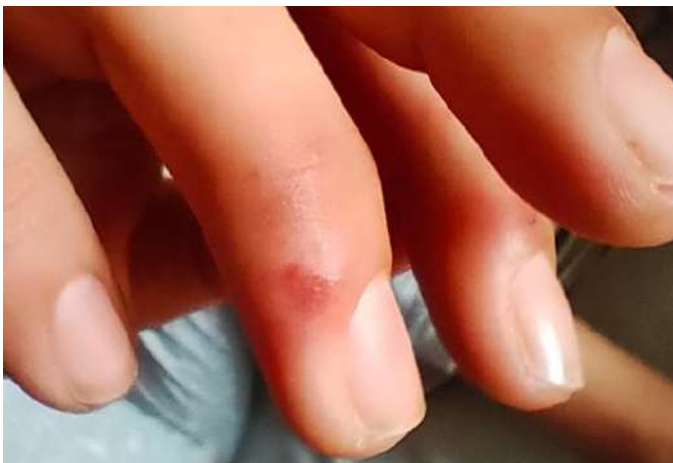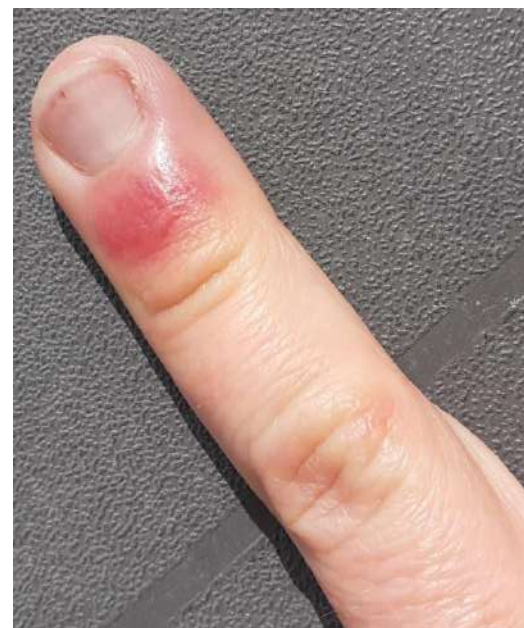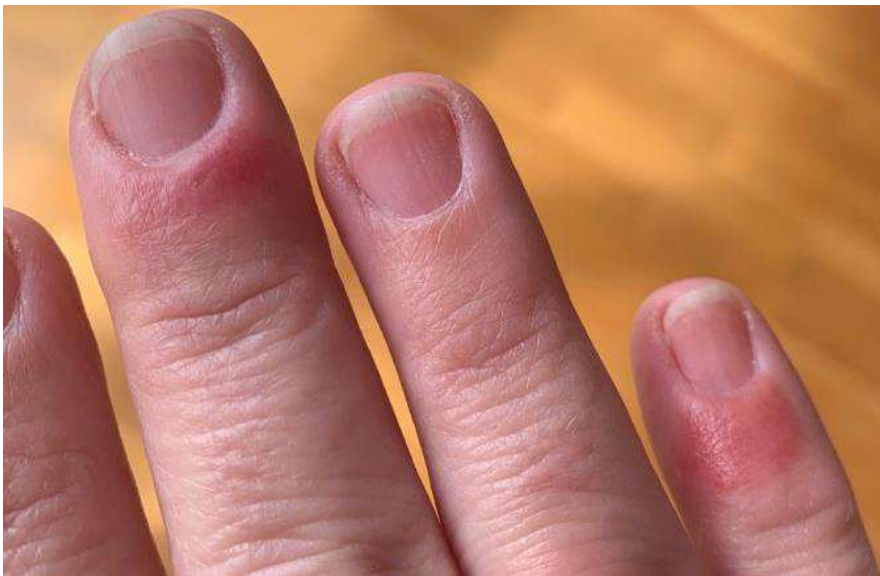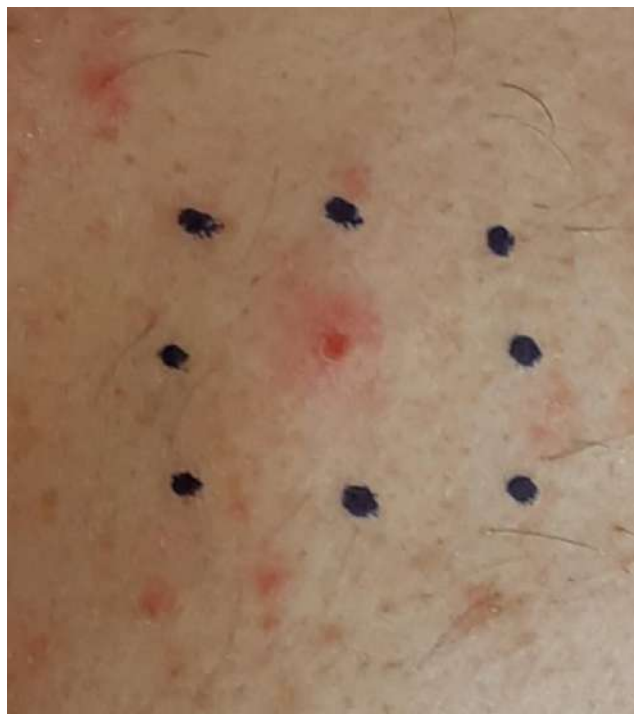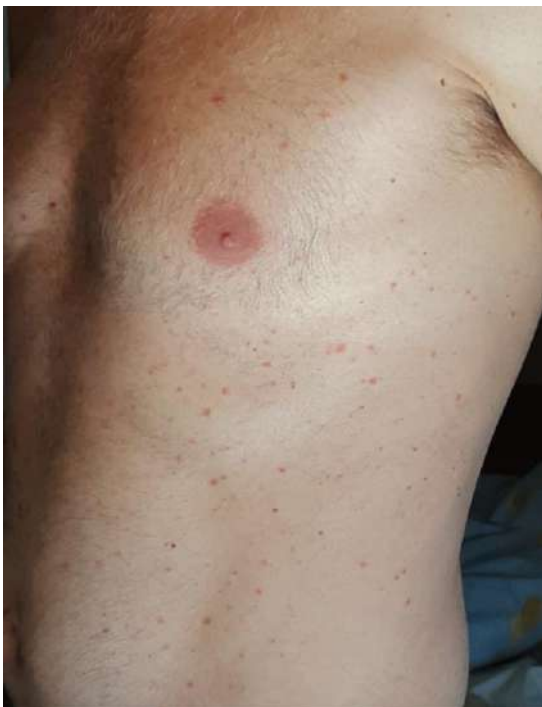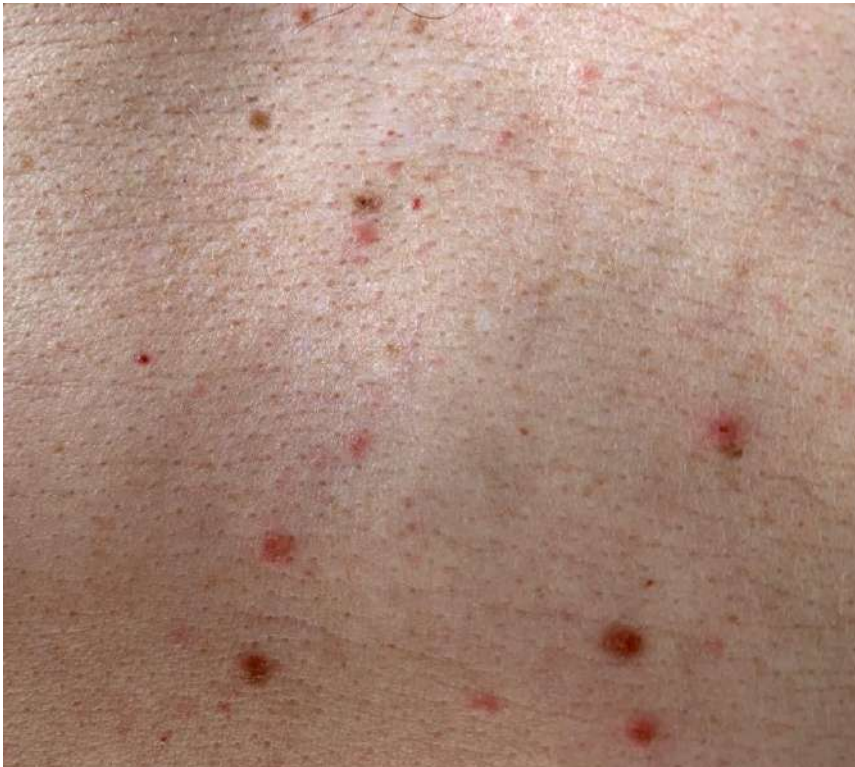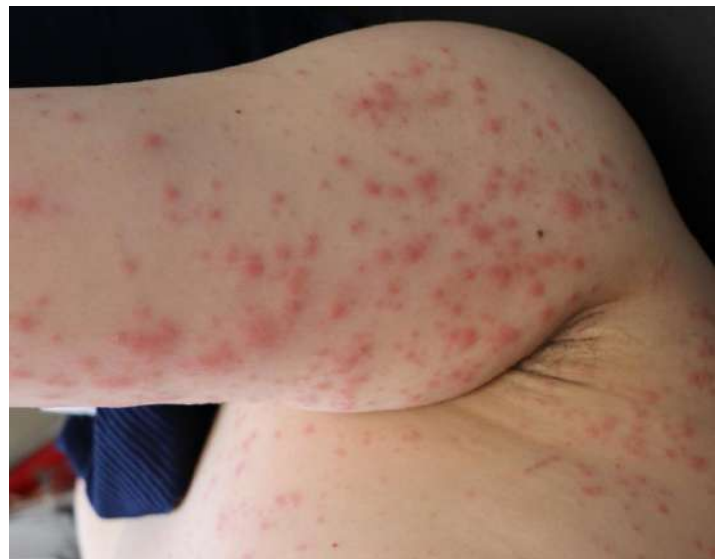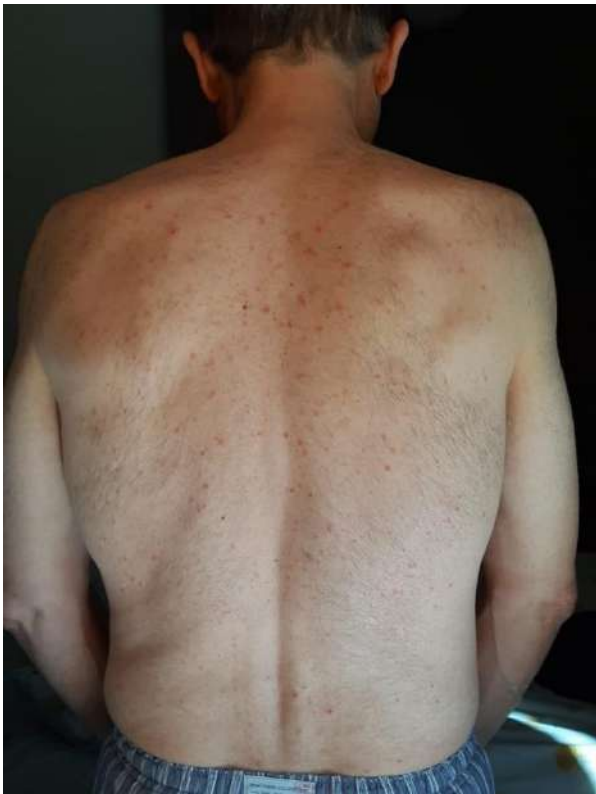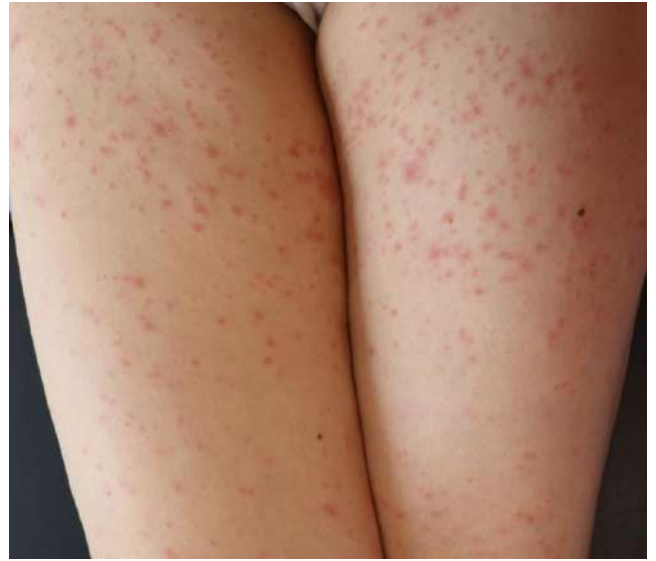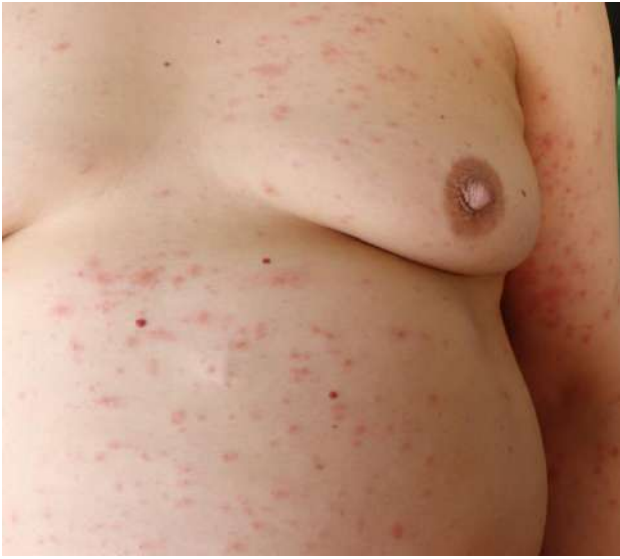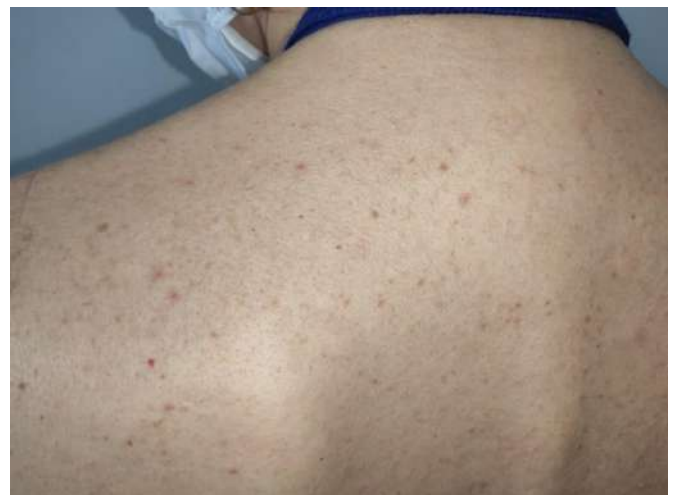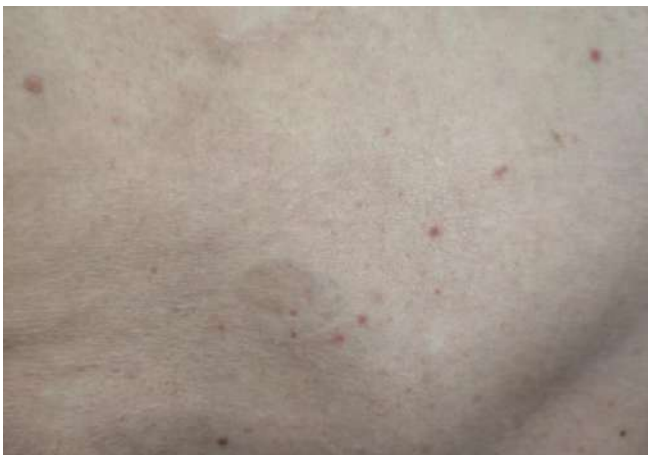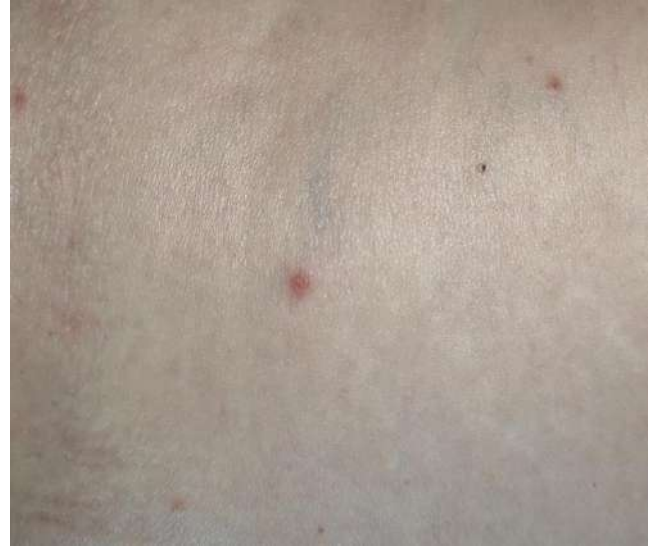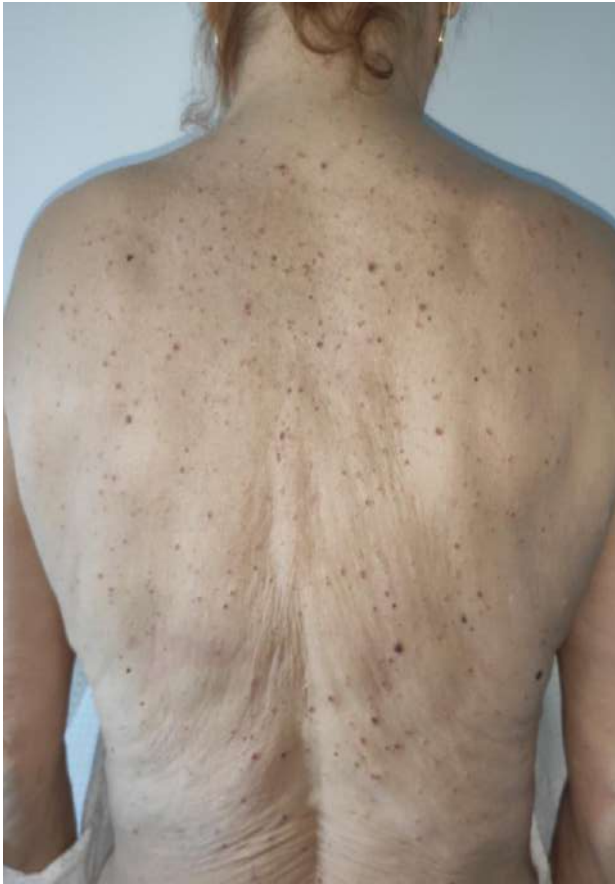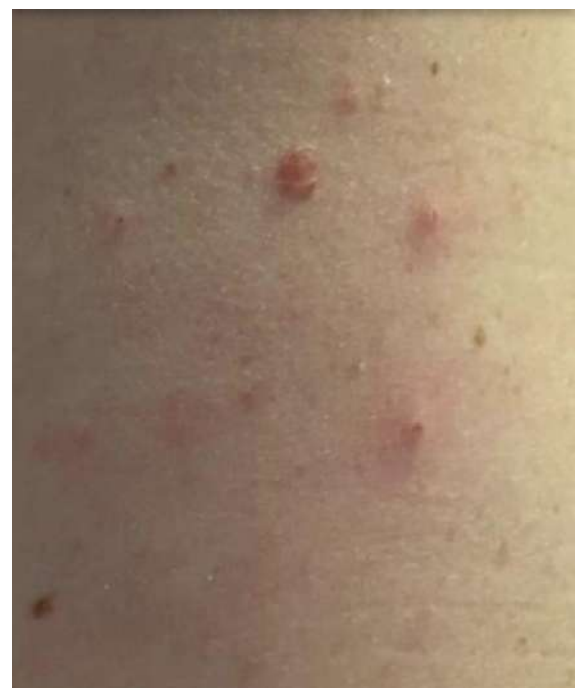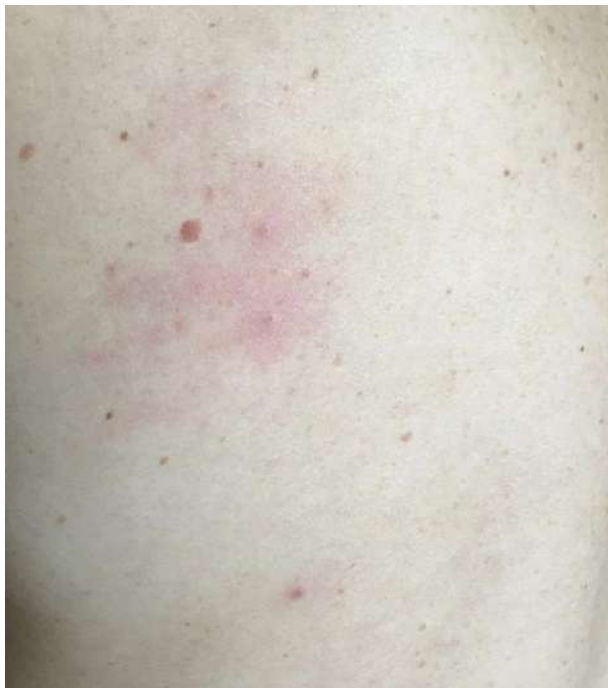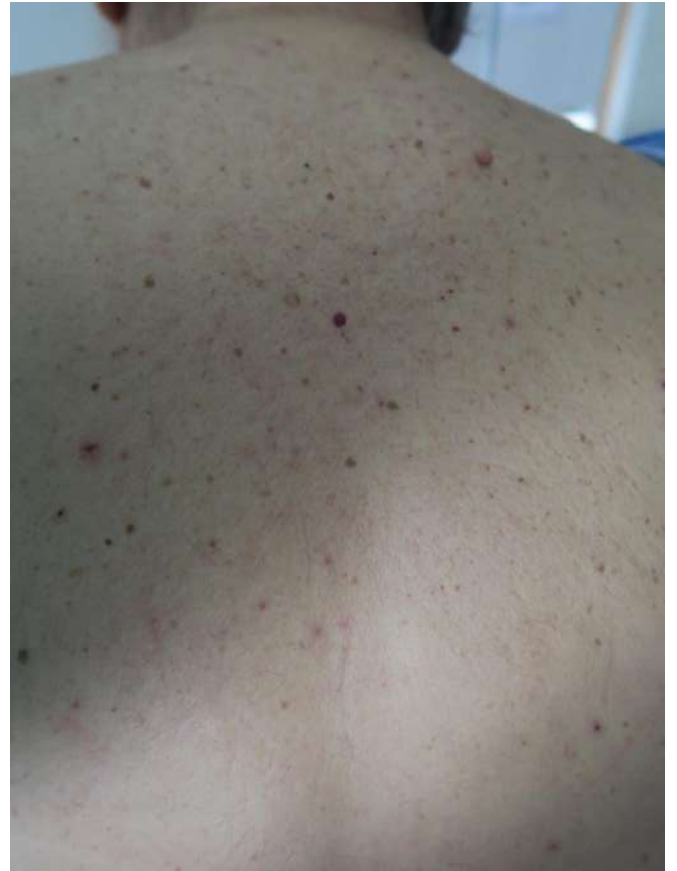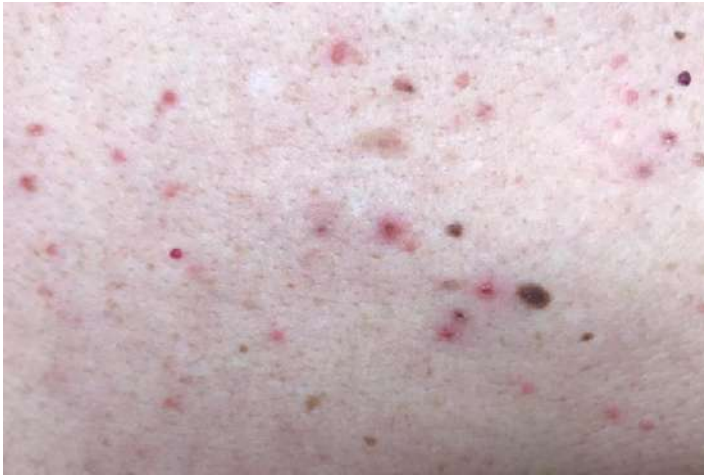## Vesicular Eruption – Confirmed cases

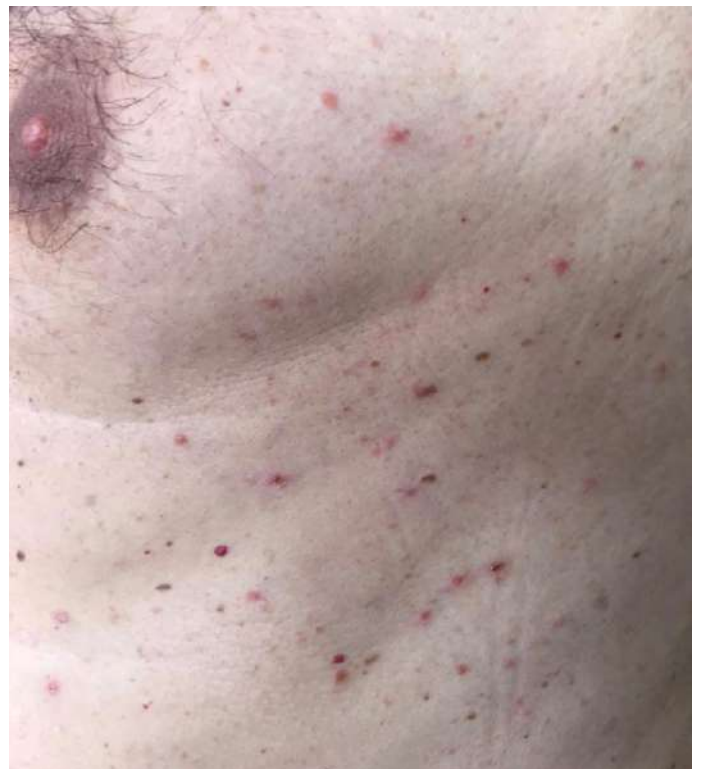
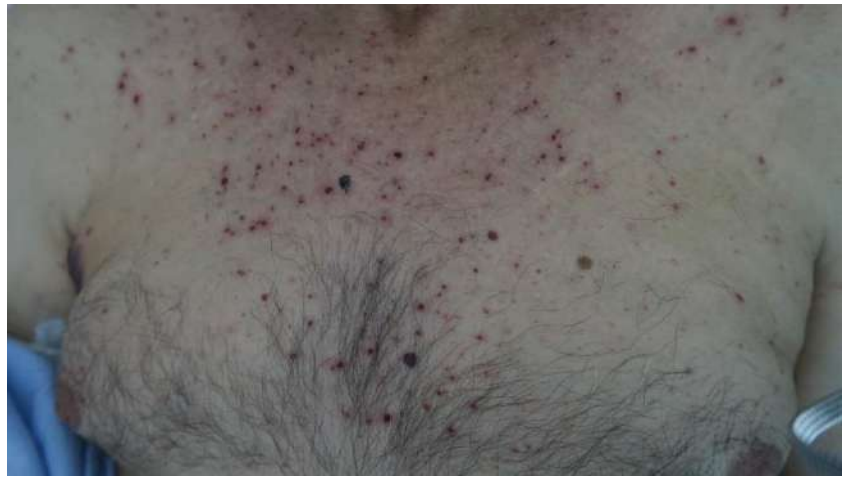
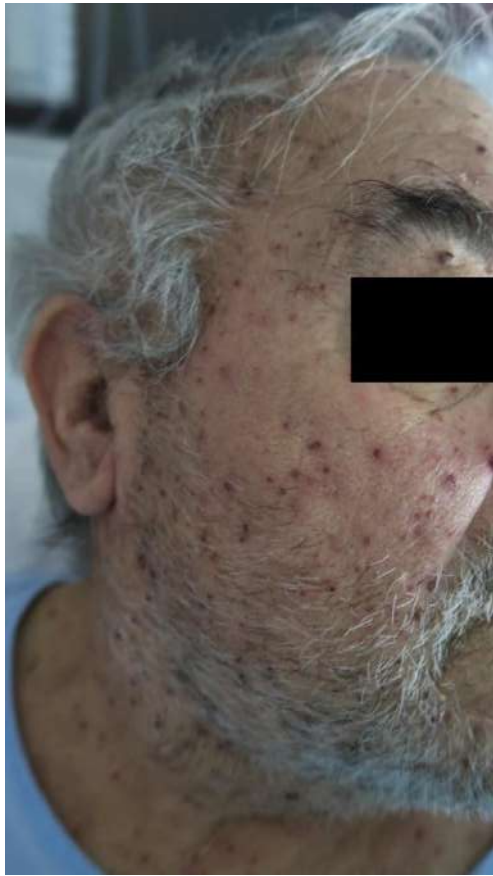


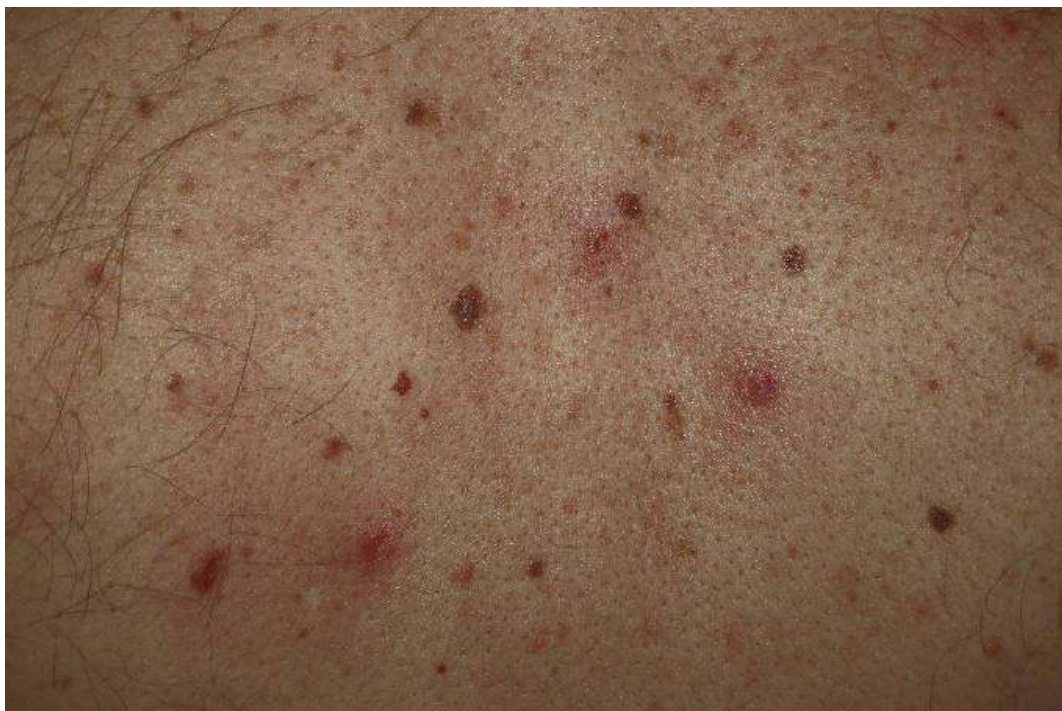
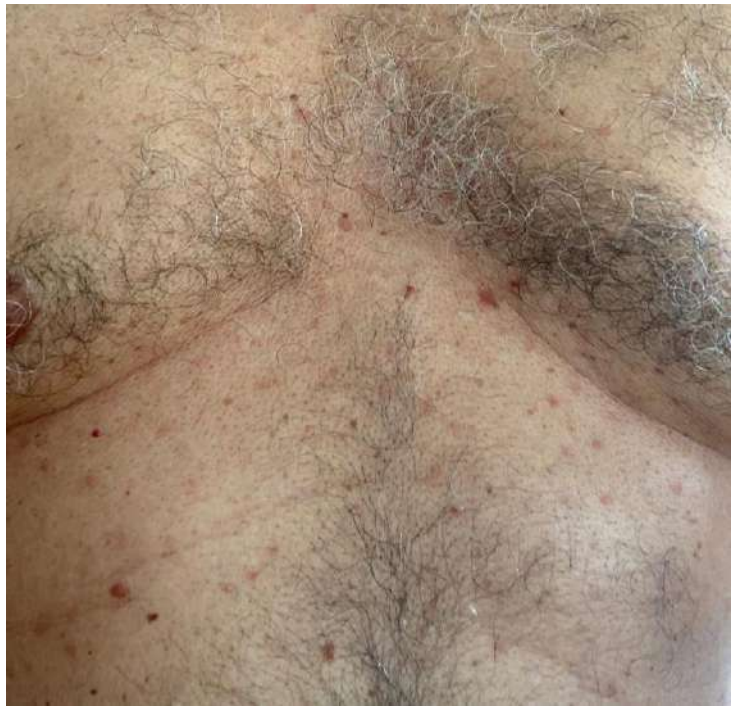
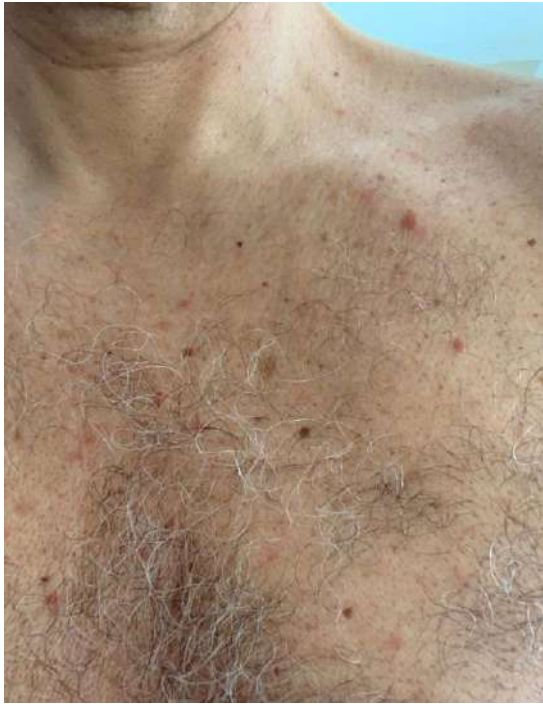




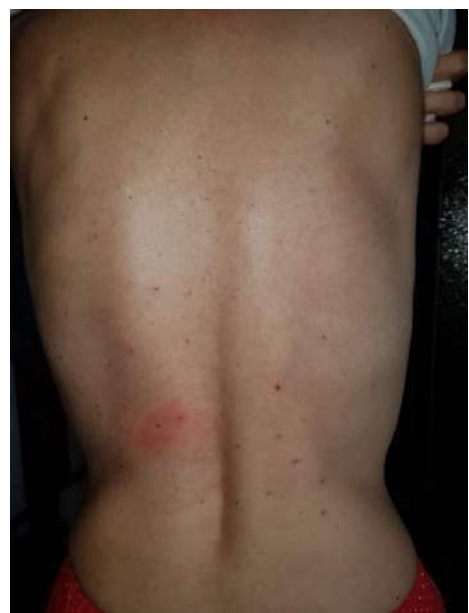
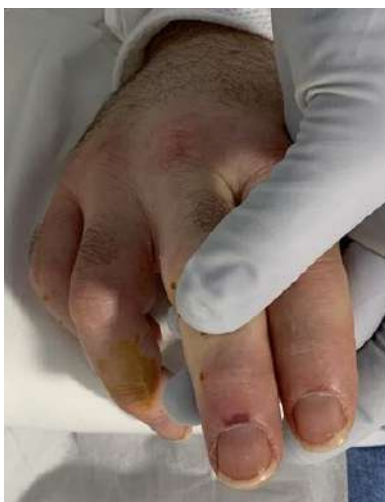
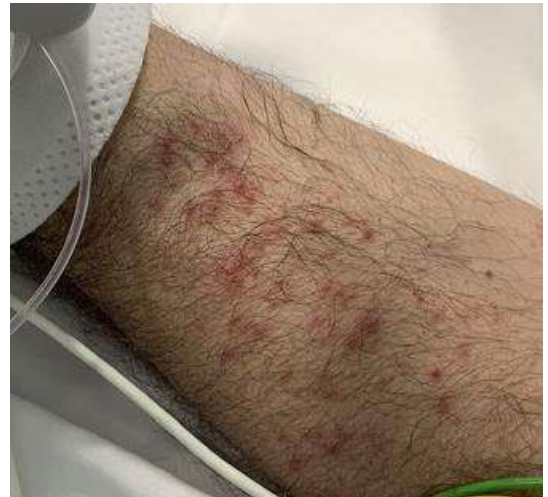
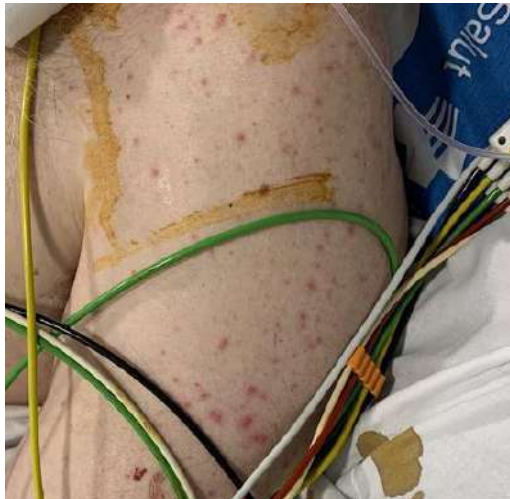
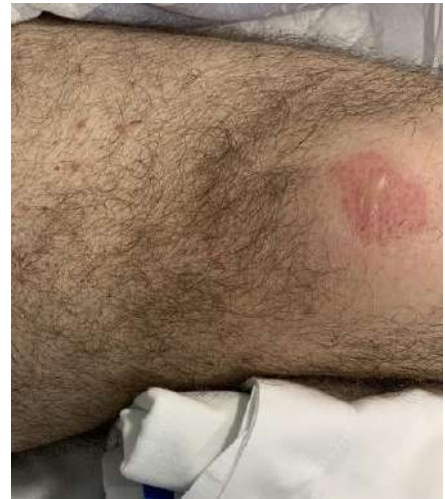
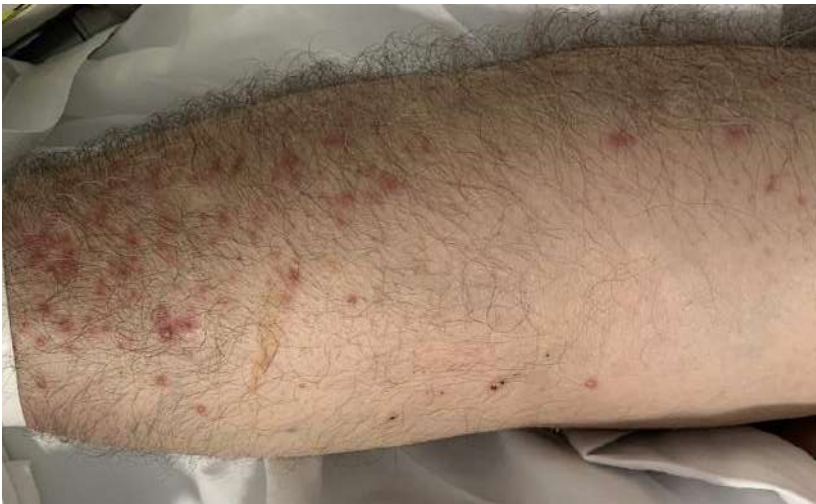


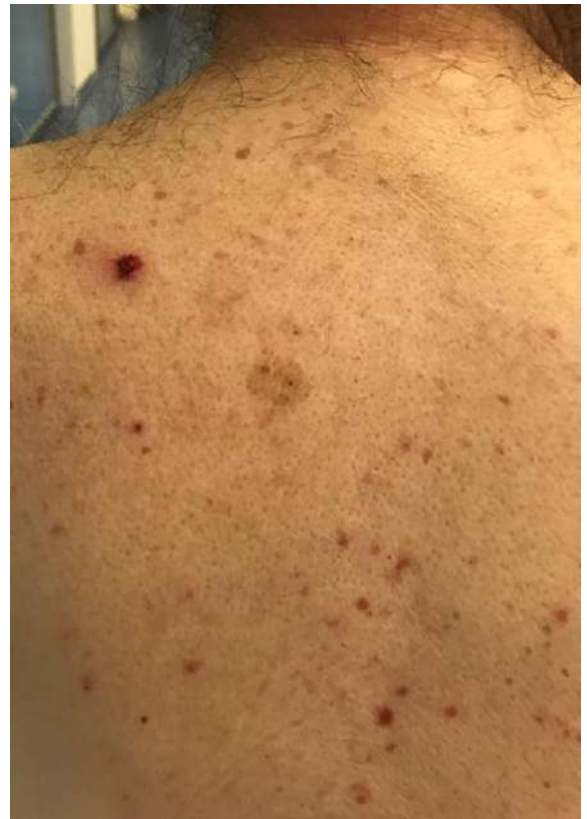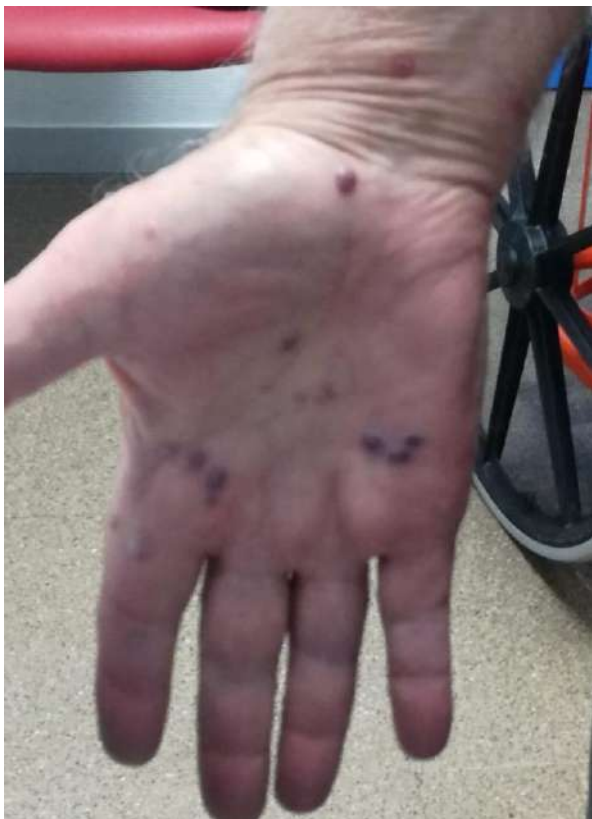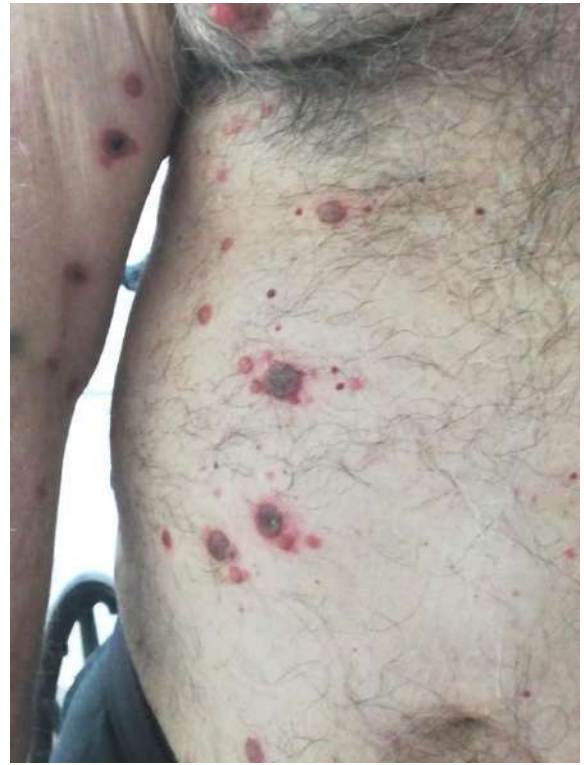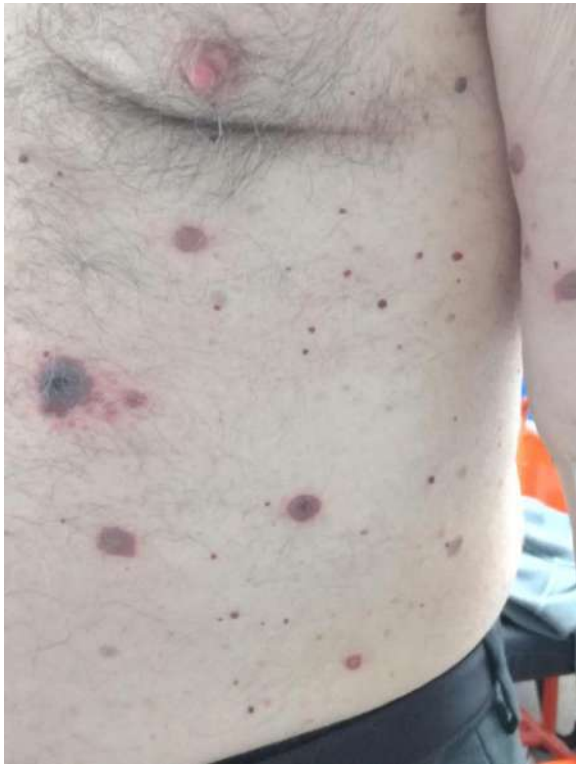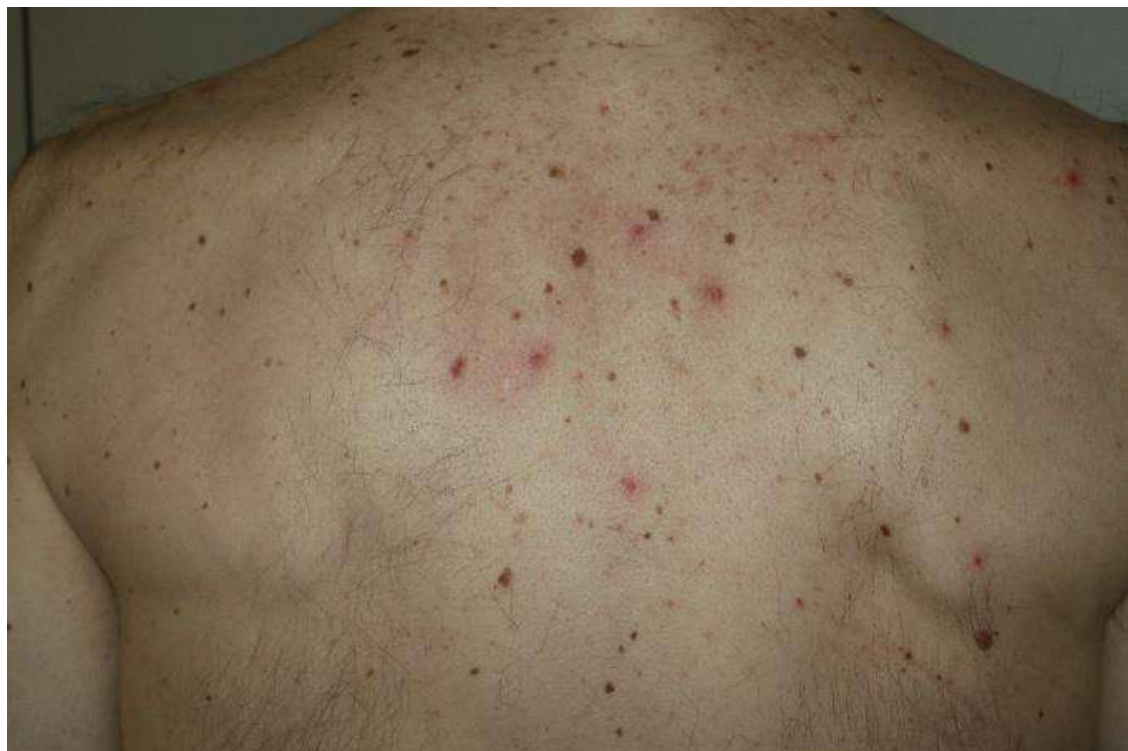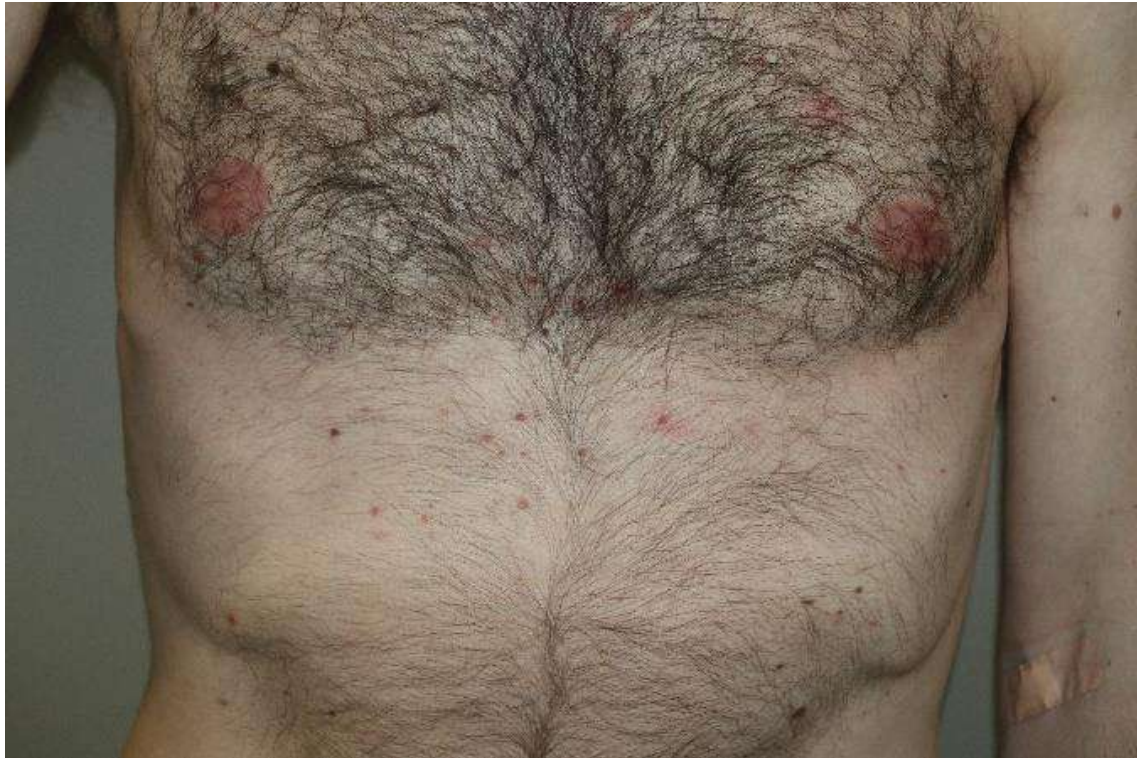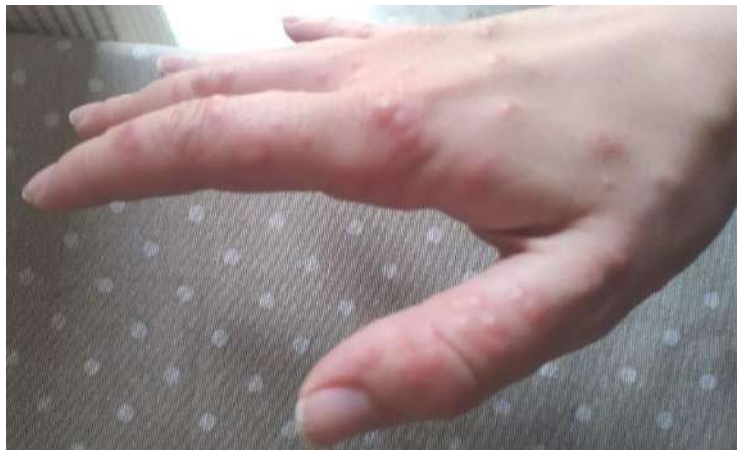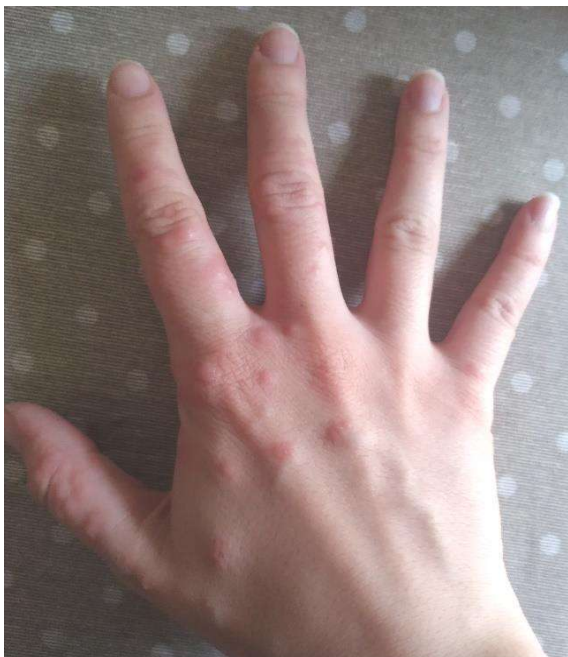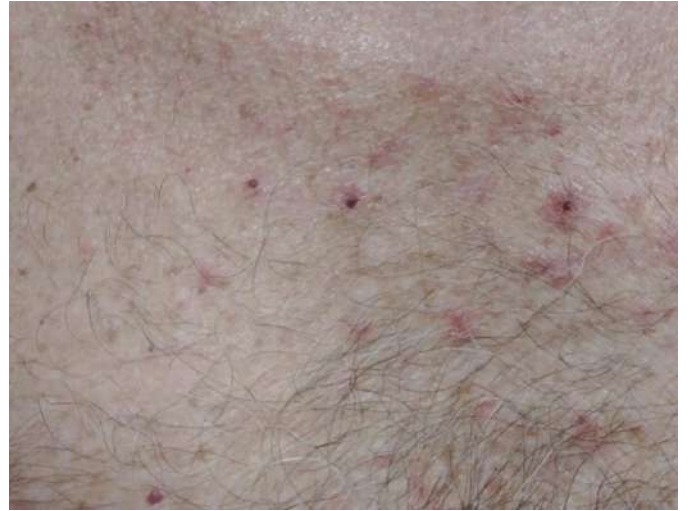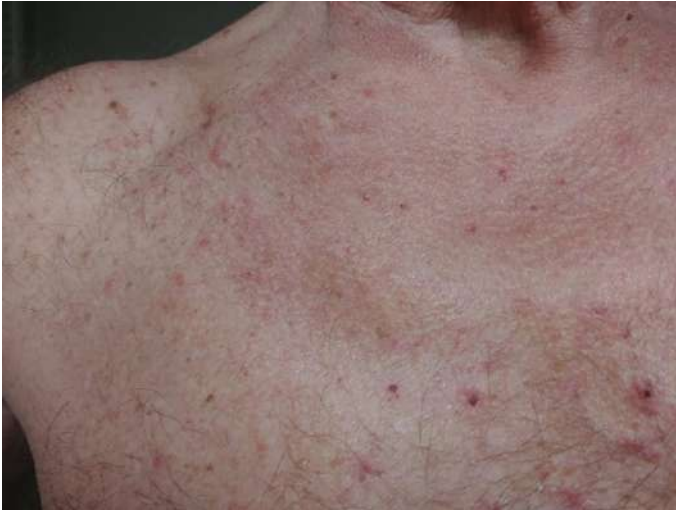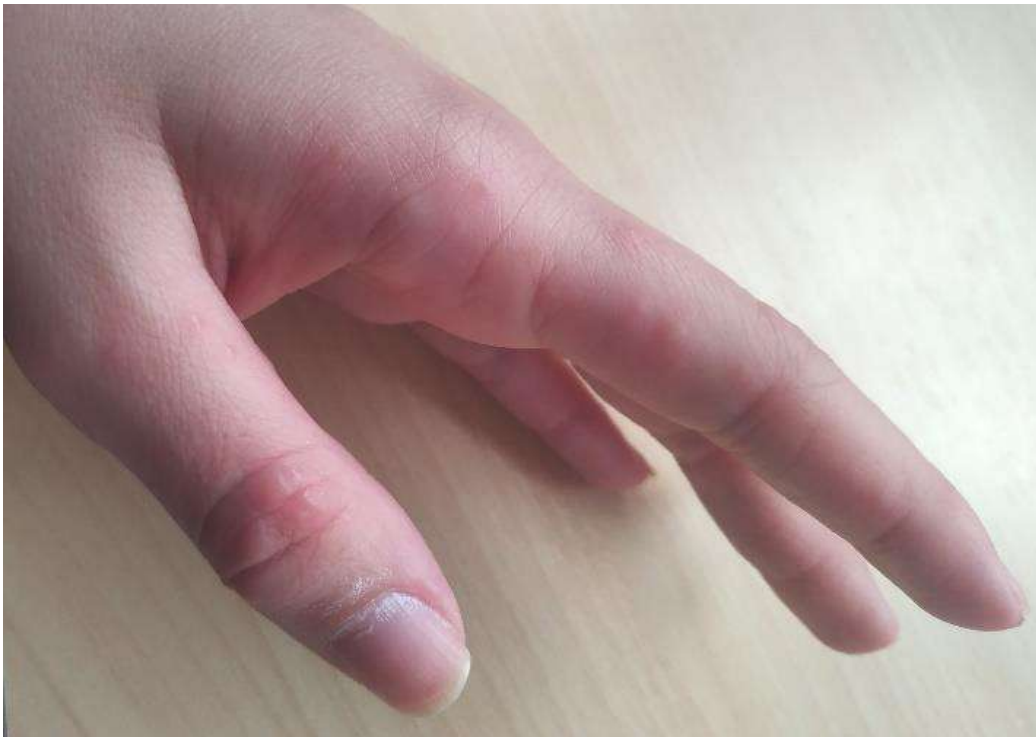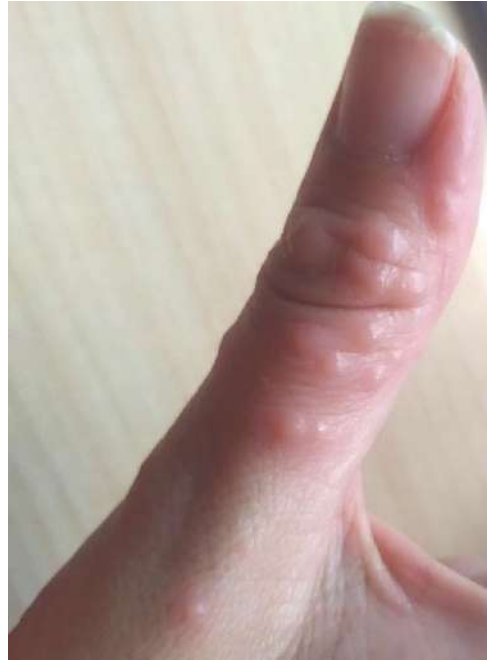






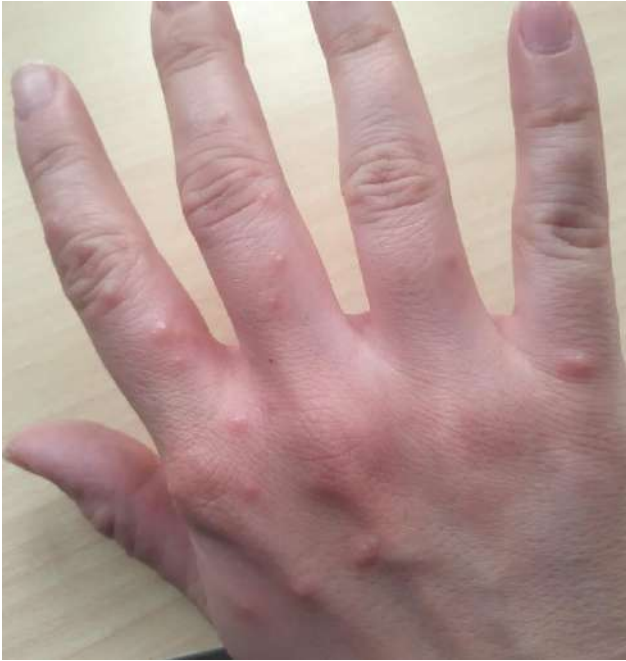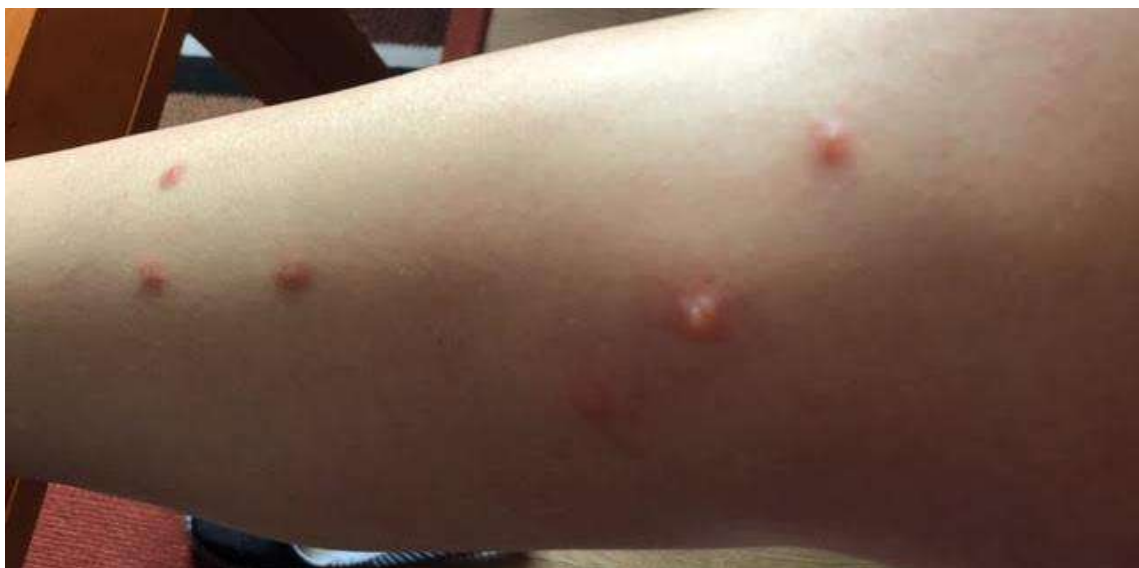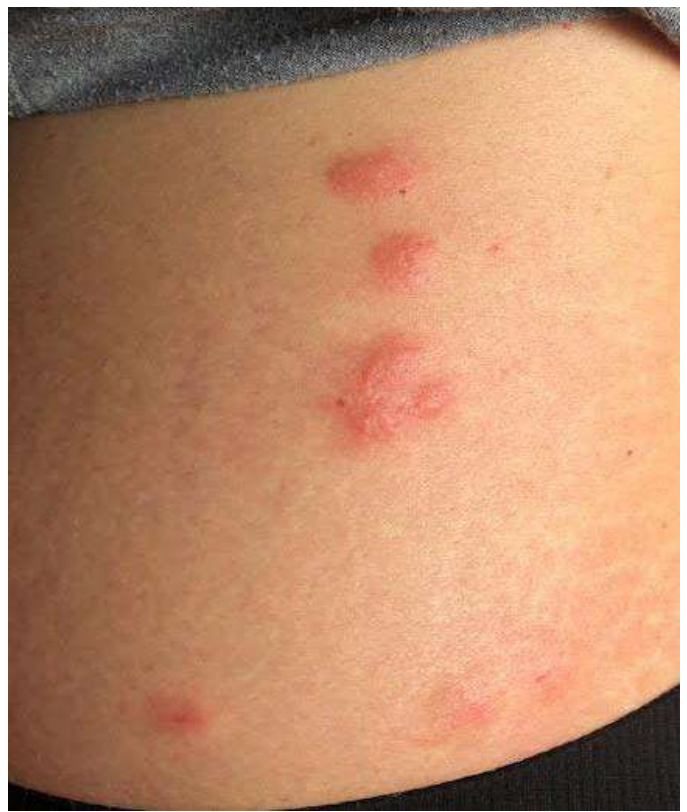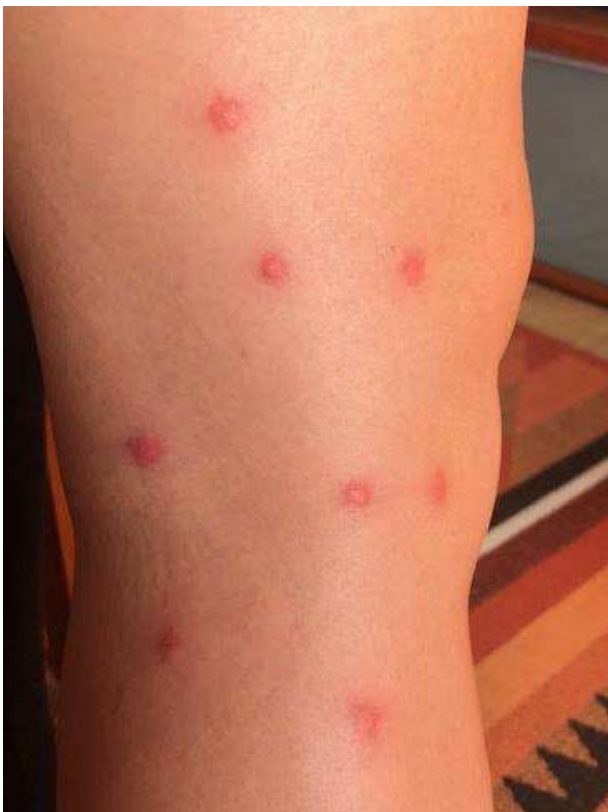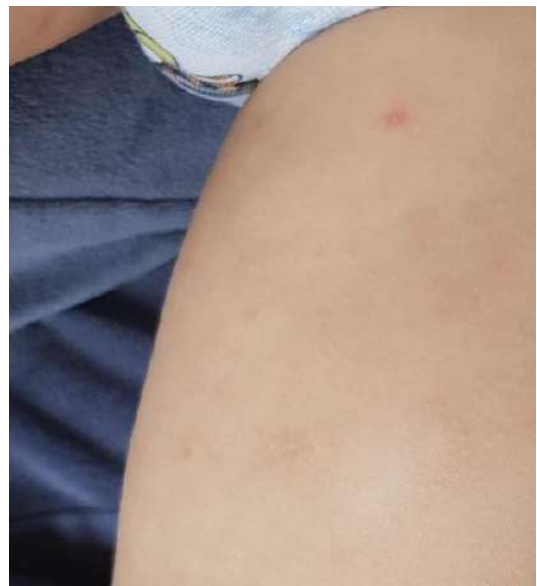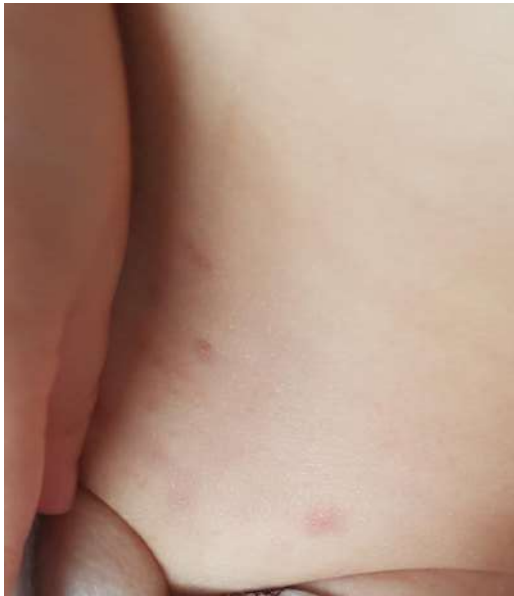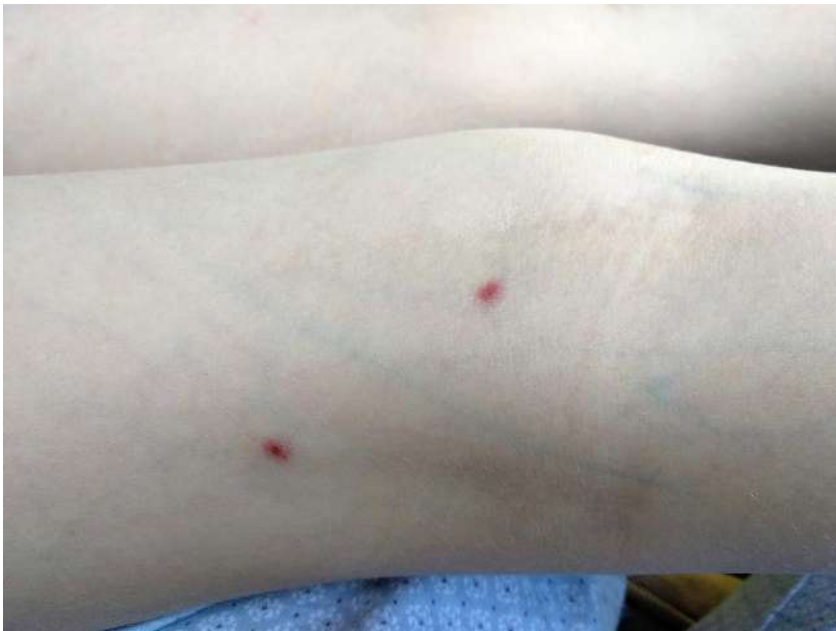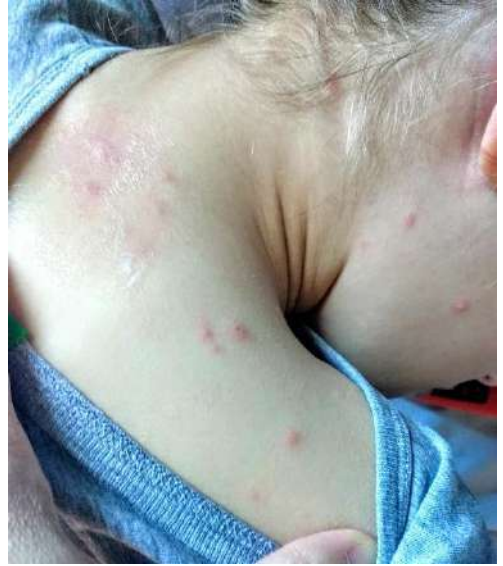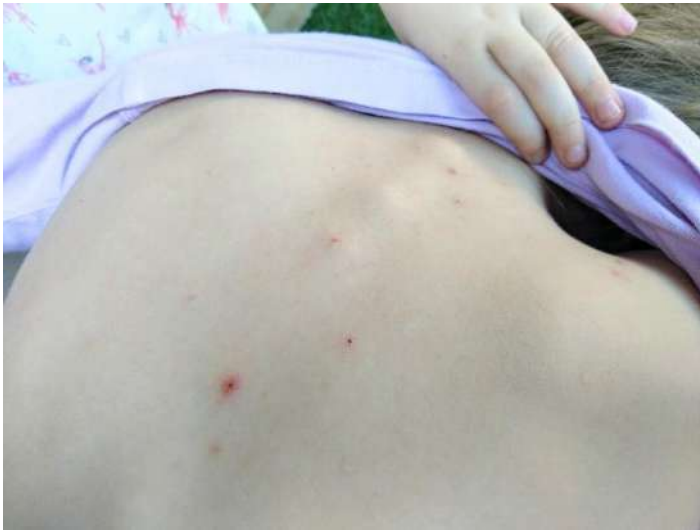## Vesicular Eruption – Suspected cases

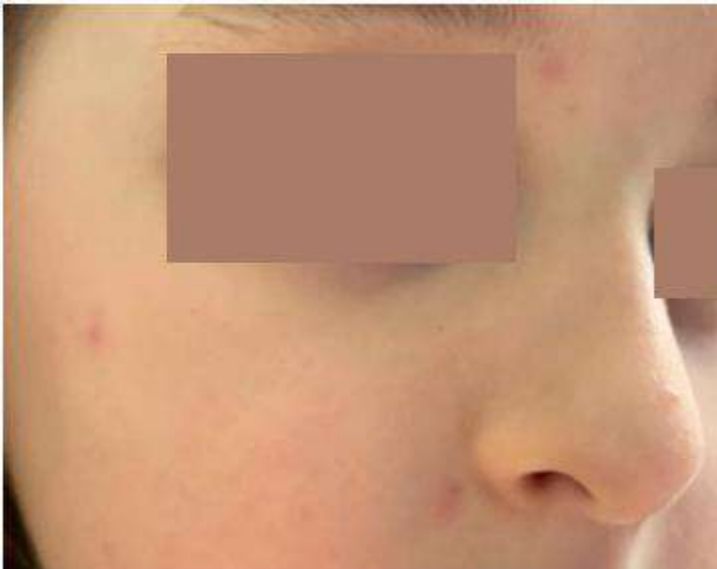
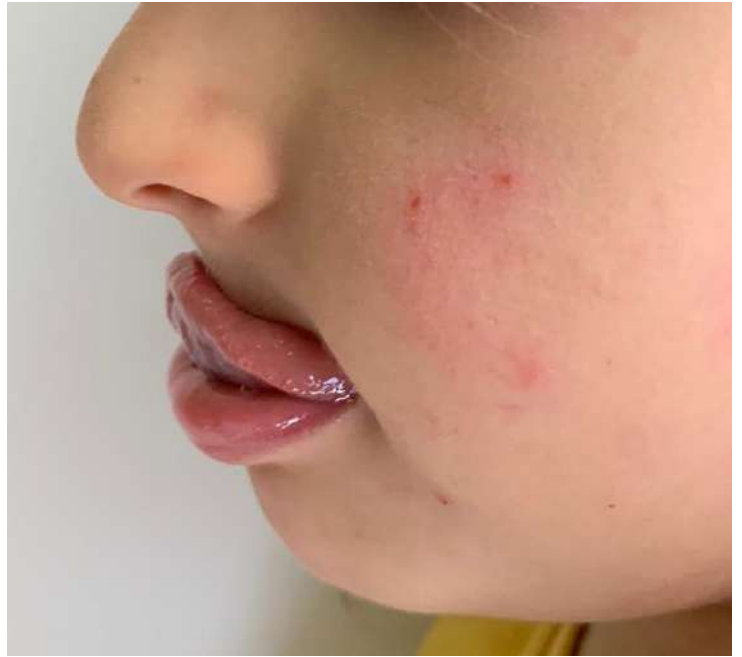
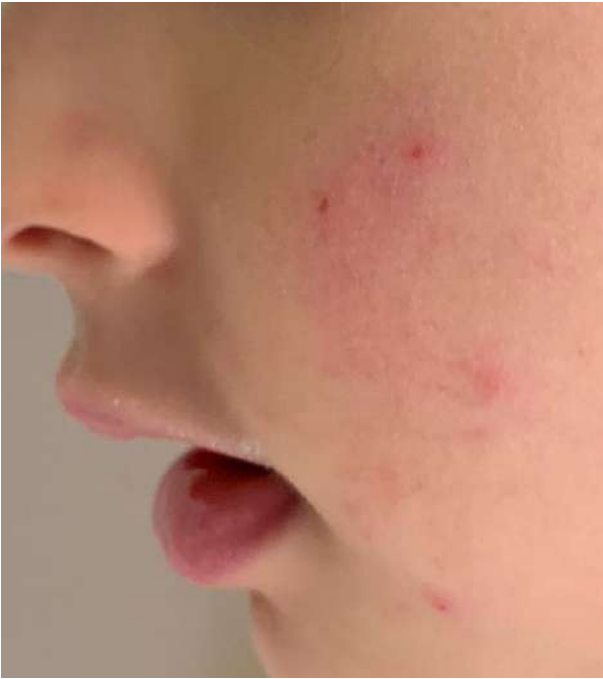


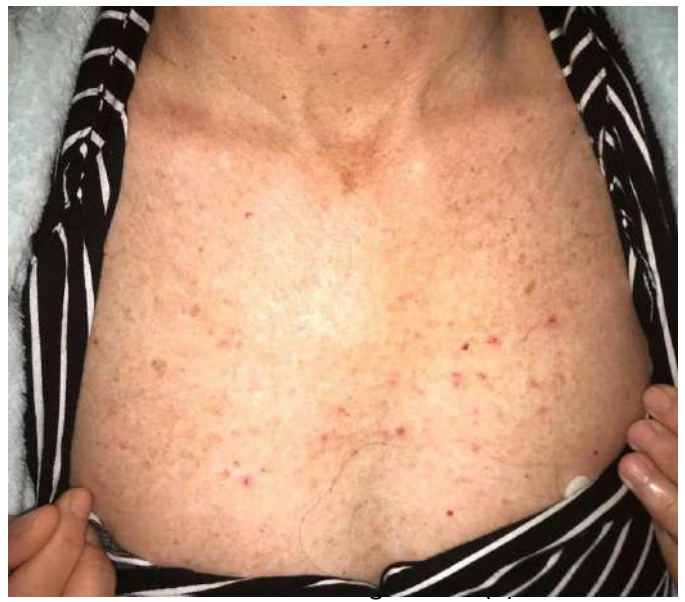
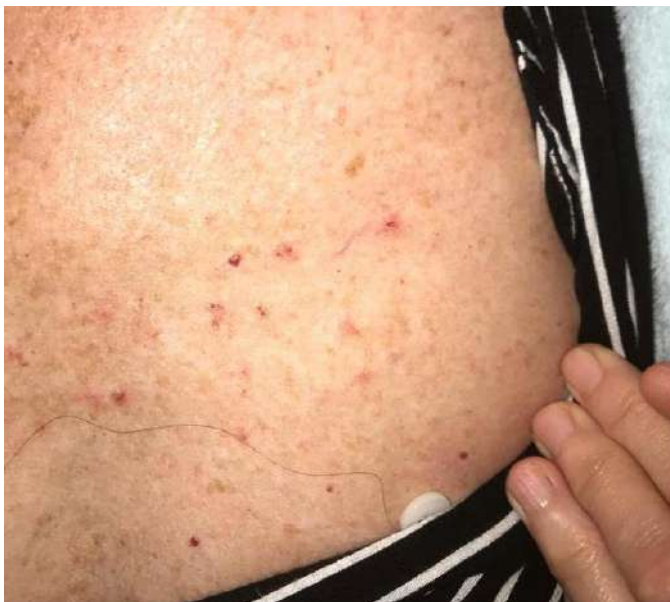
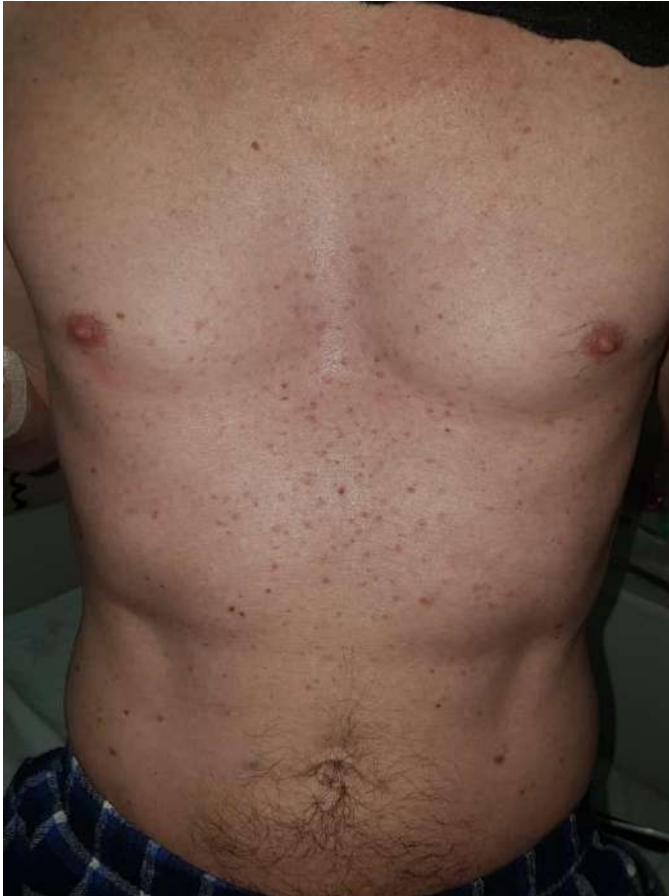




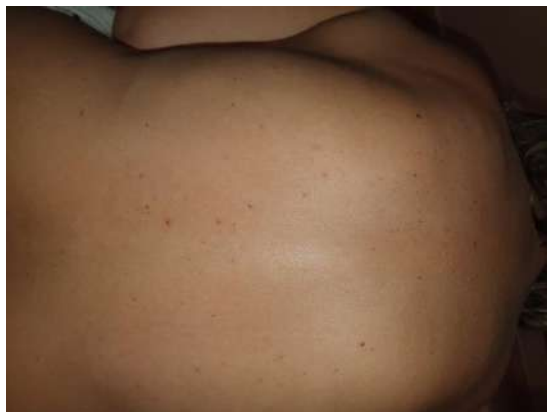
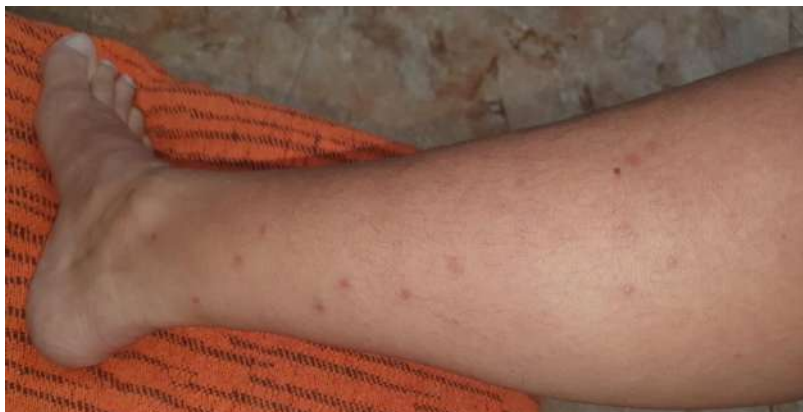
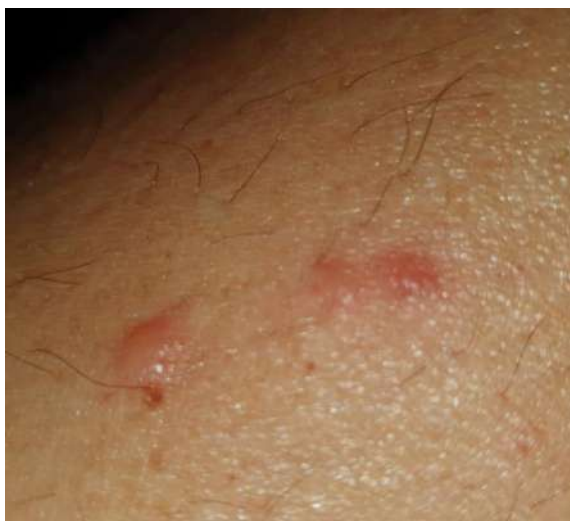
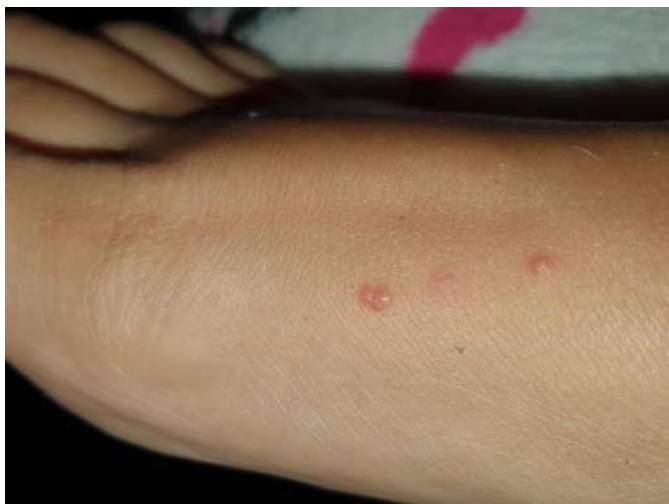
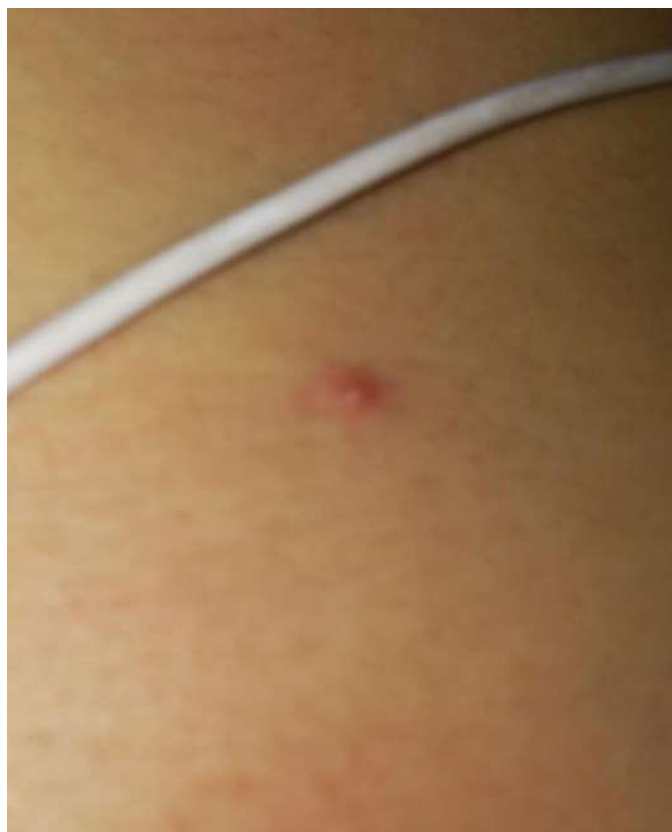
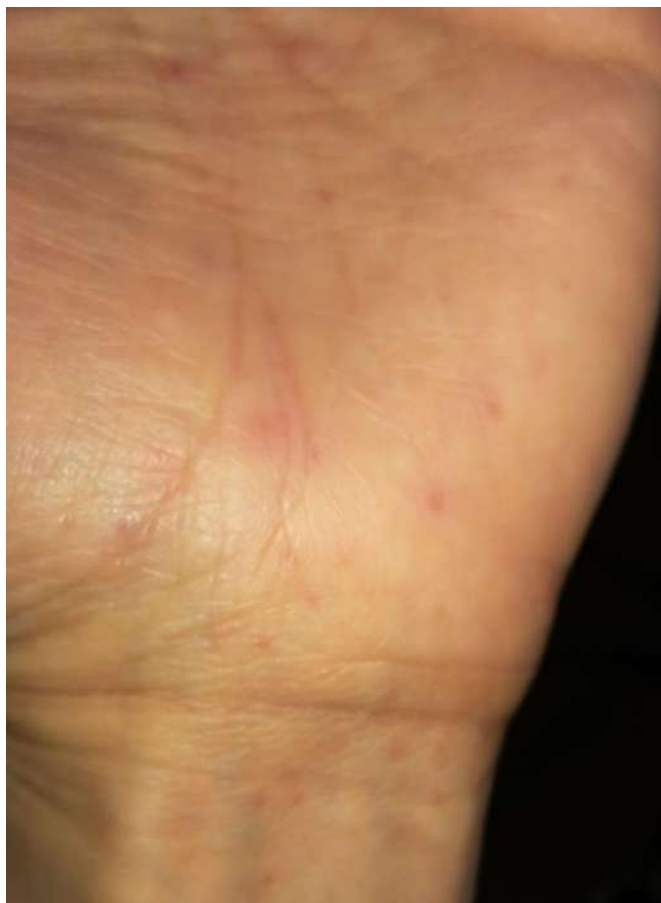


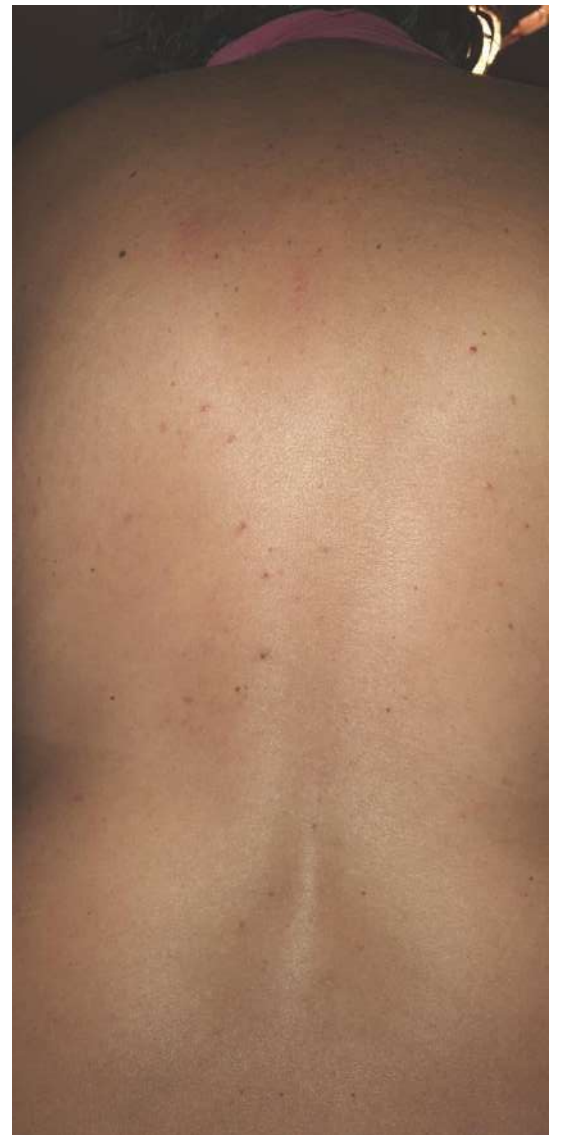
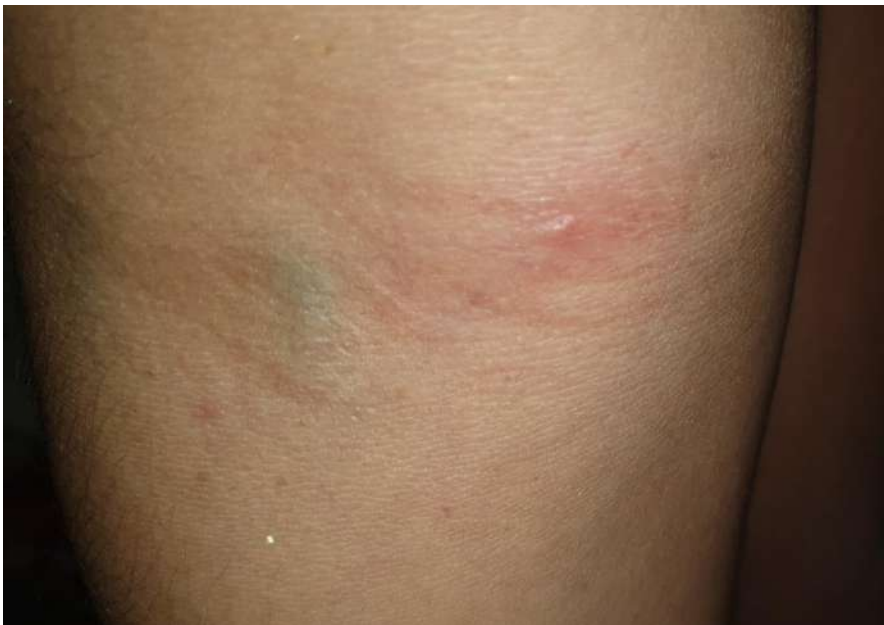
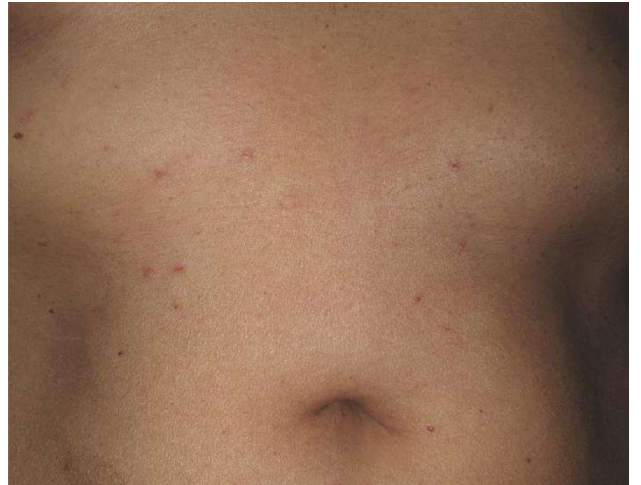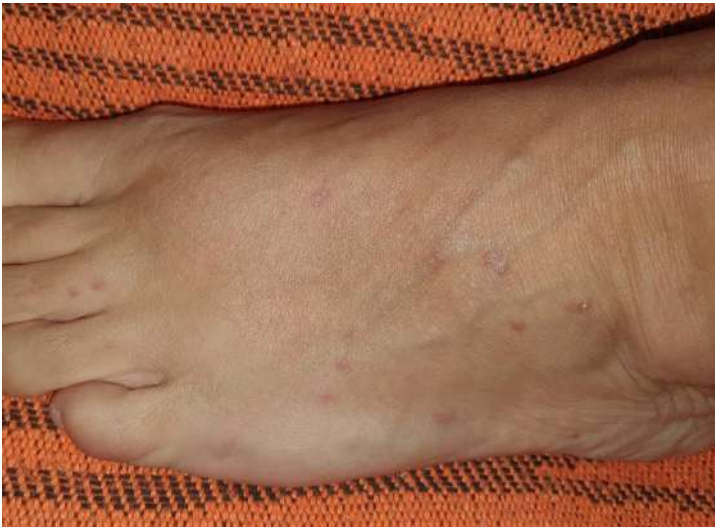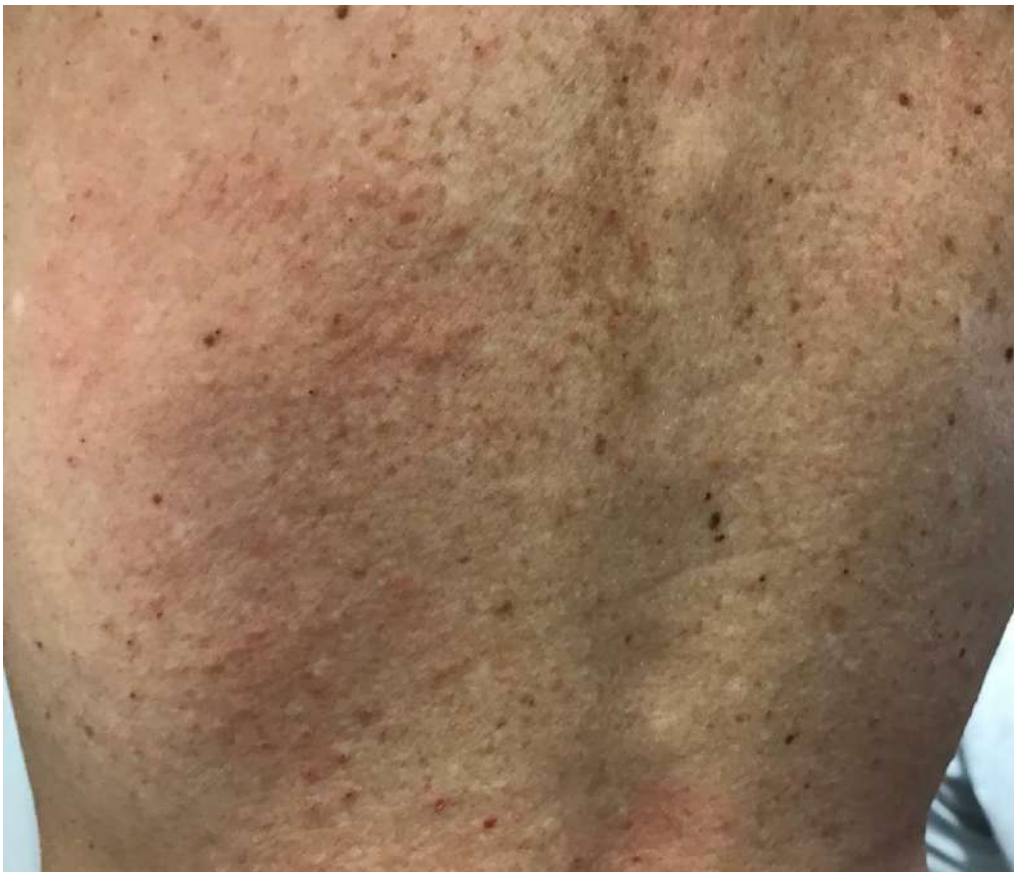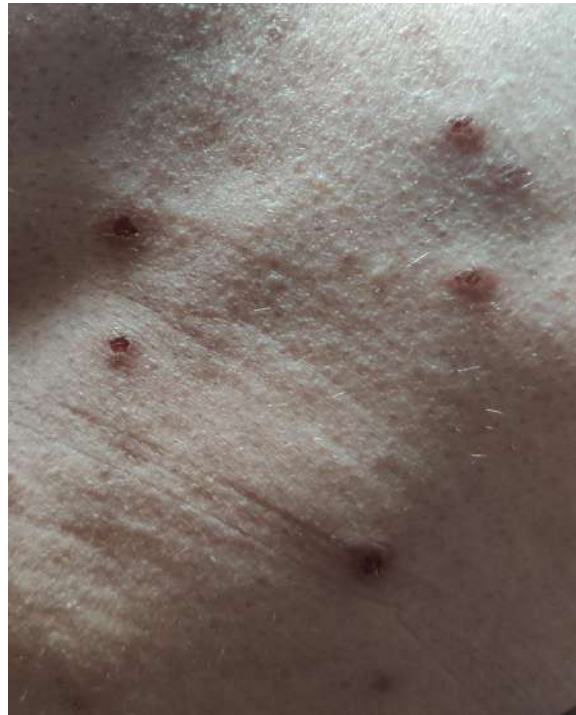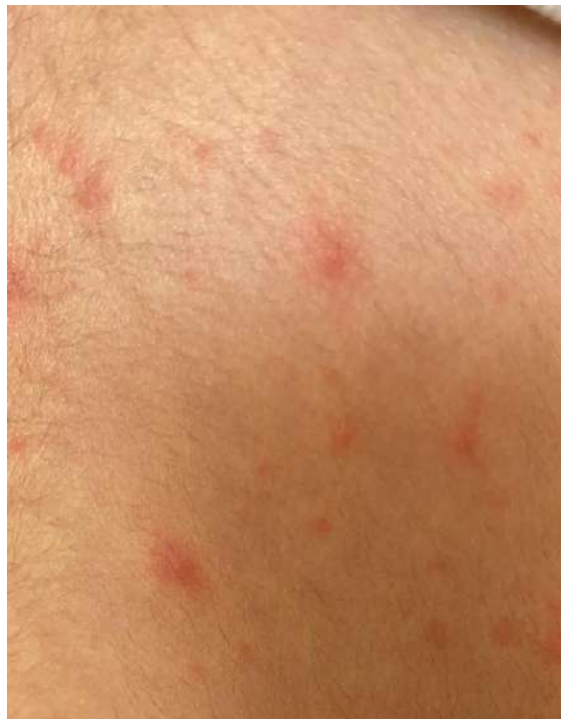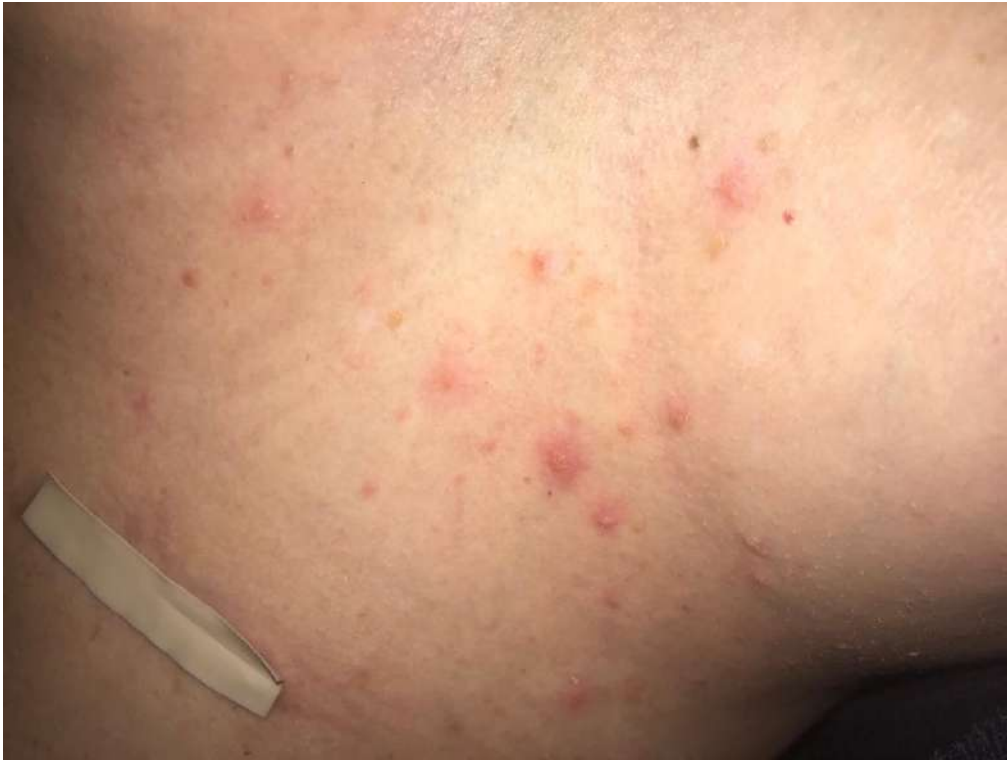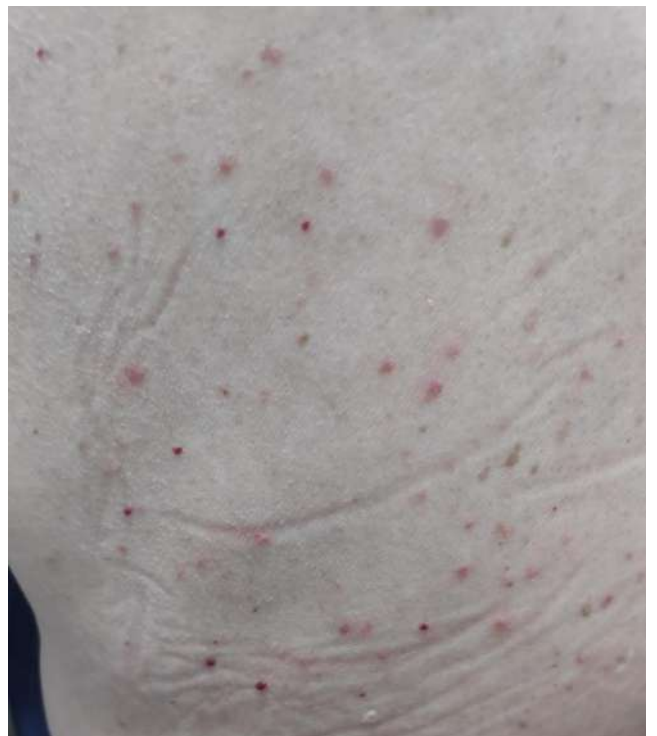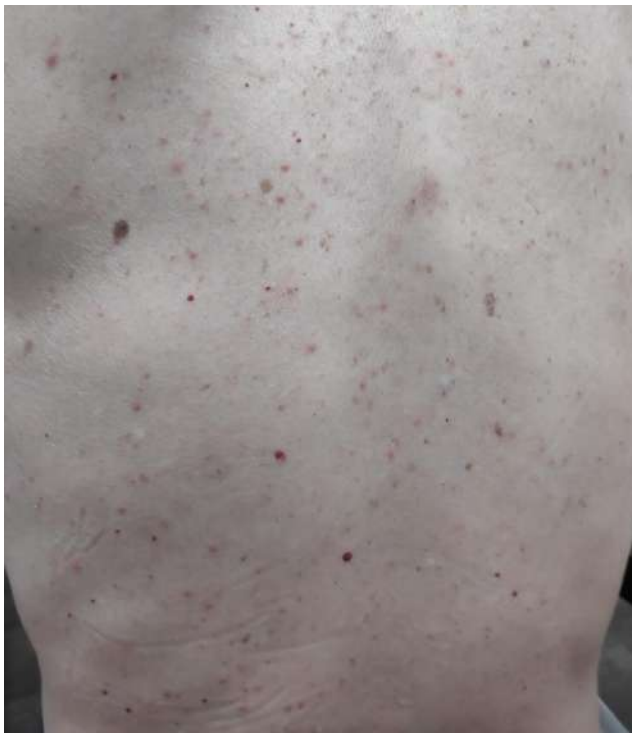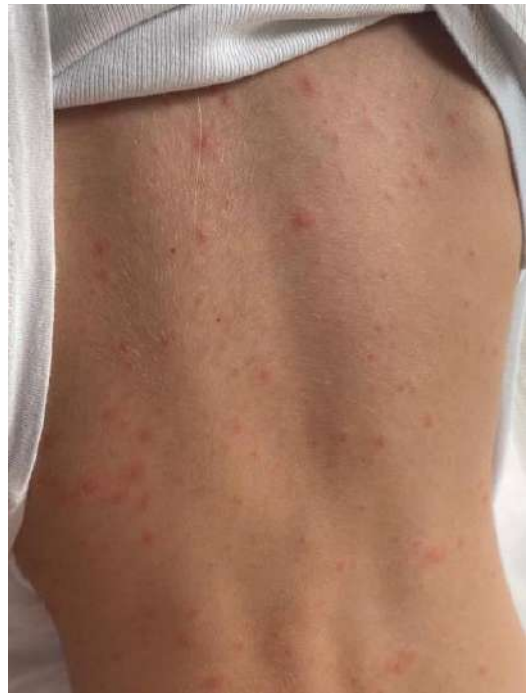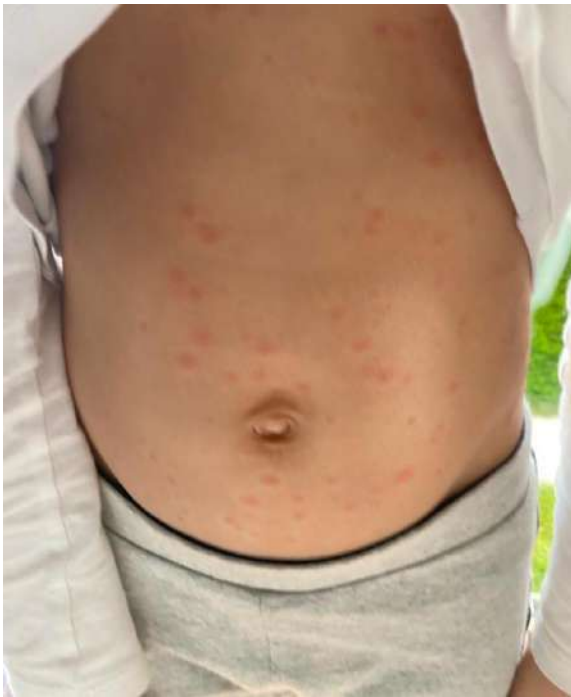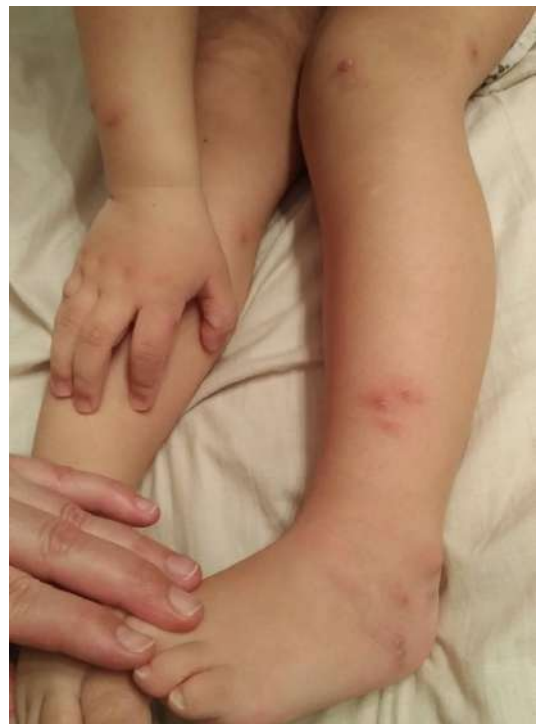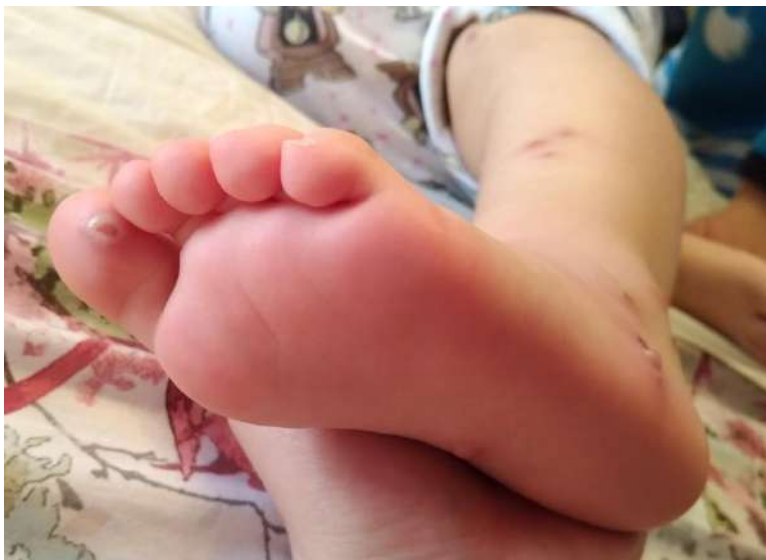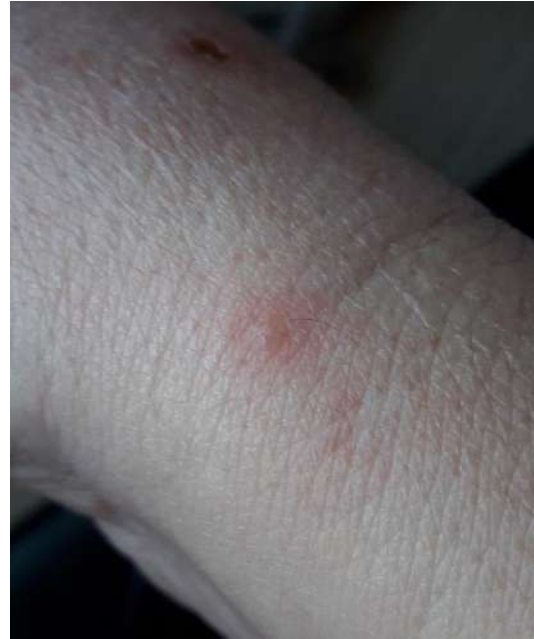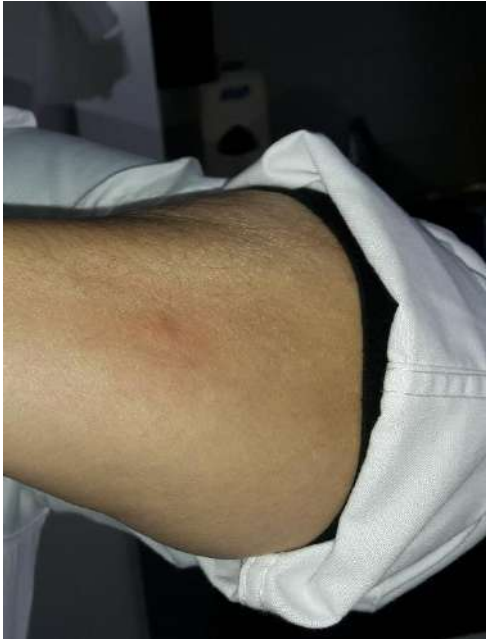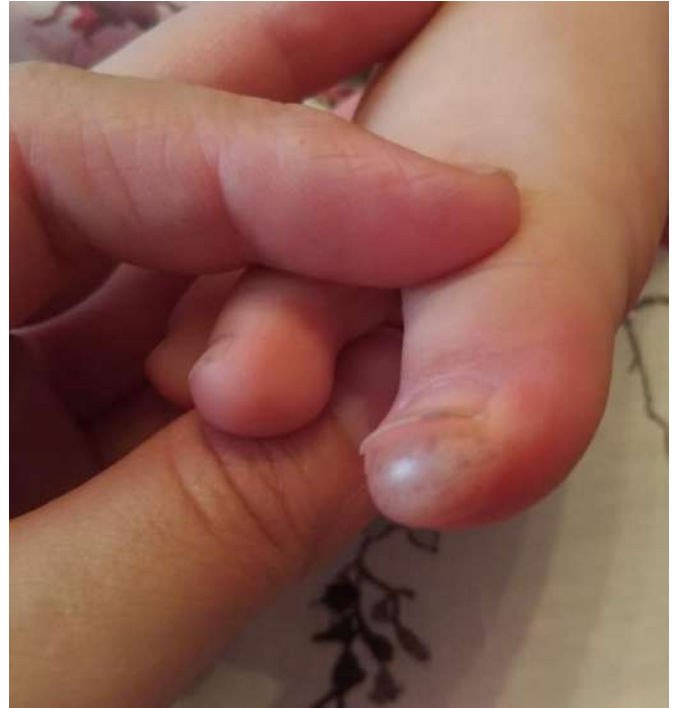












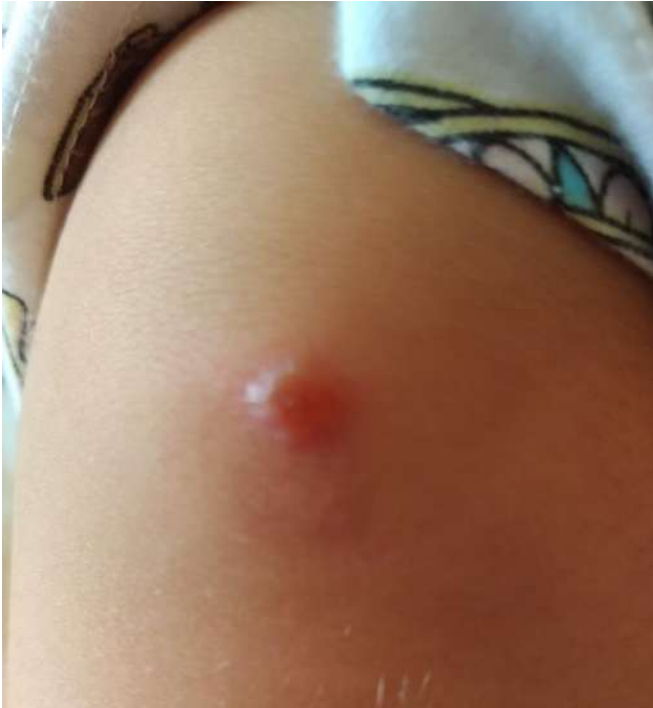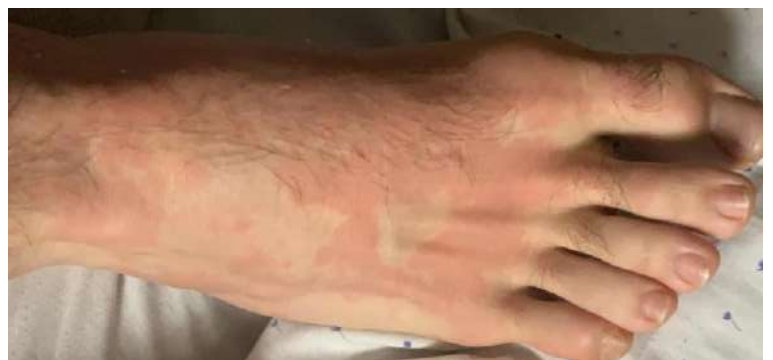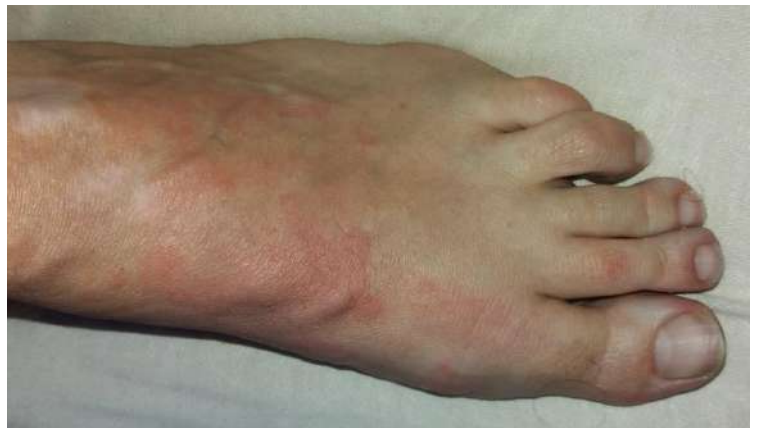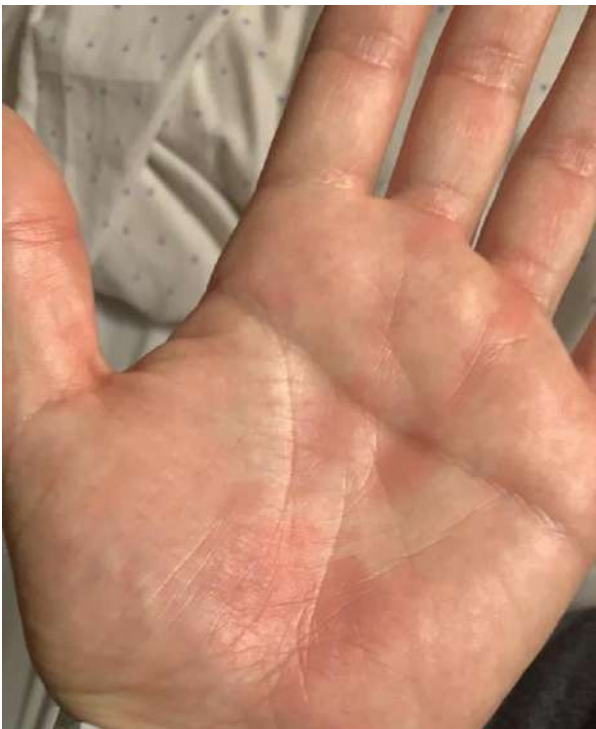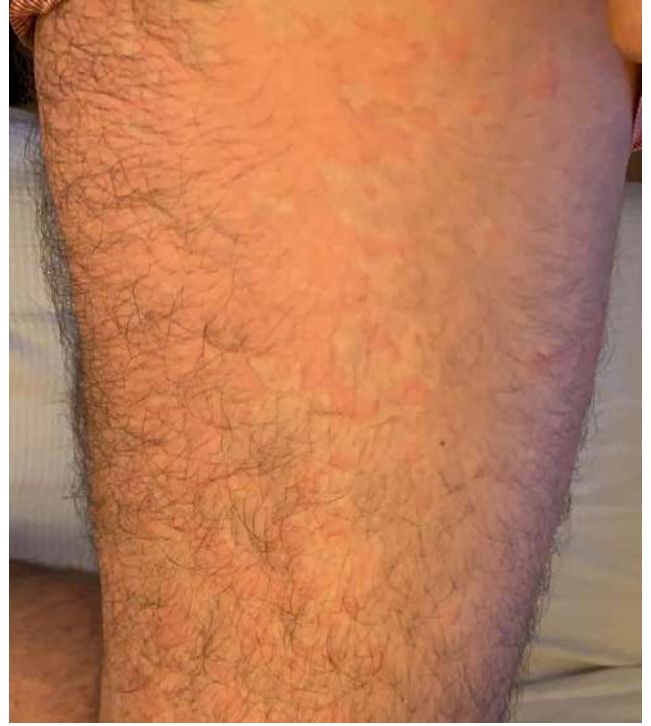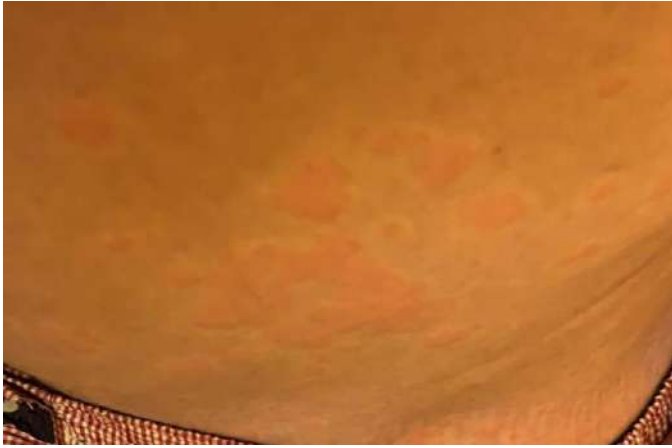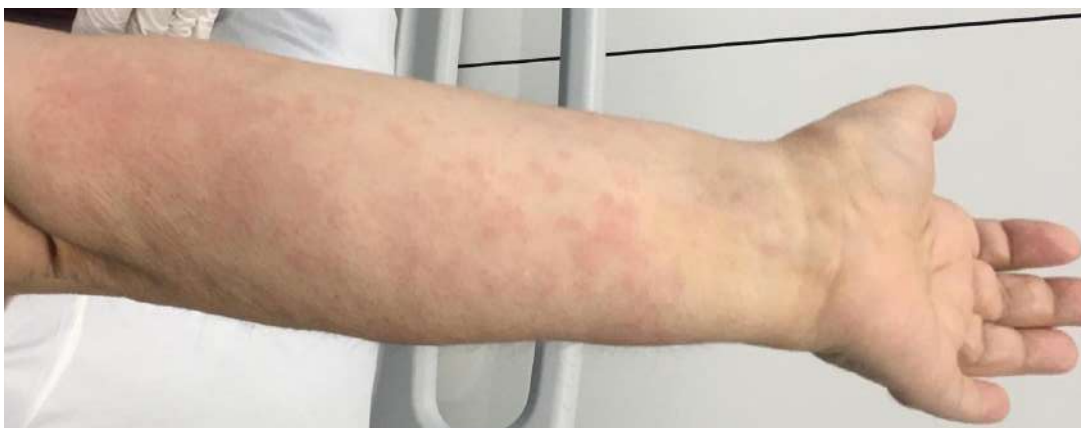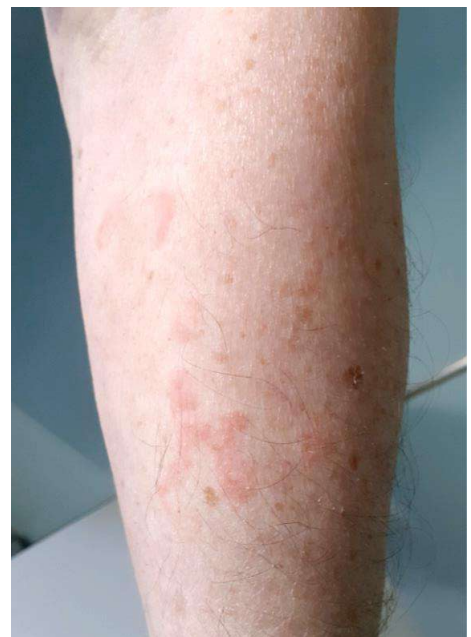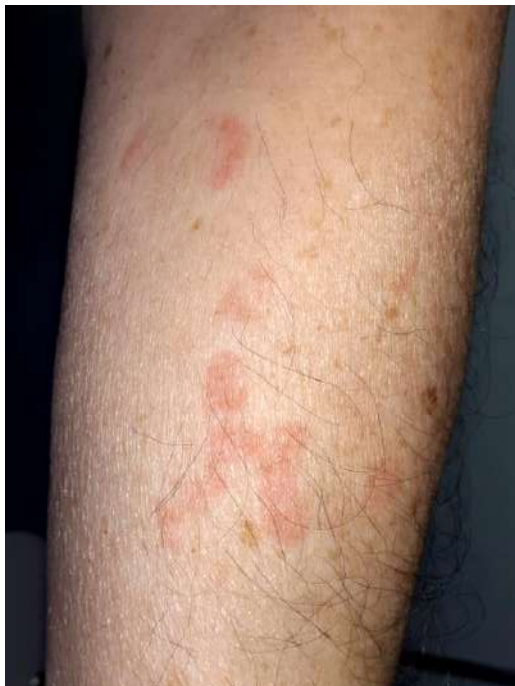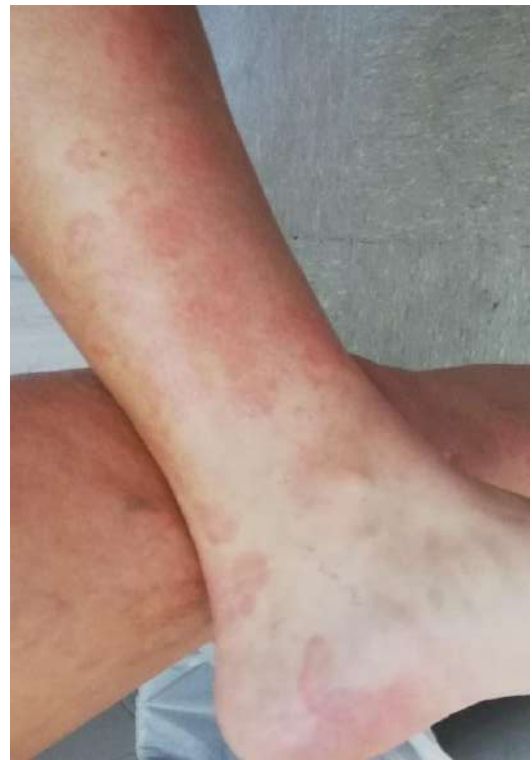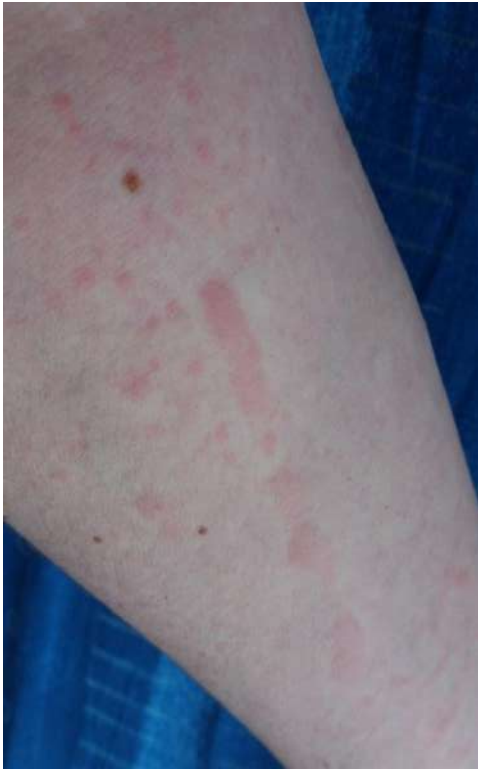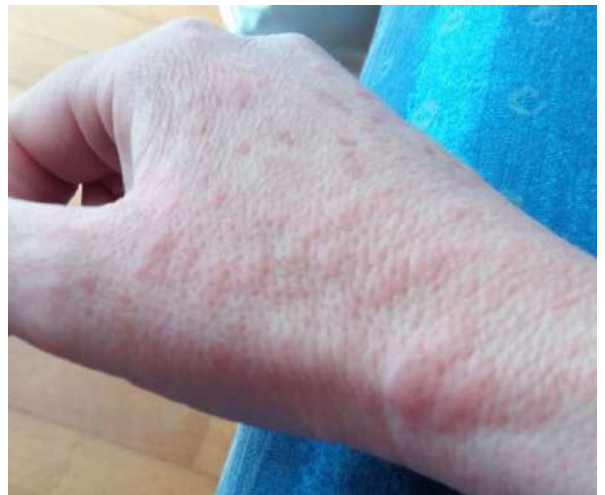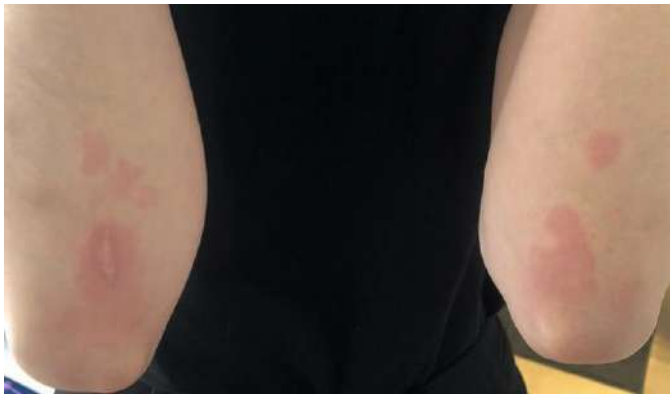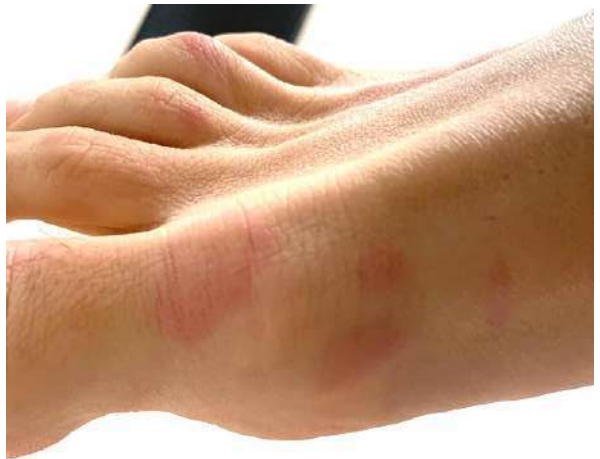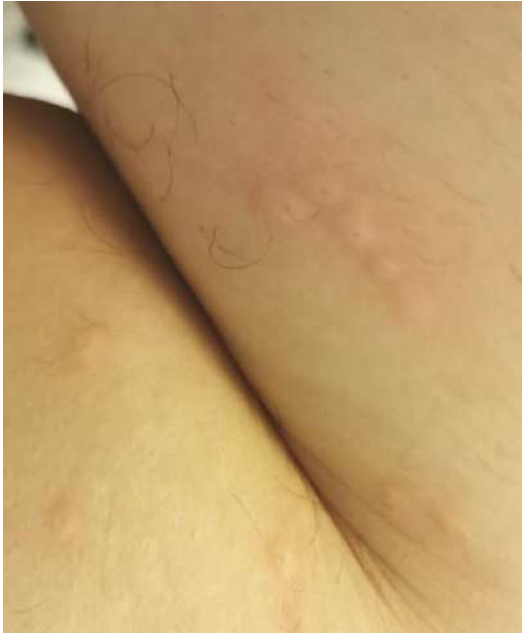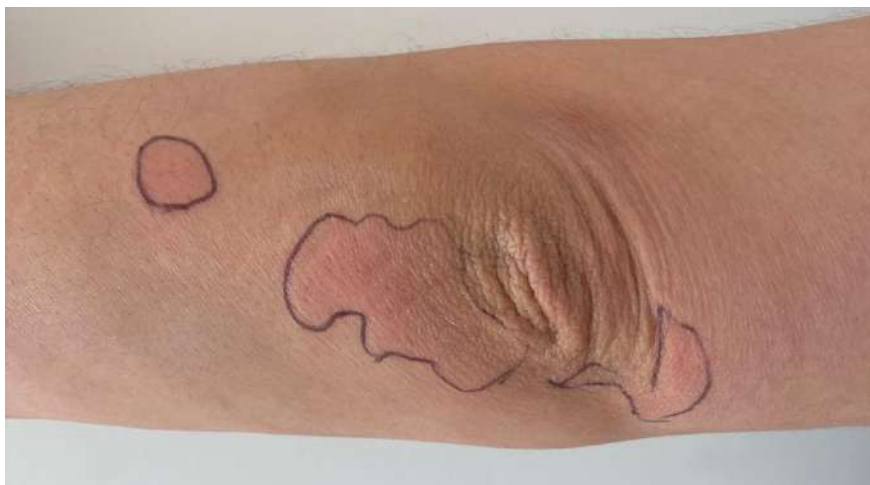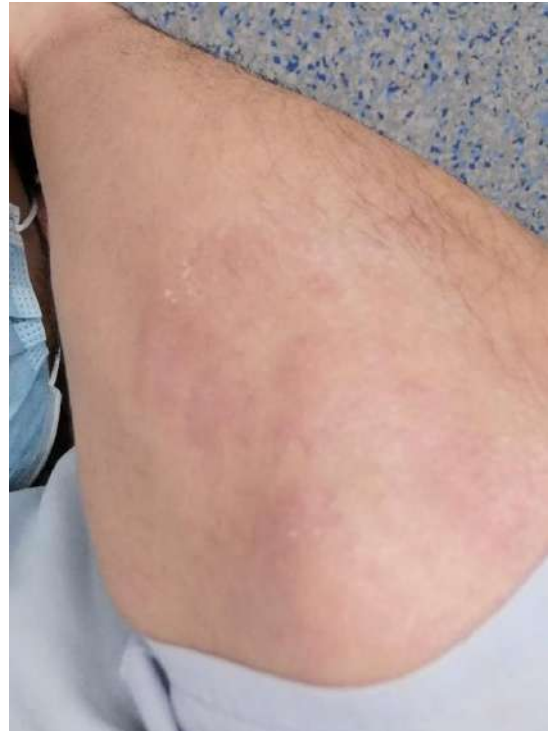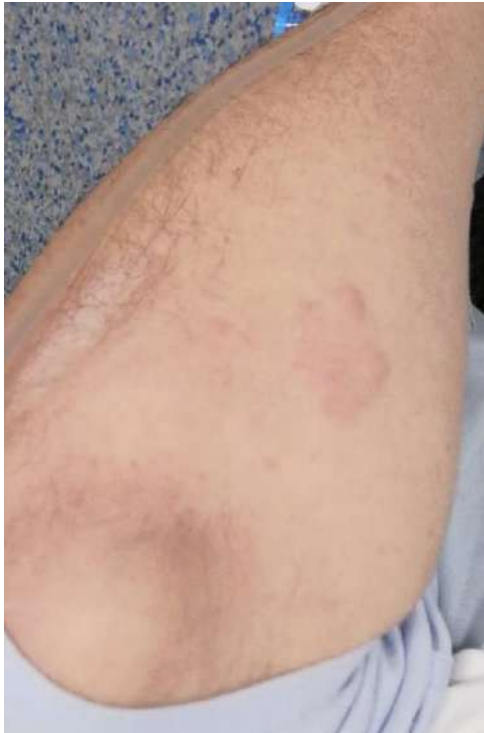## Urticarial Eruption – Confirmed cases

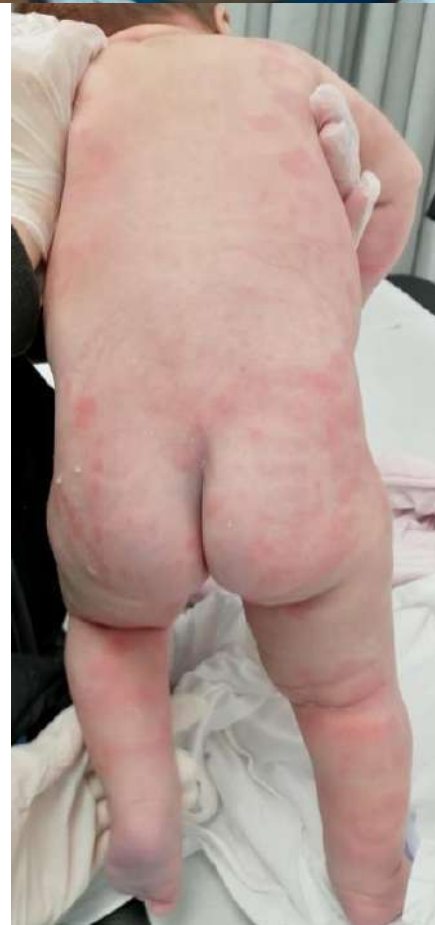
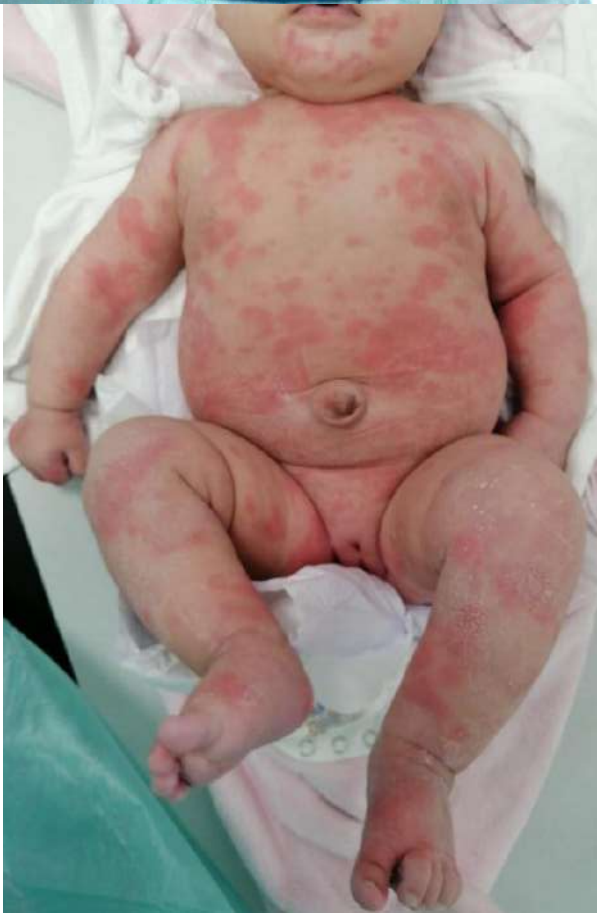
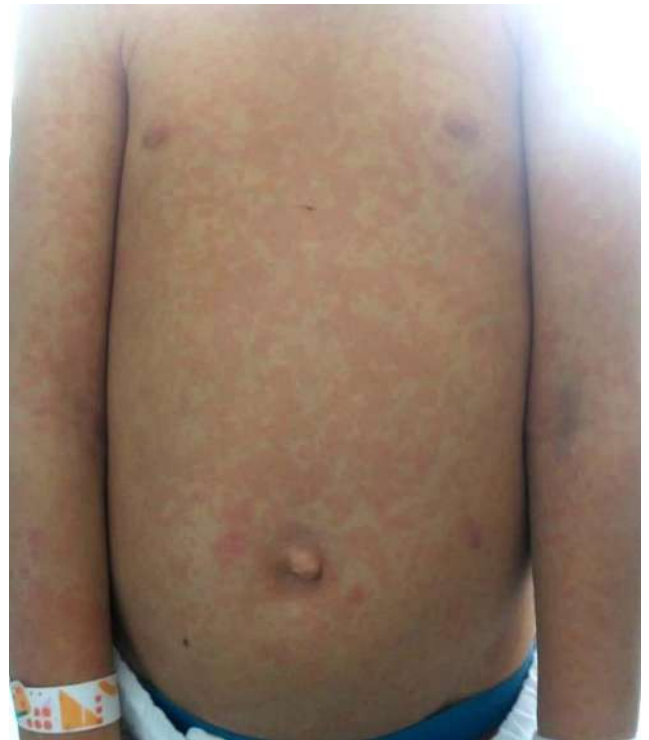
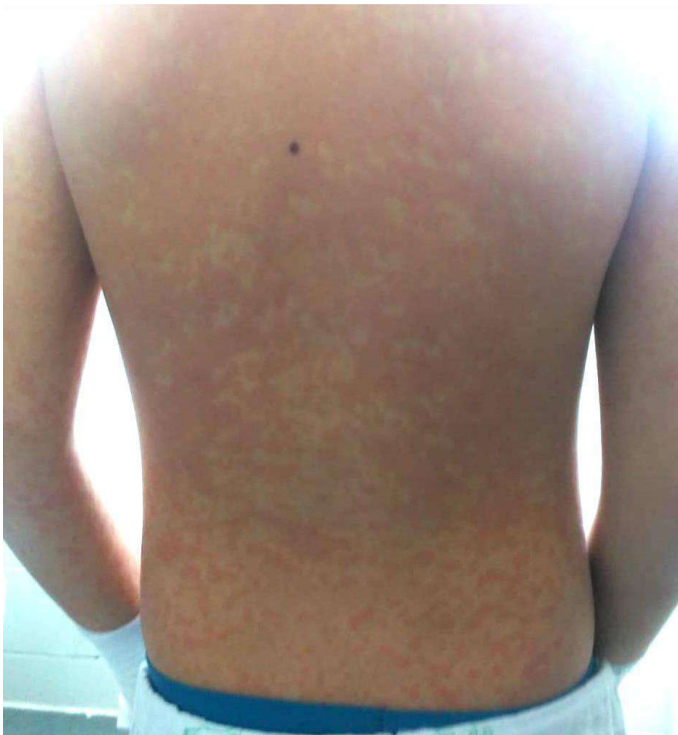




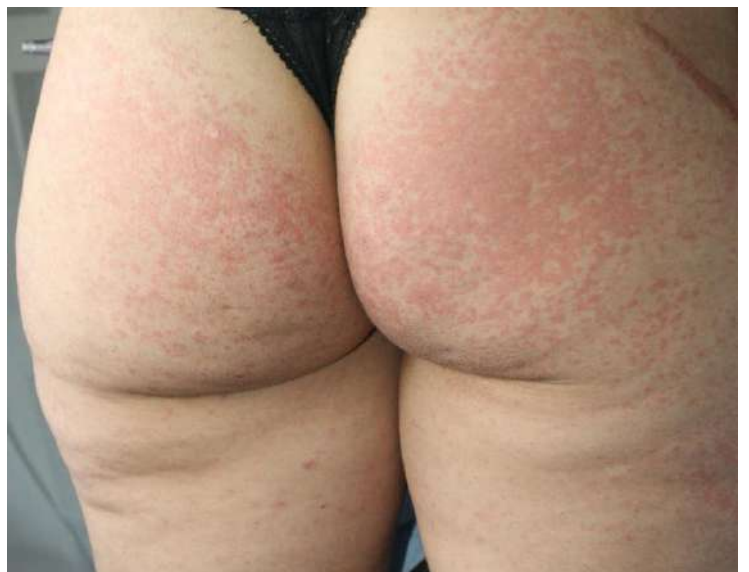
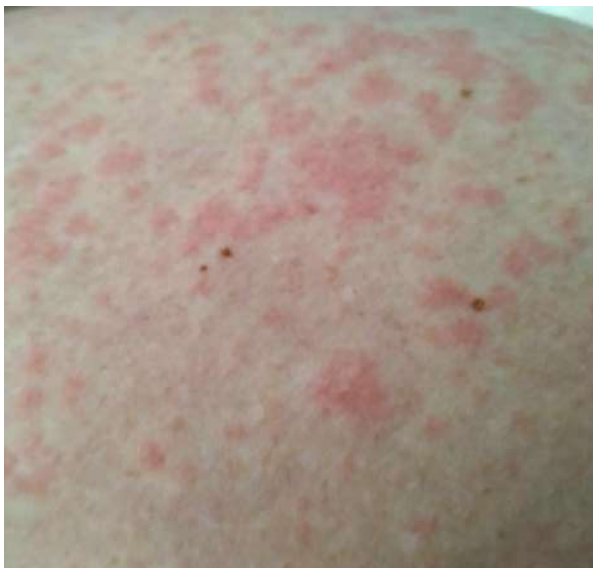
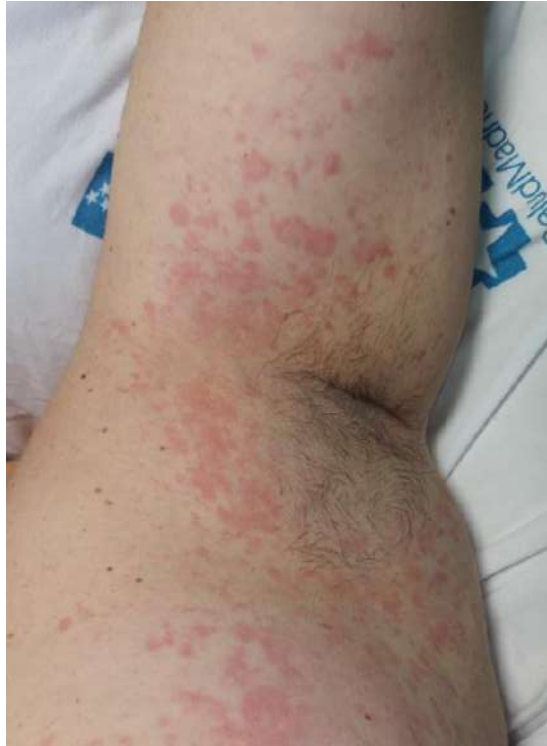
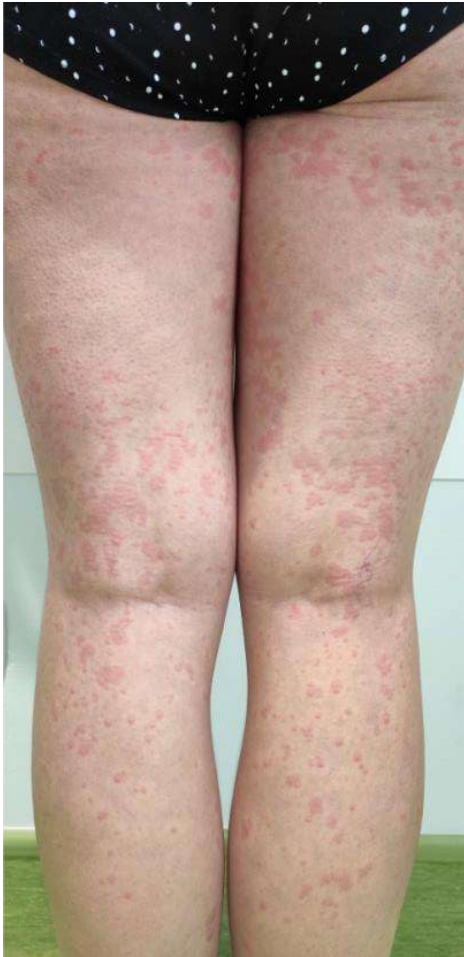


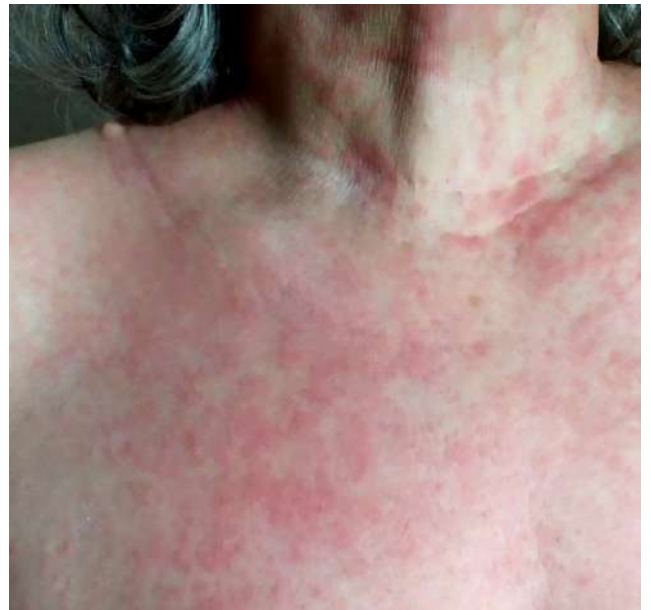
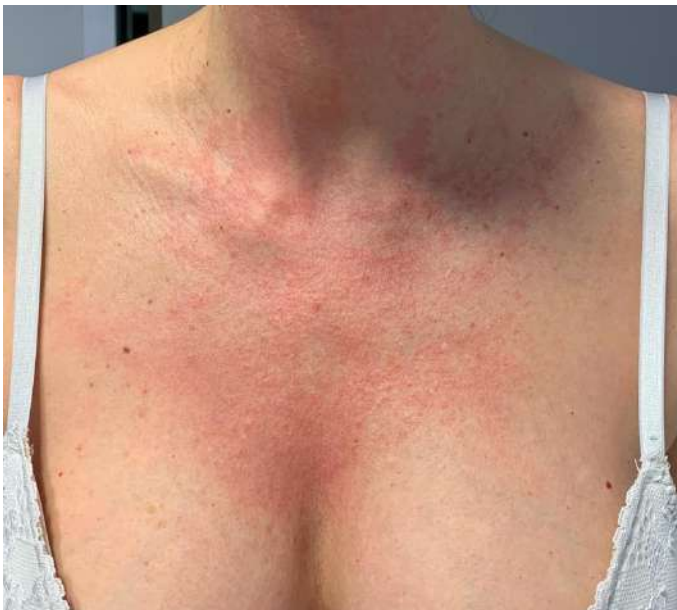
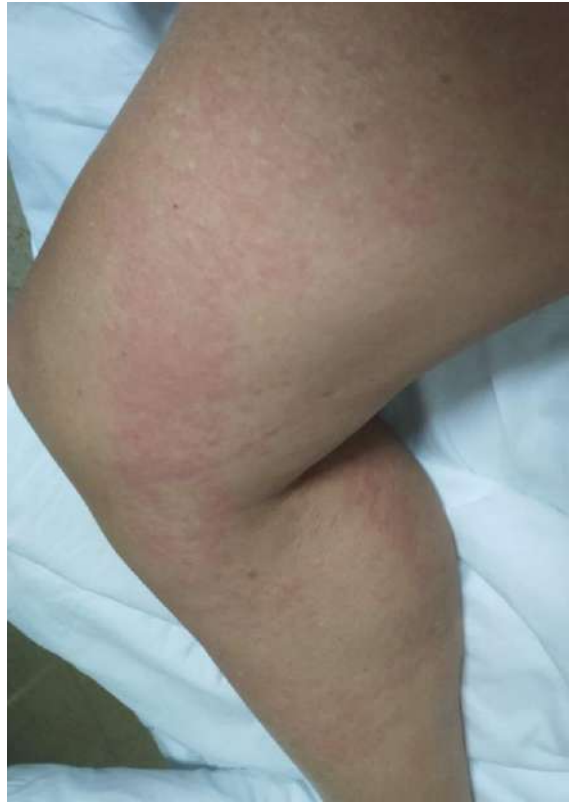
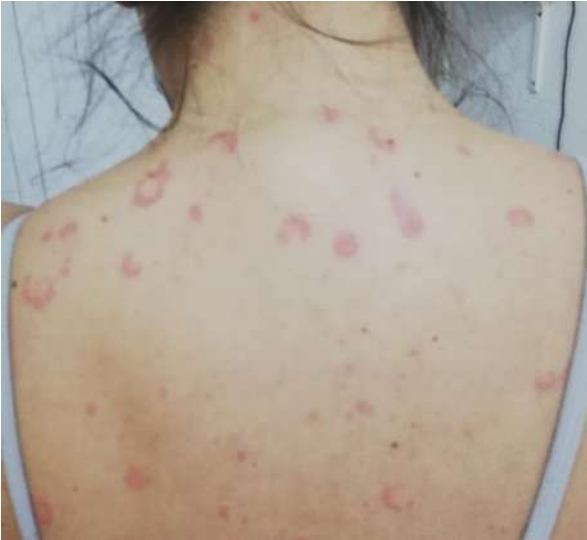


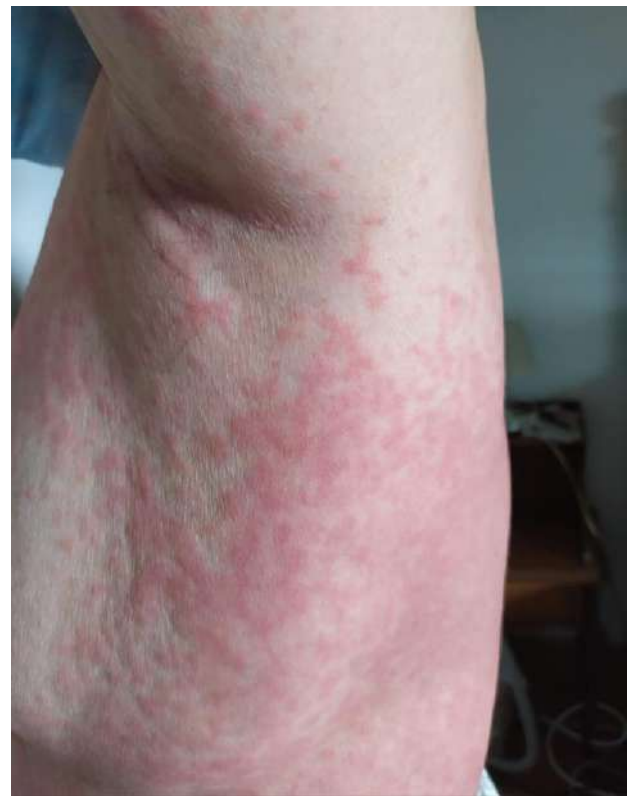
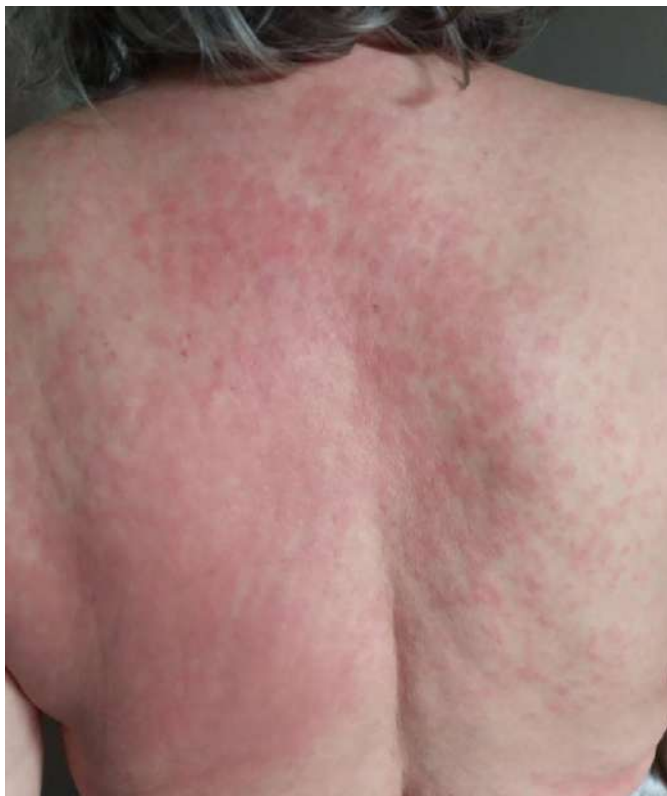
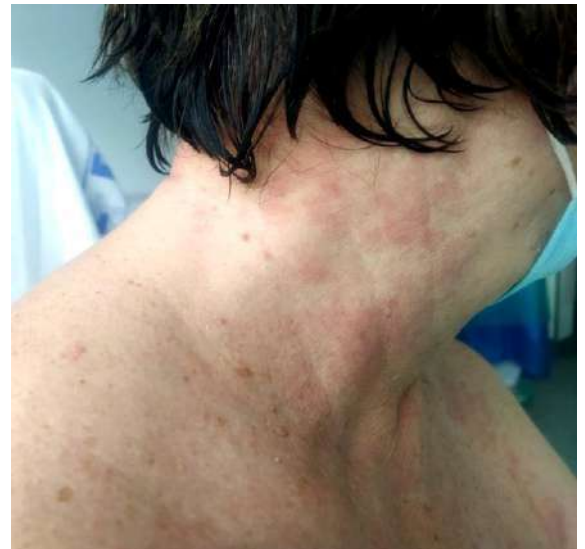
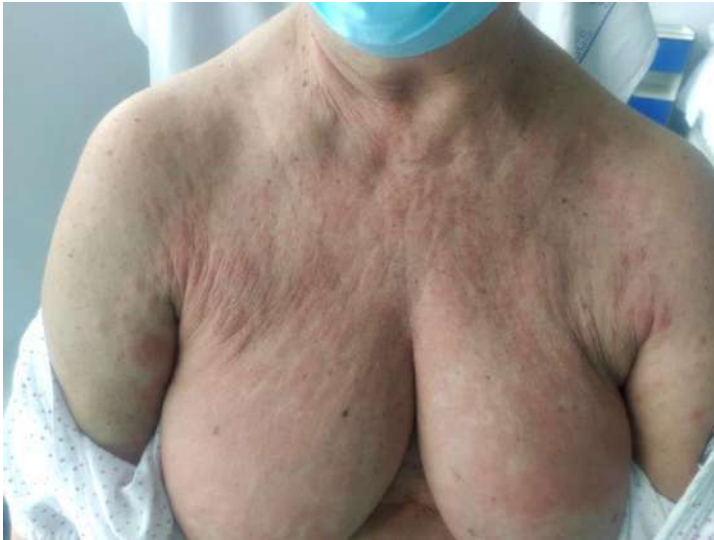
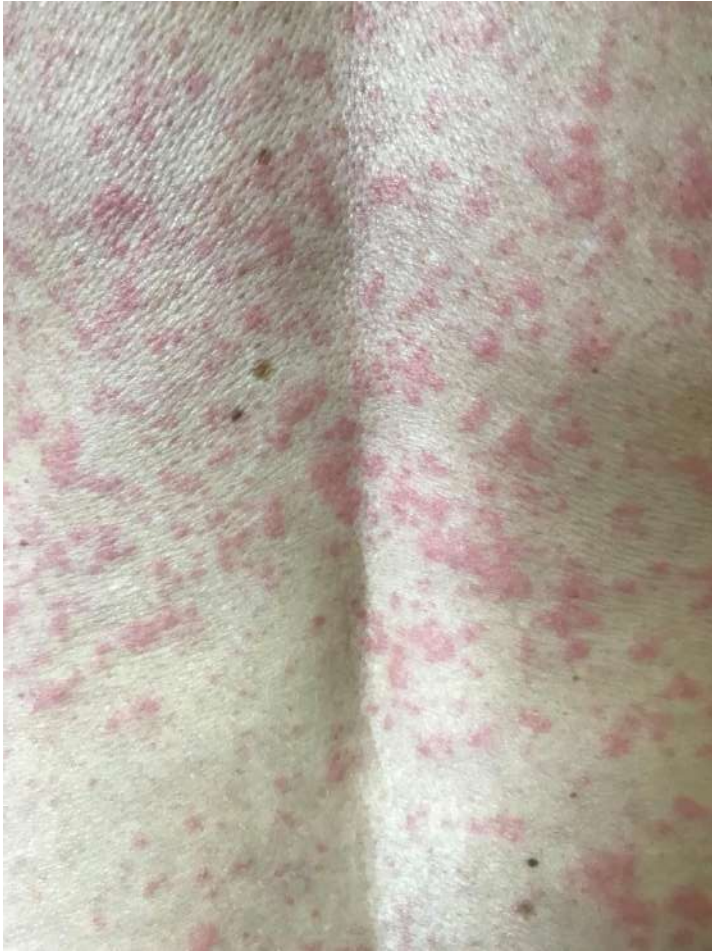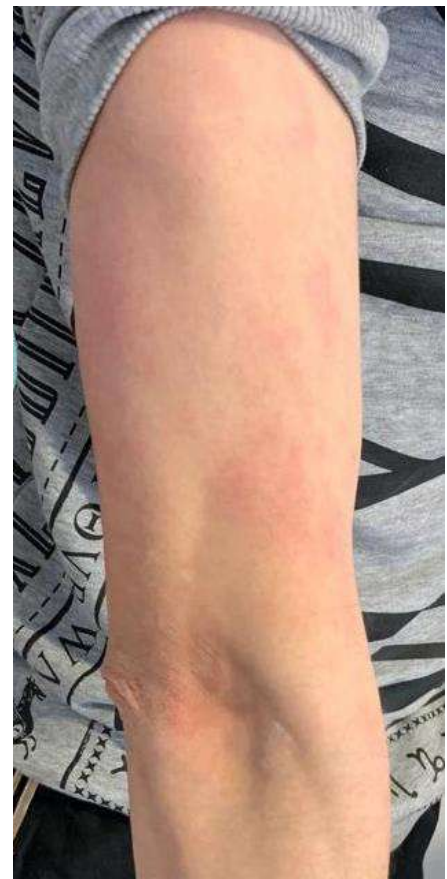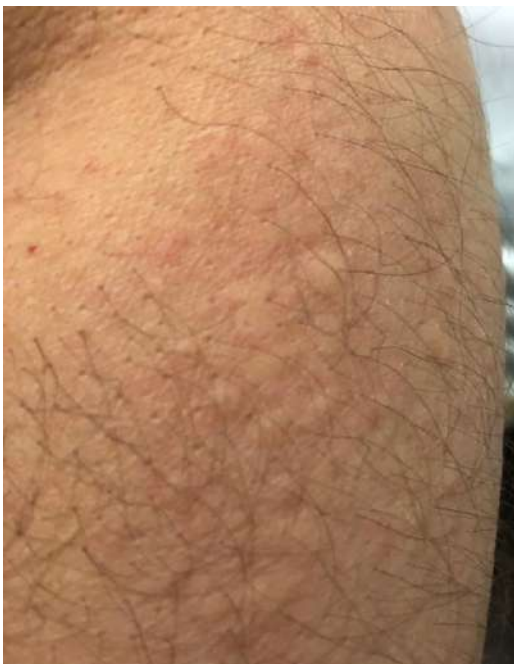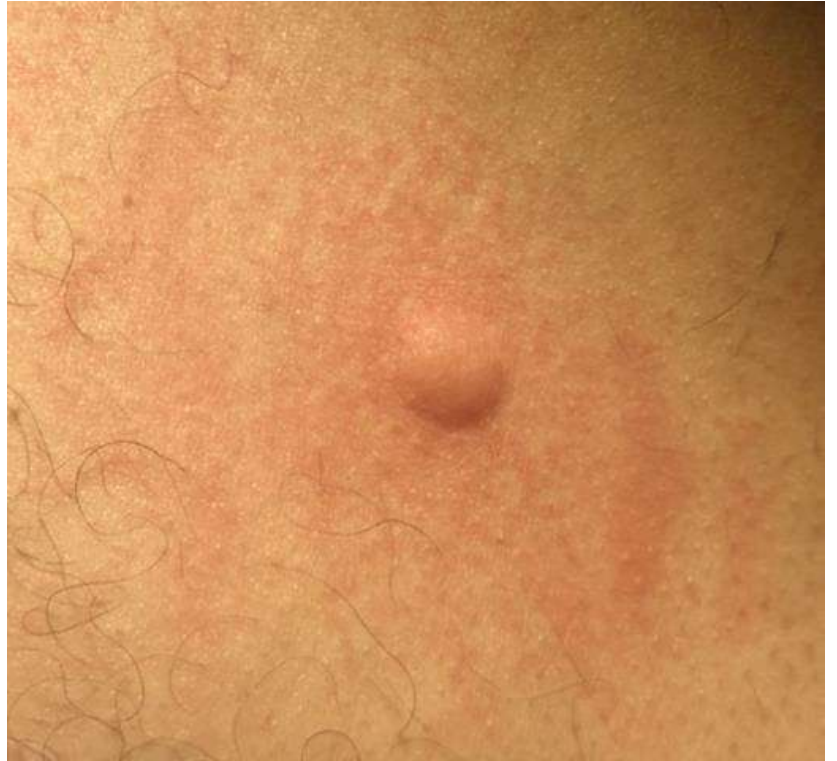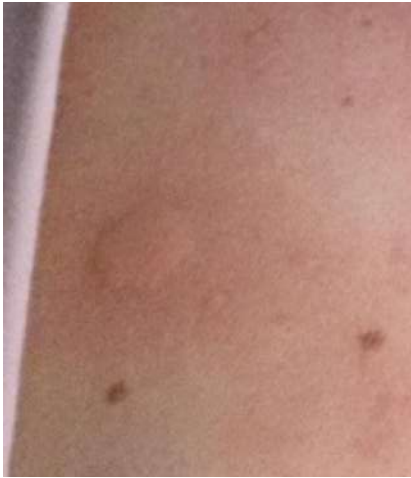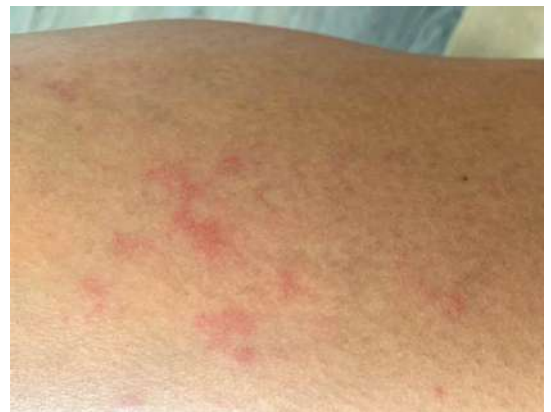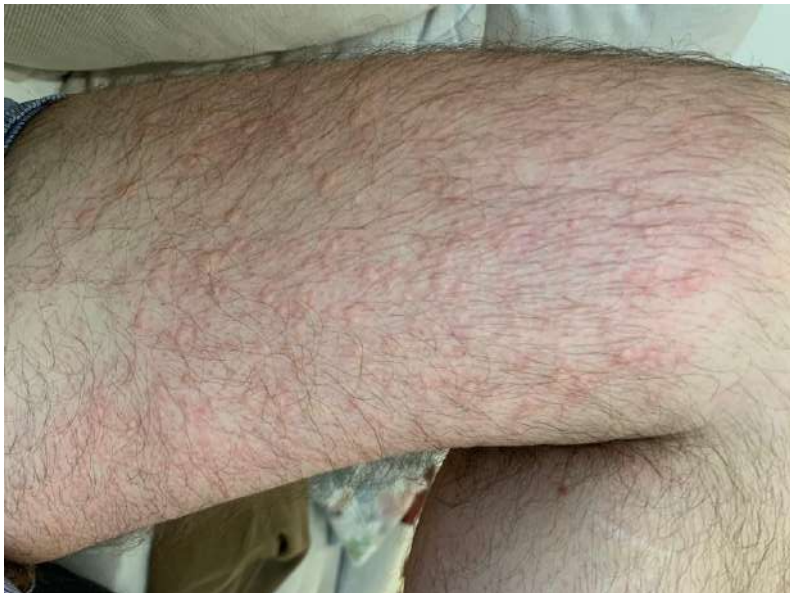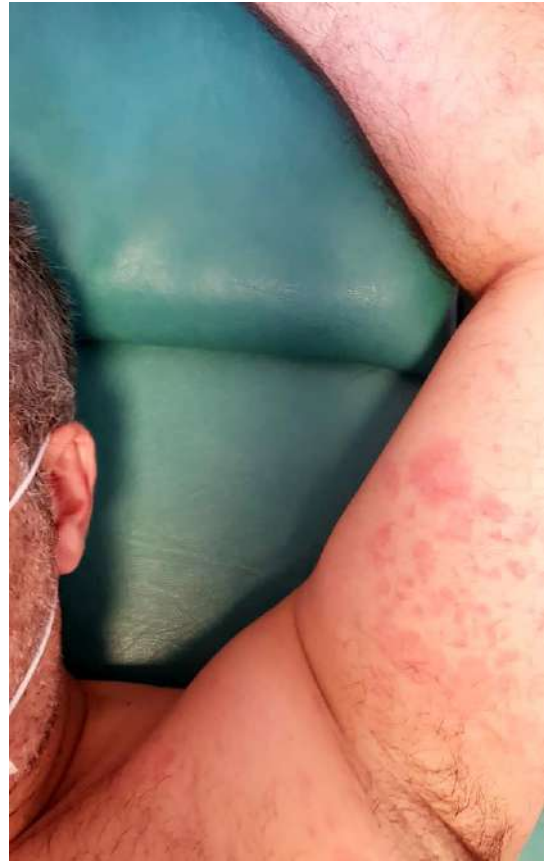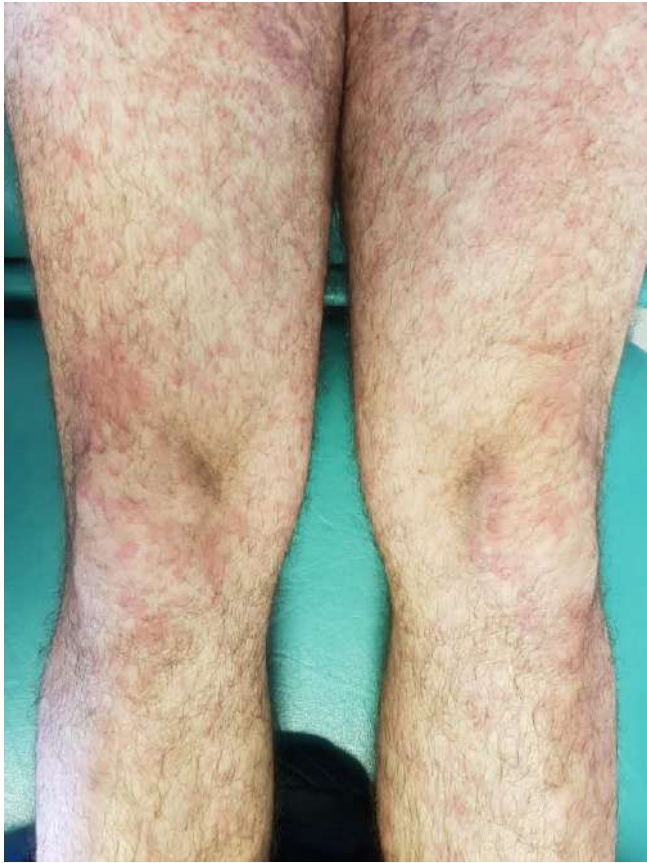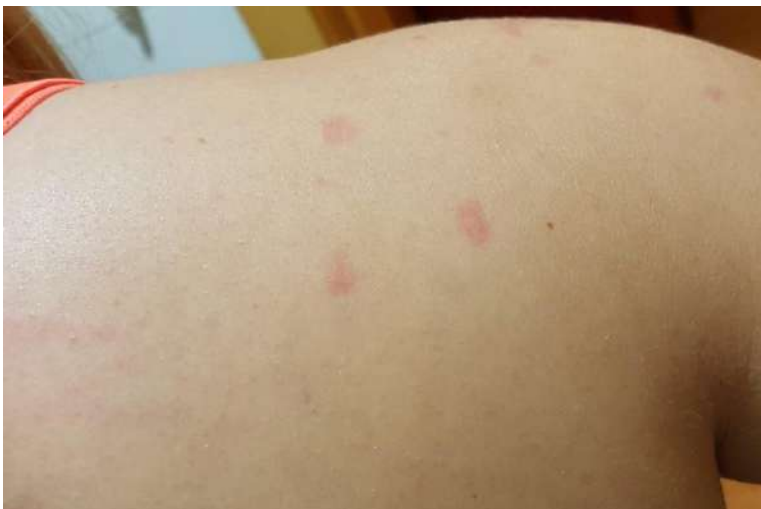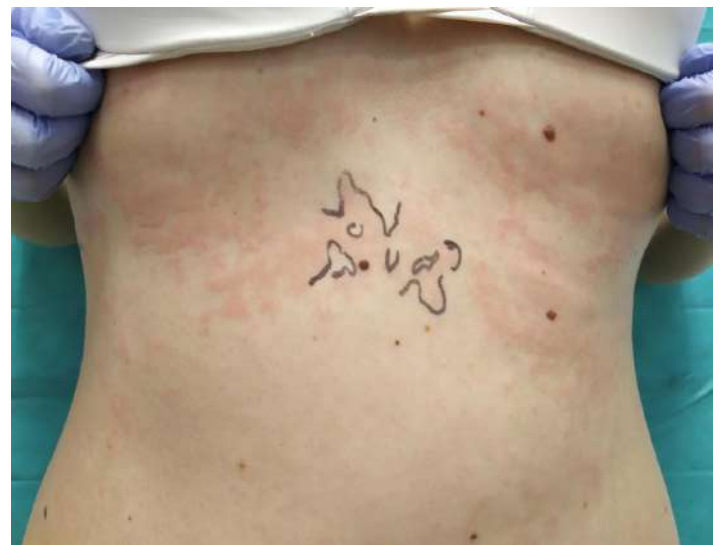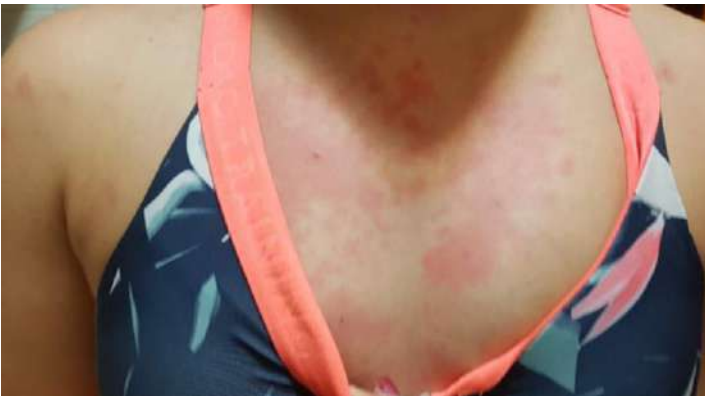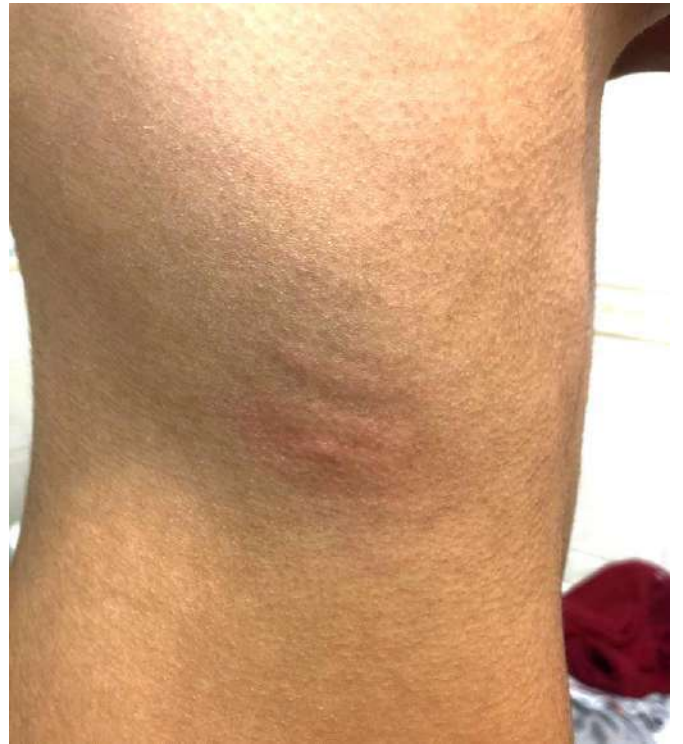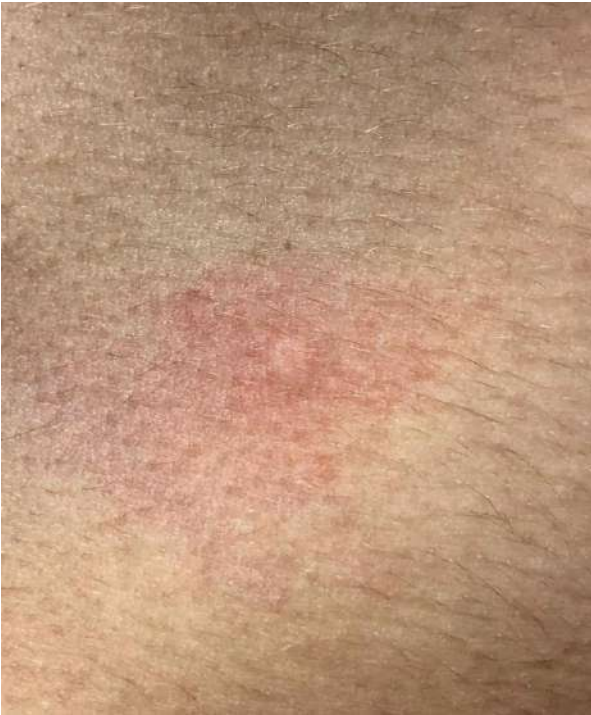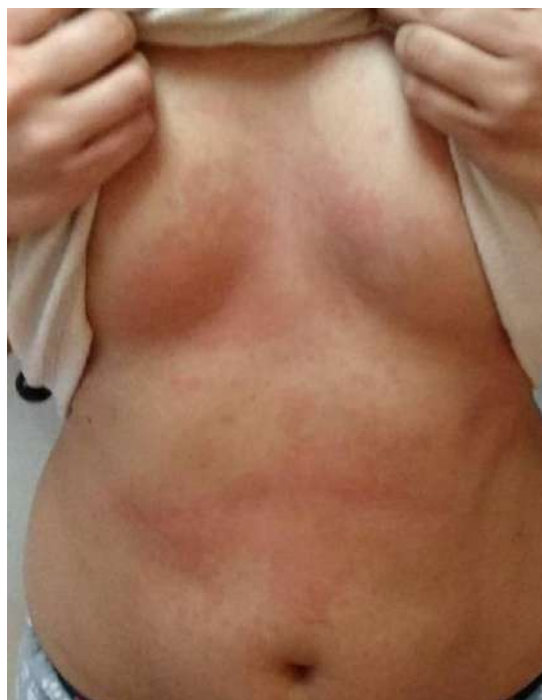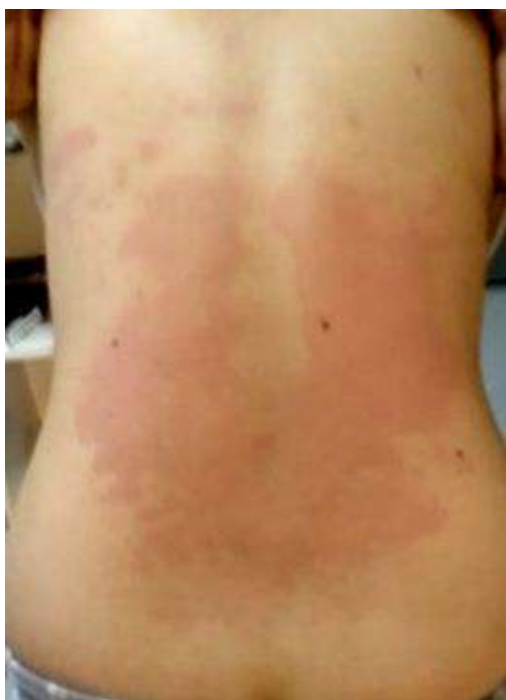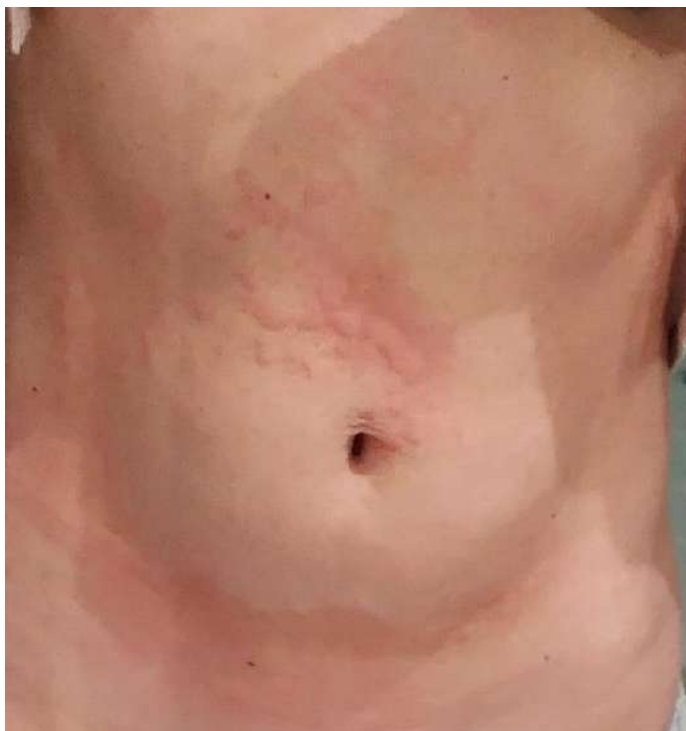## Urticarial Eruption – Suspected cases





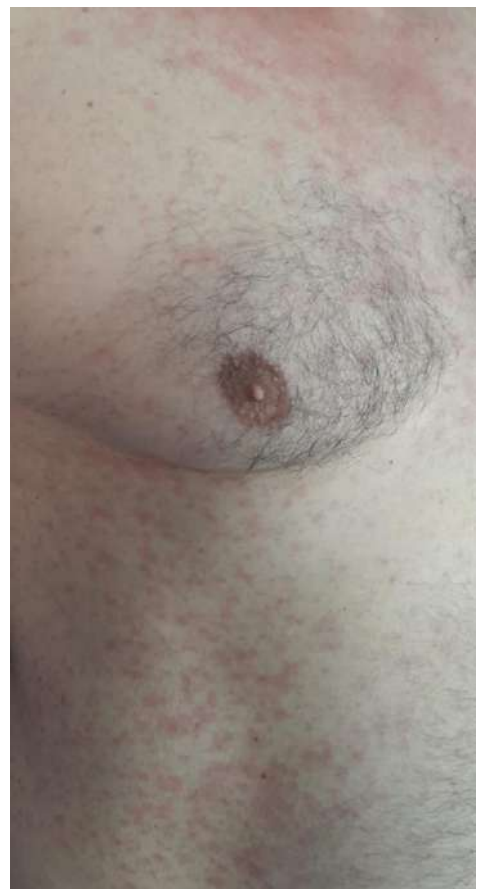
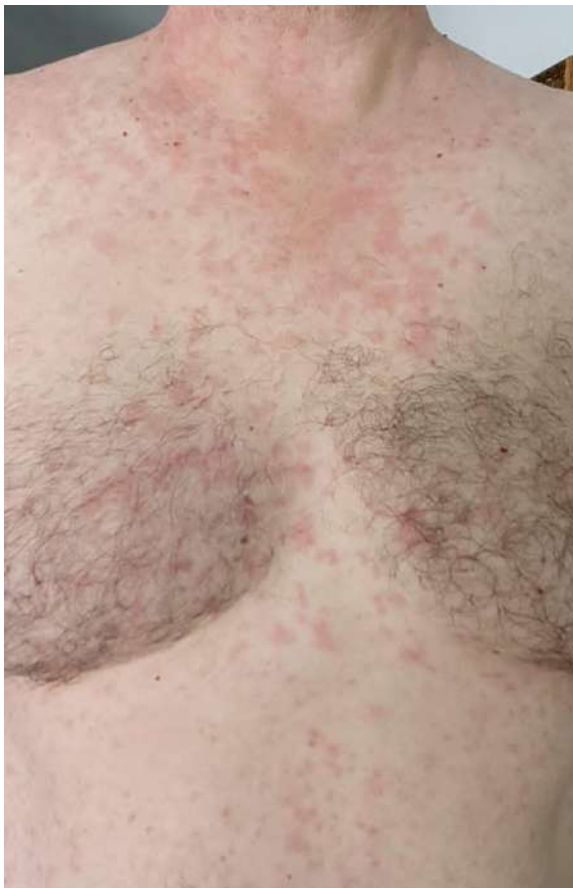
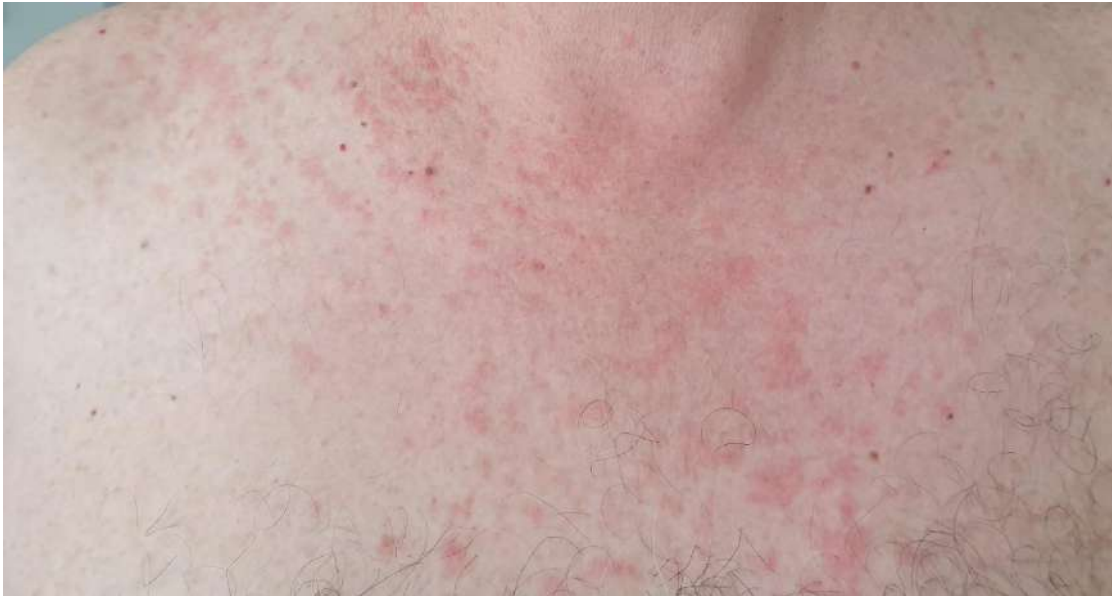


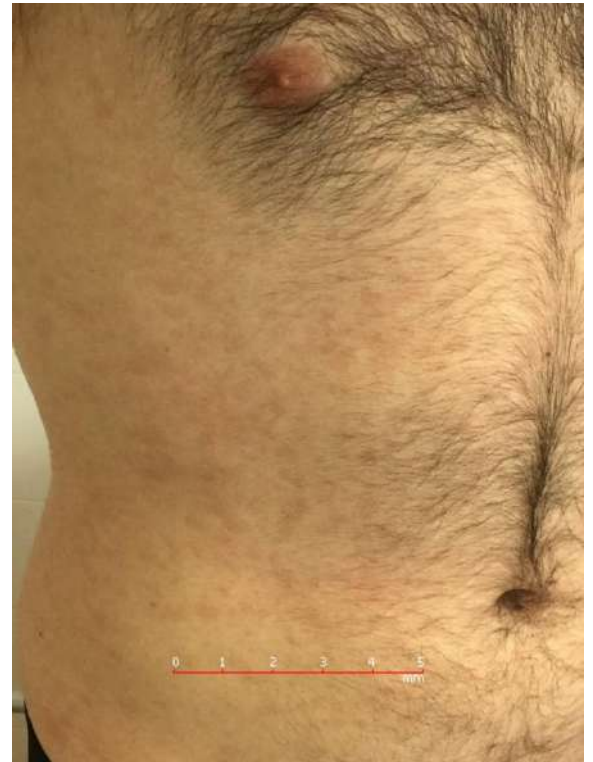


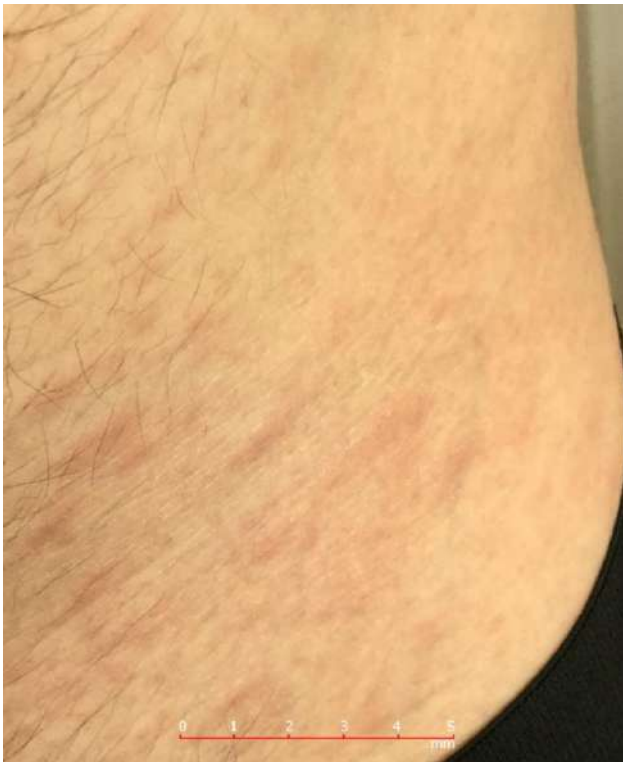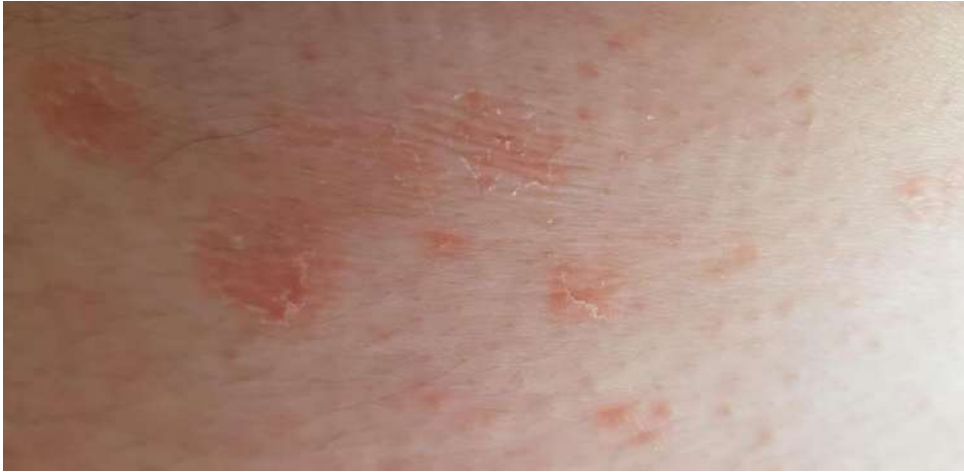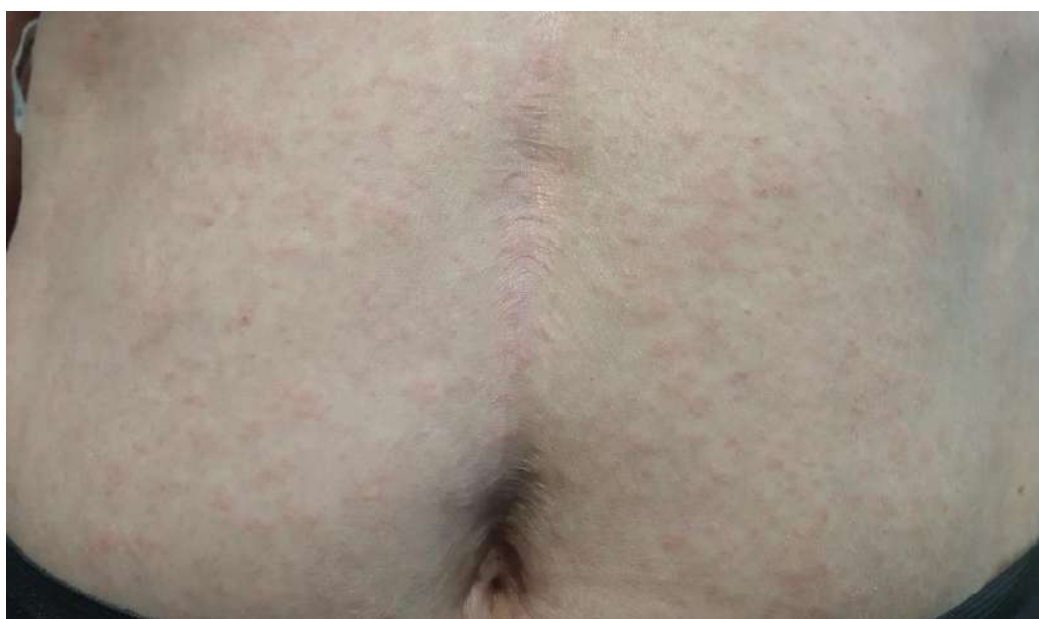
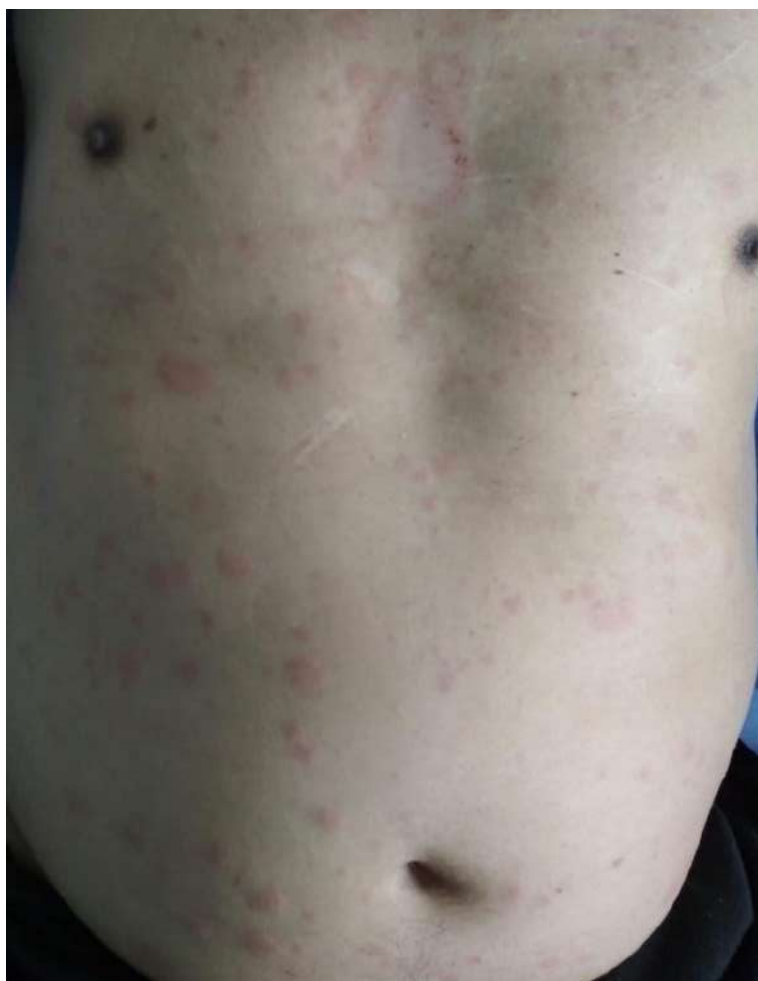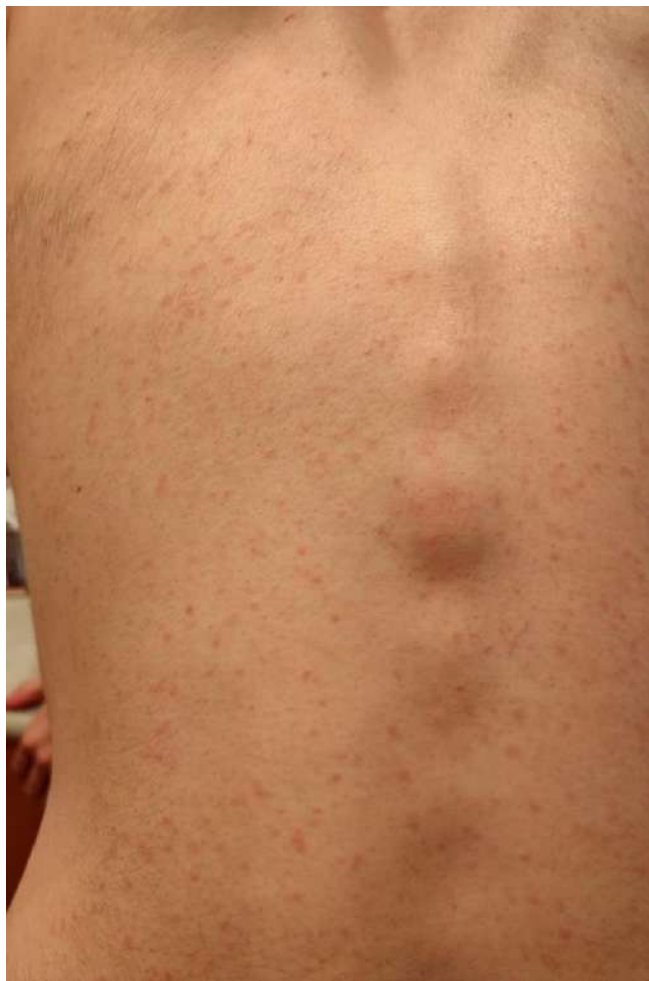## Maculopapular eruption – Confirmed cases

Pityriasis rosea-like

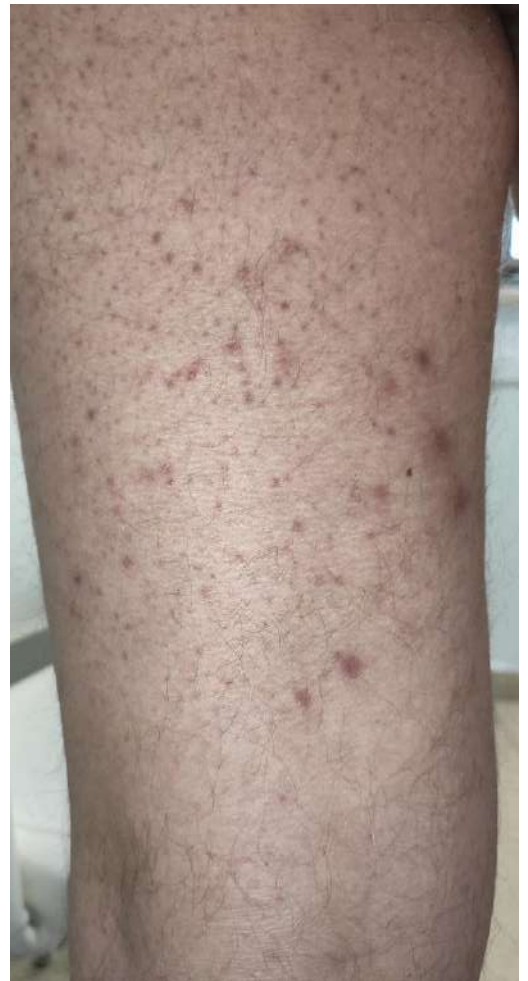
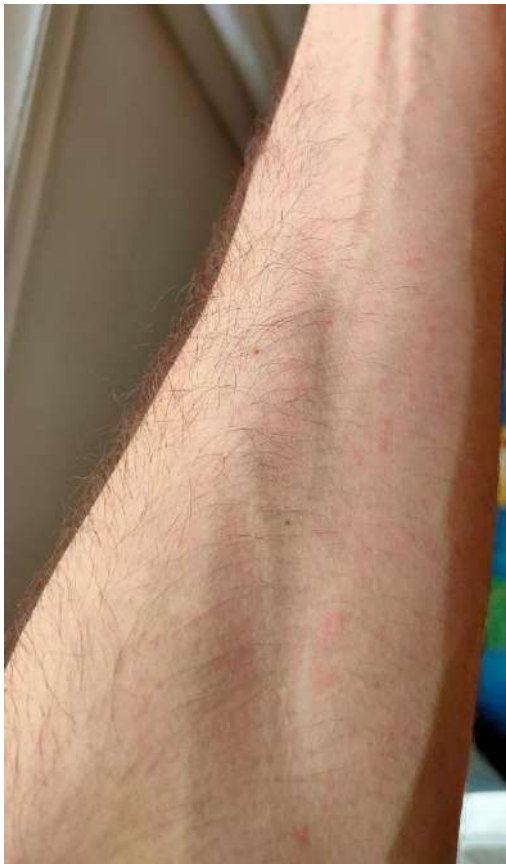
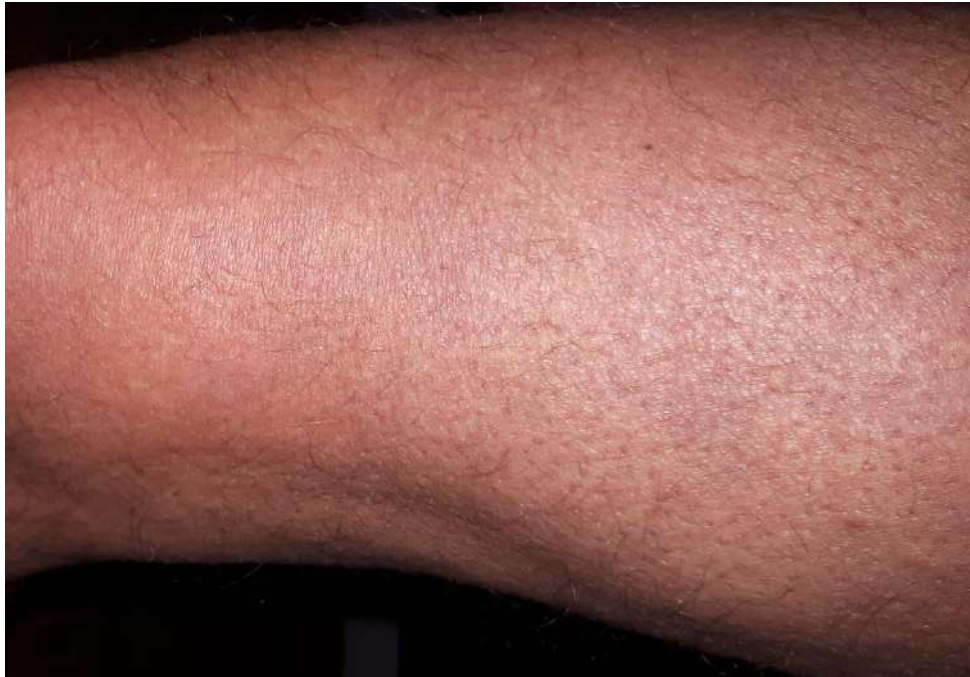




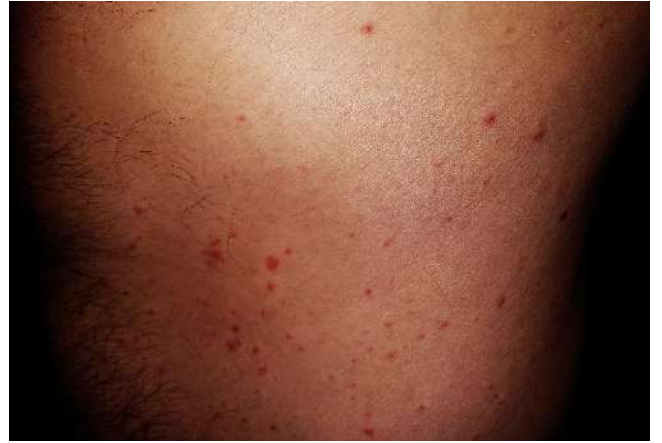
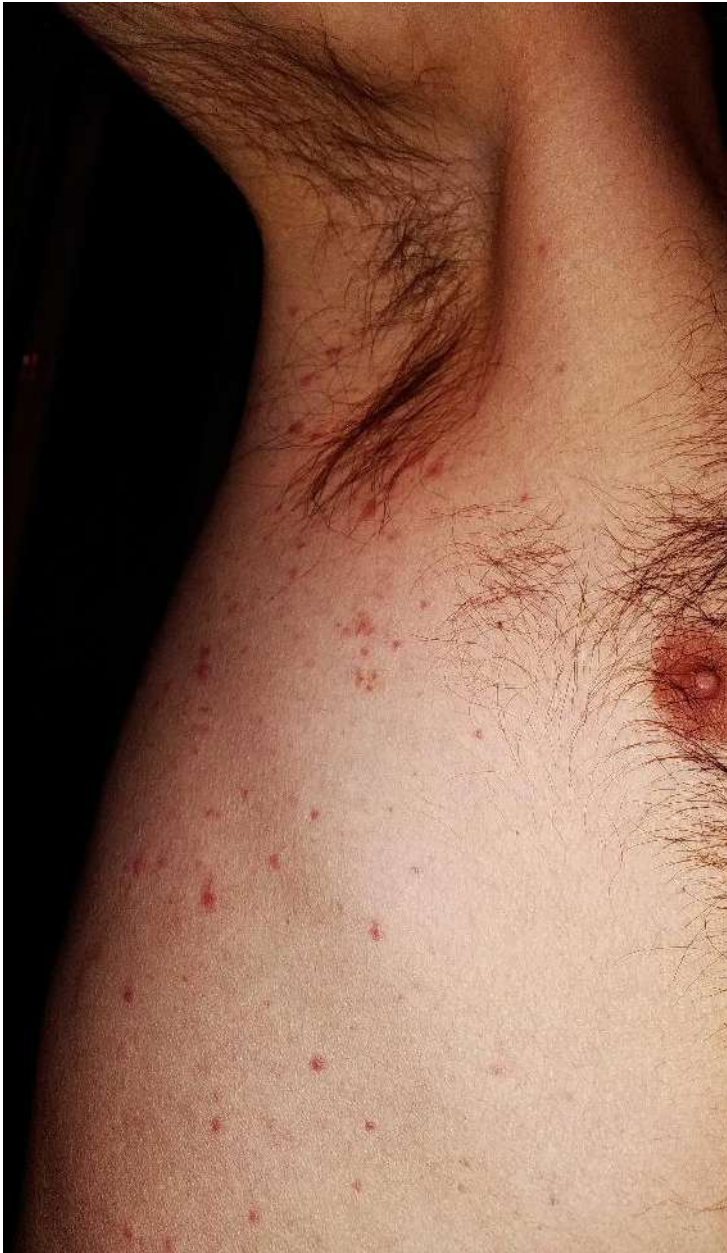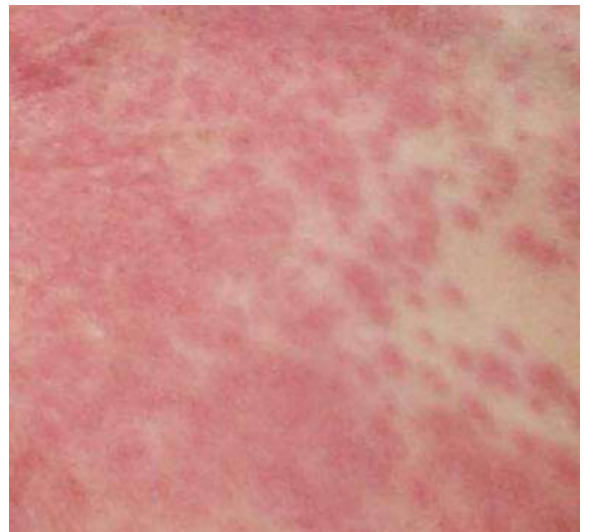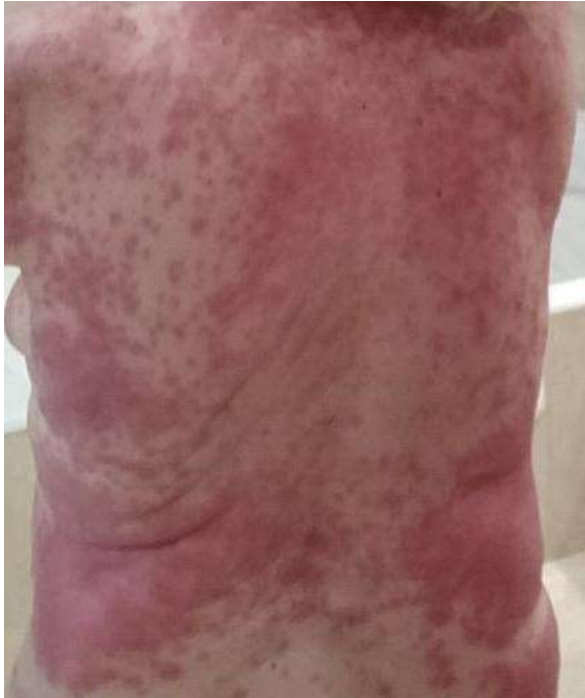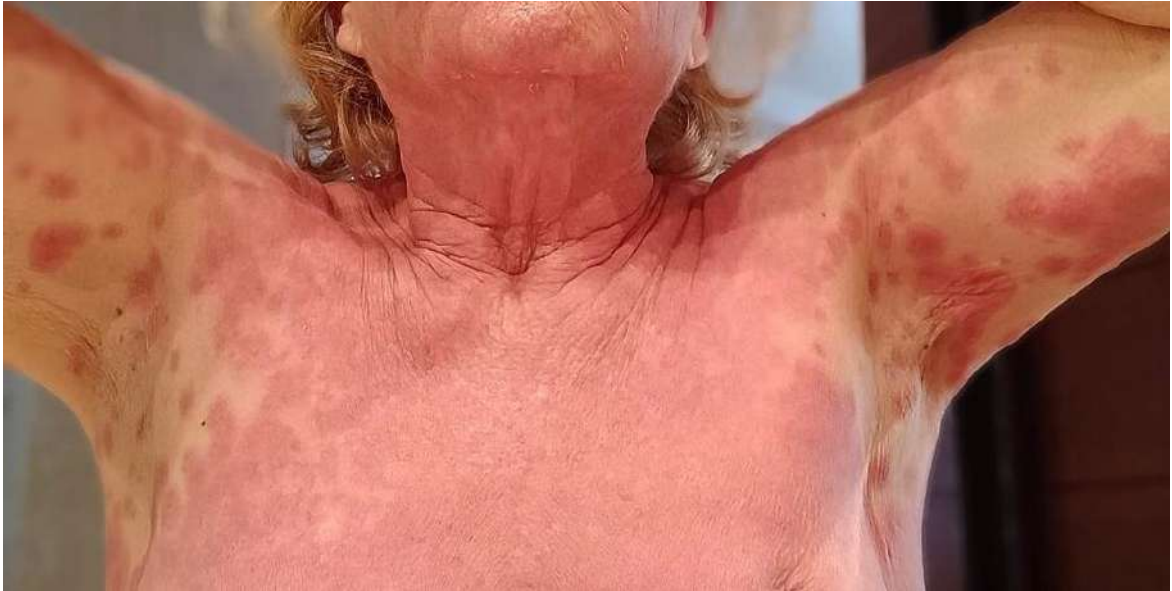## Perifollicular eruption

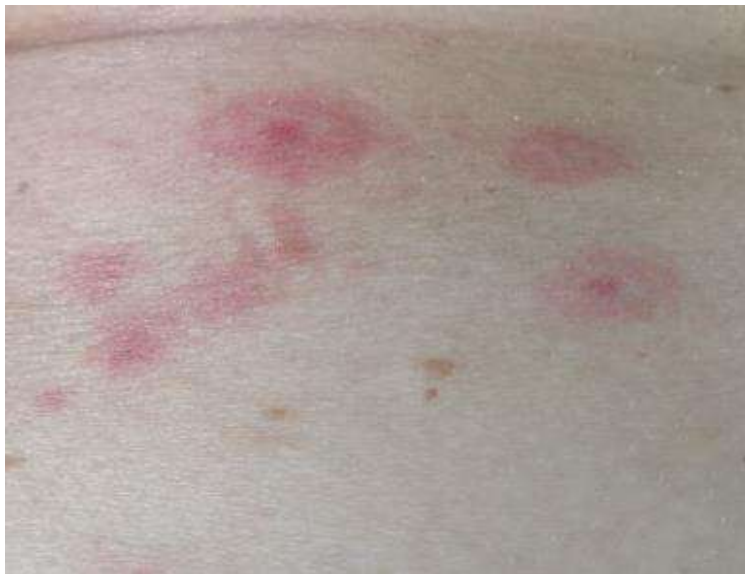
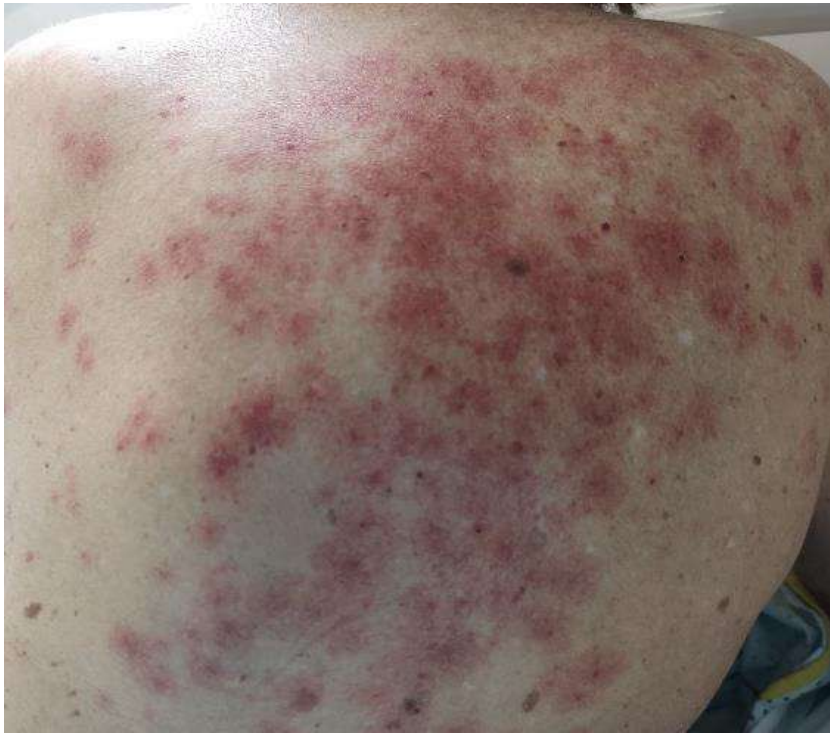




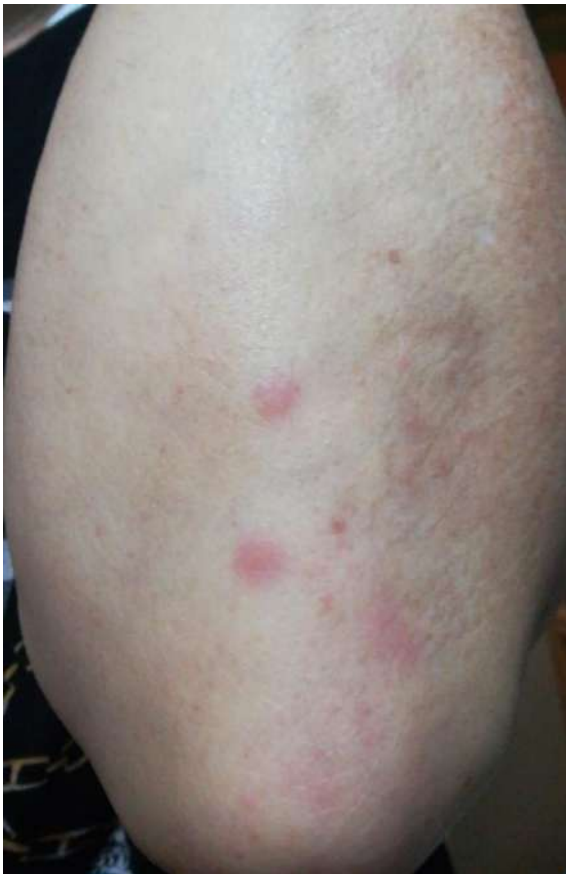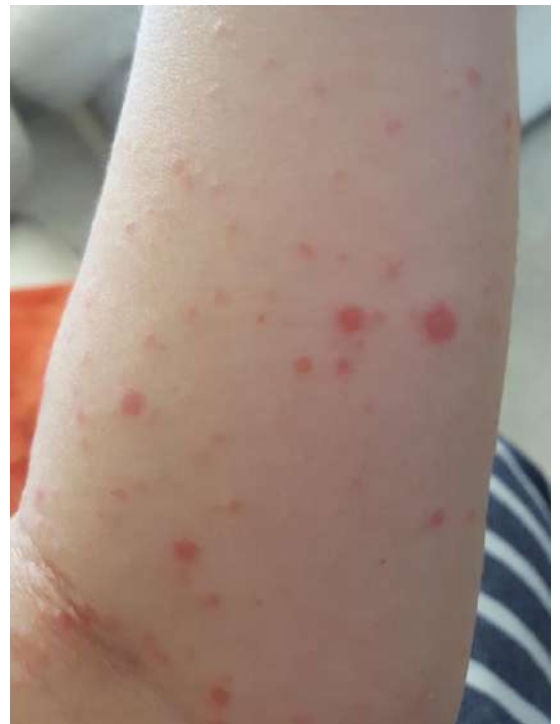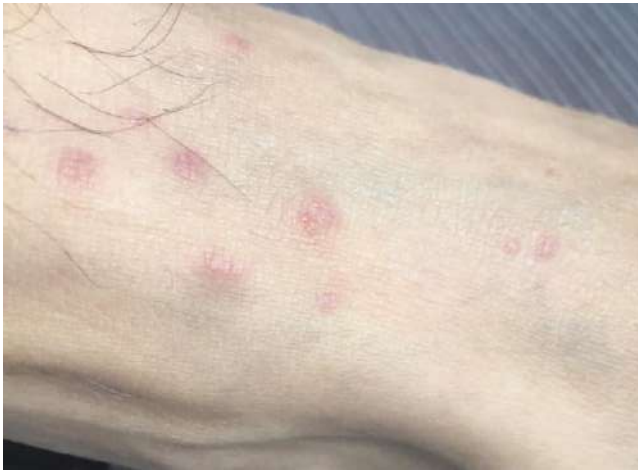Erythema multiforme-like



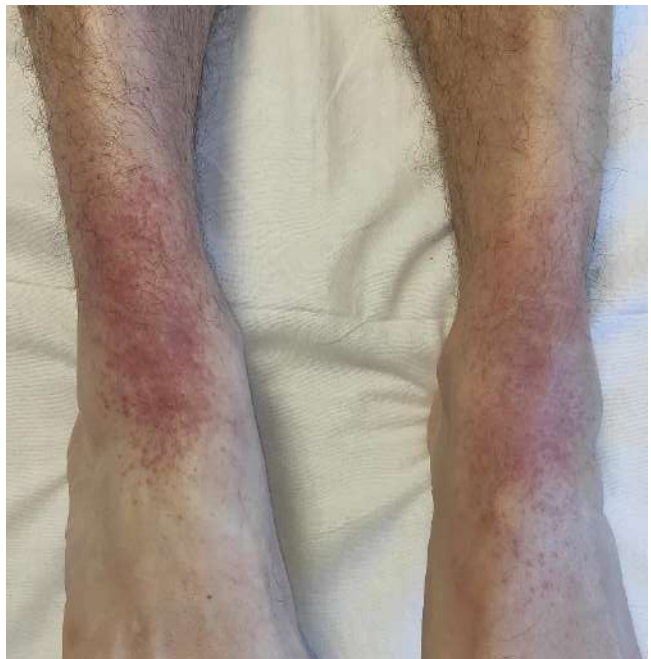
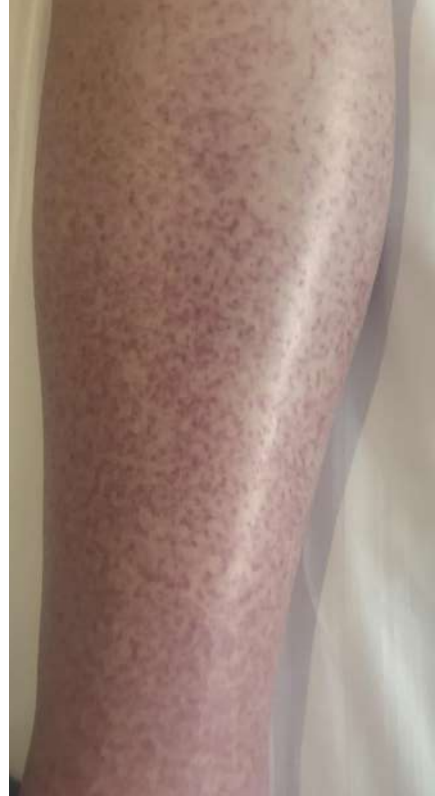
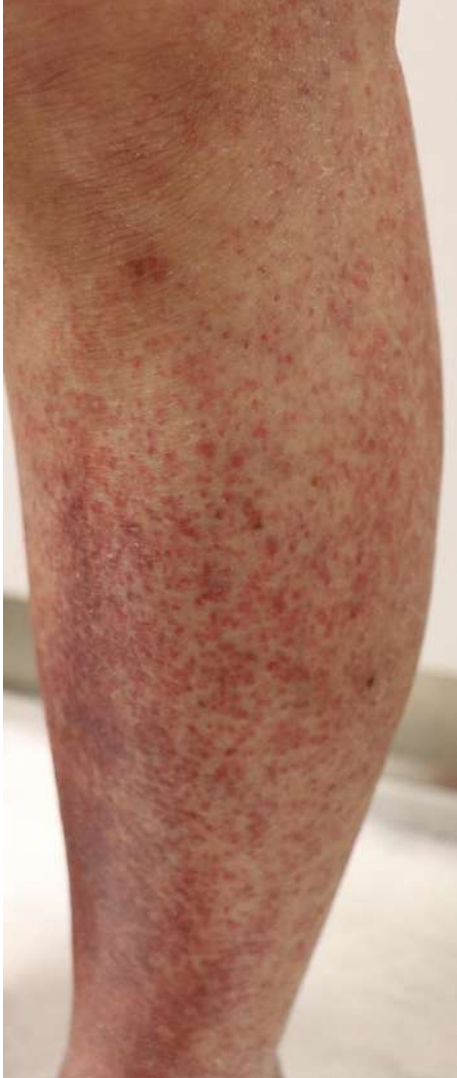

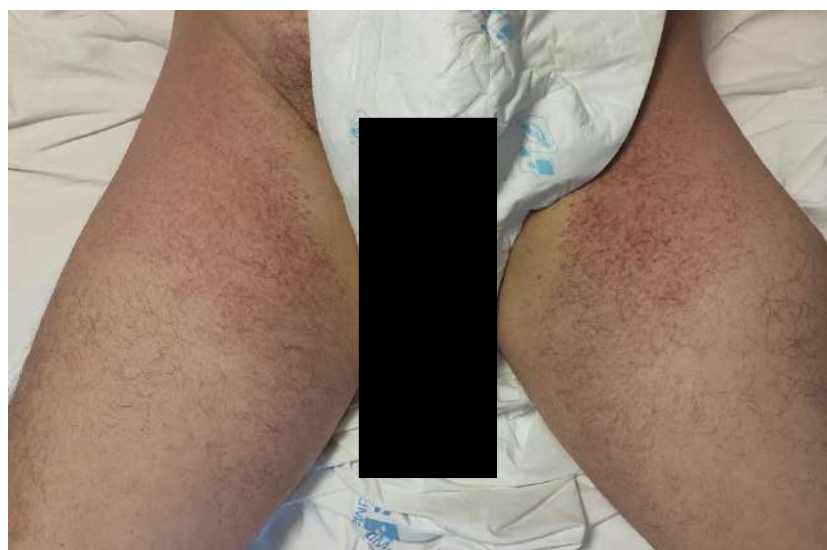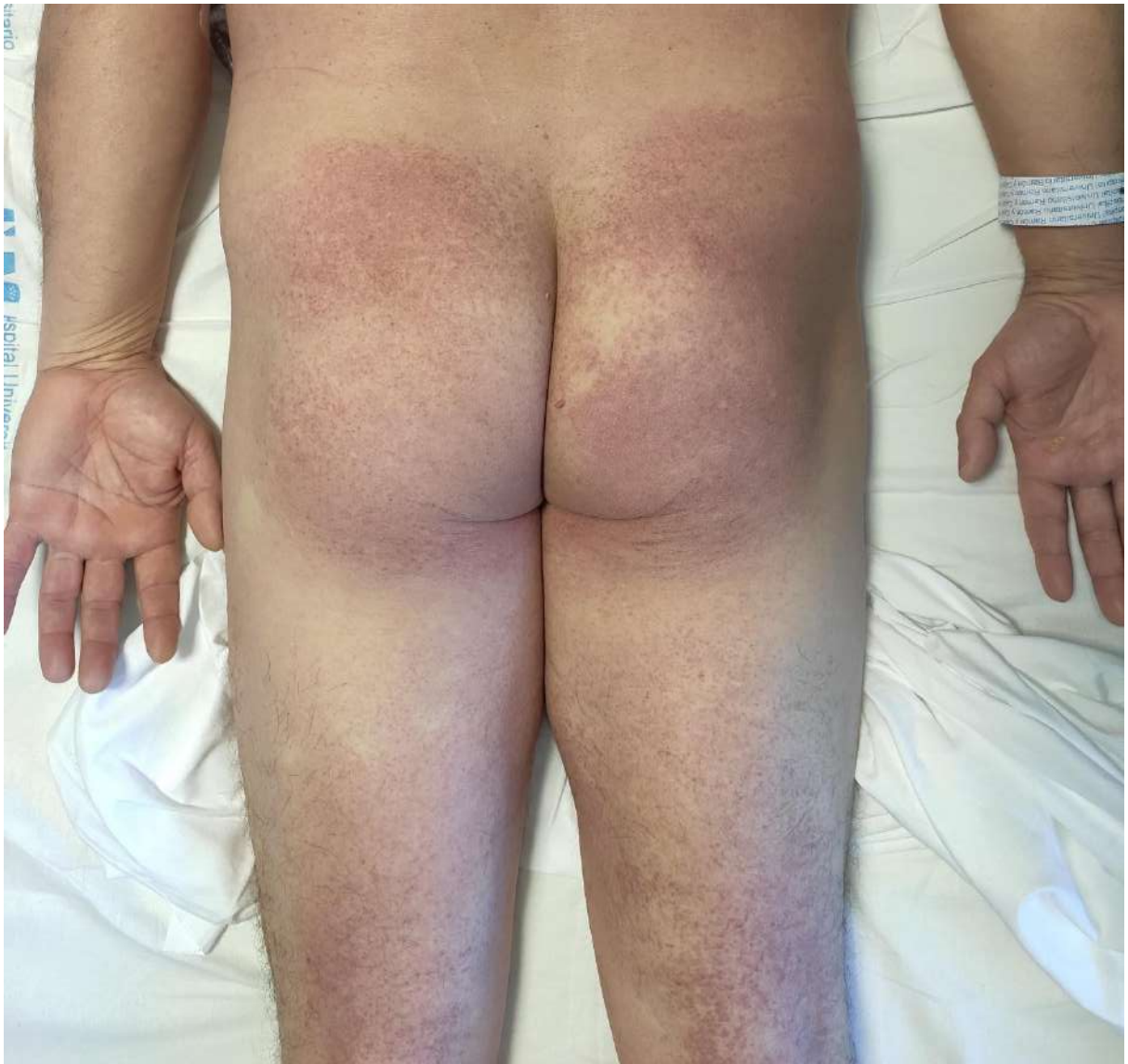Pseudovesicular or resembling erythema elevatum diutinum



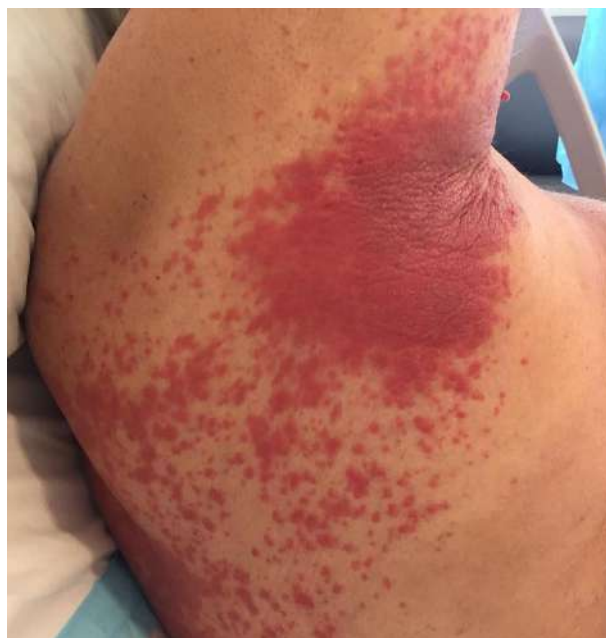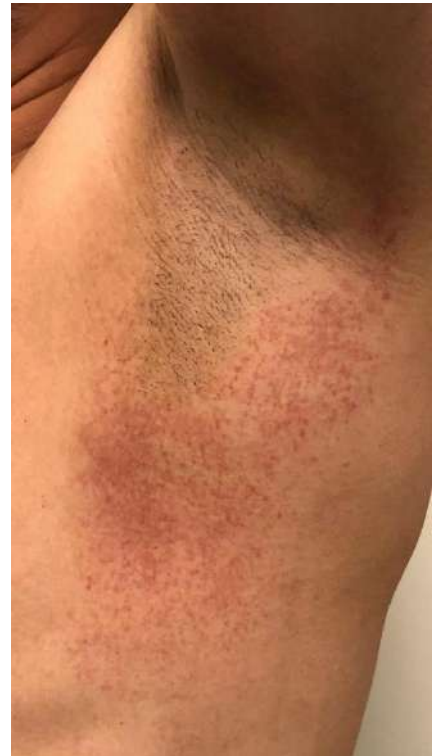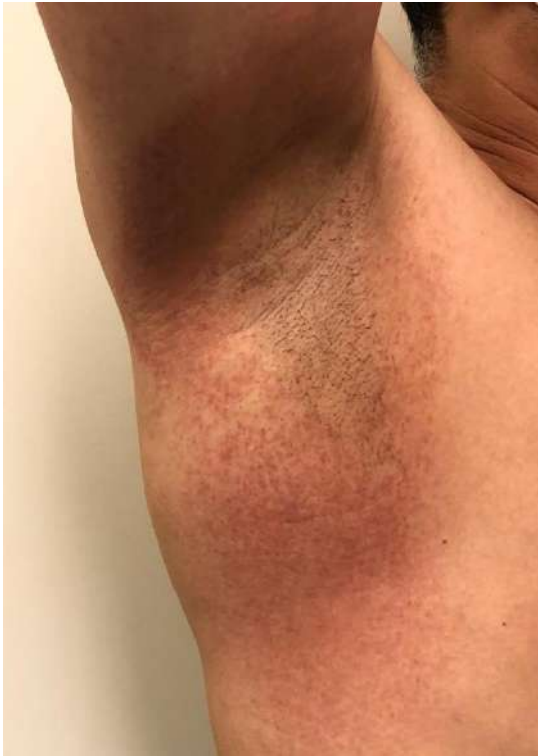## Purpuric eruptions

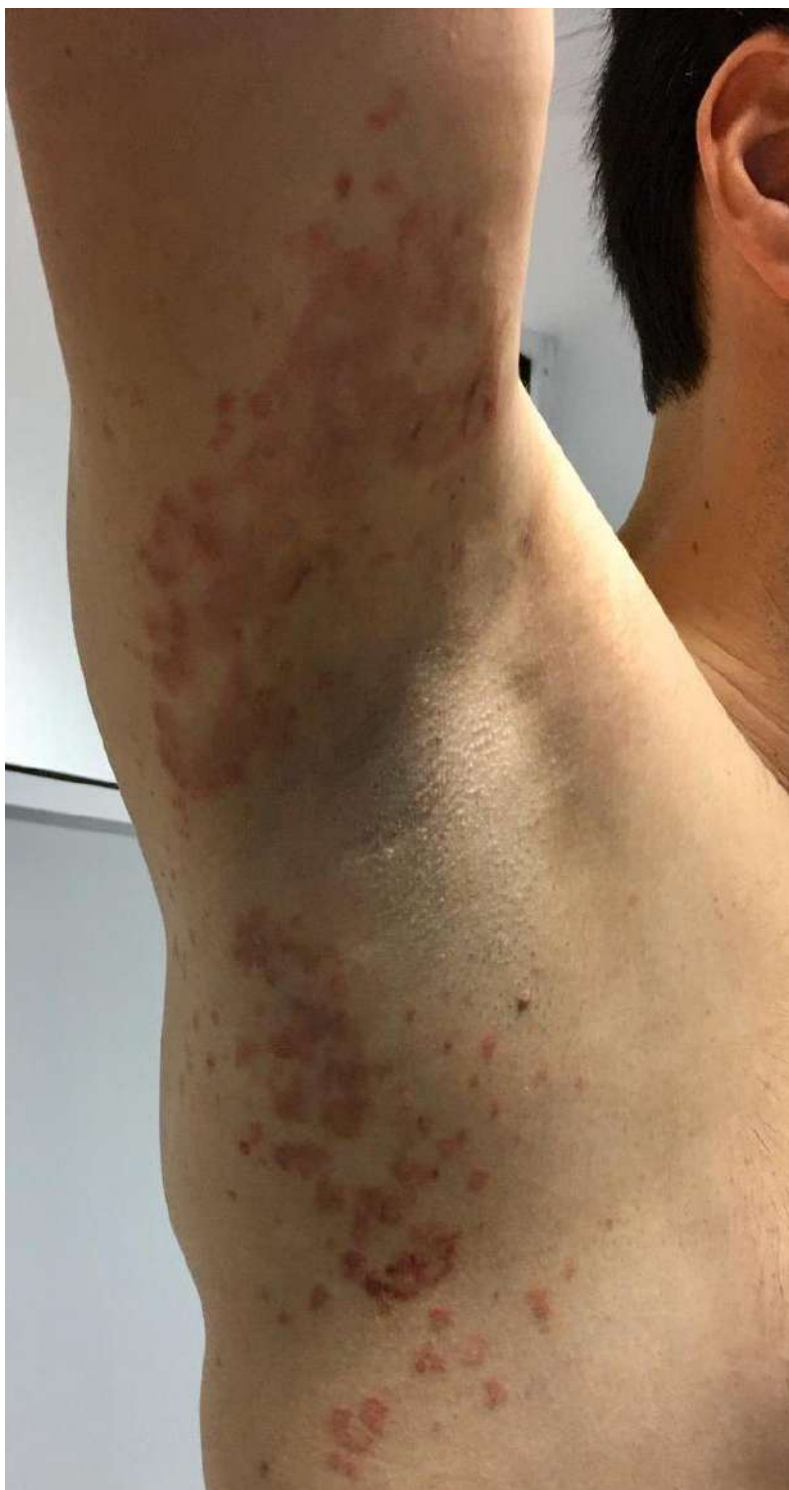




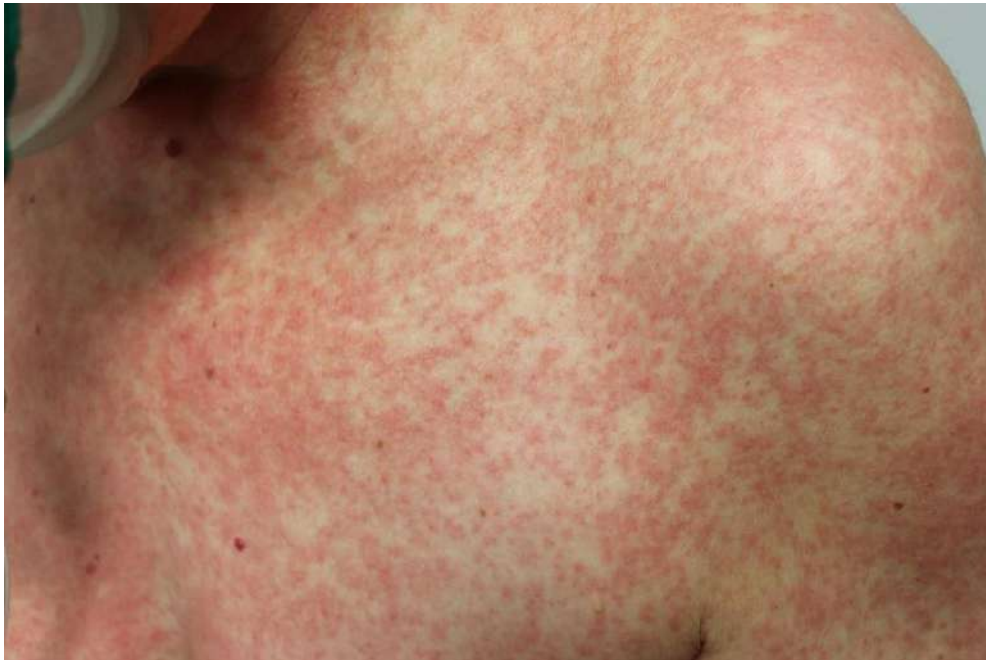
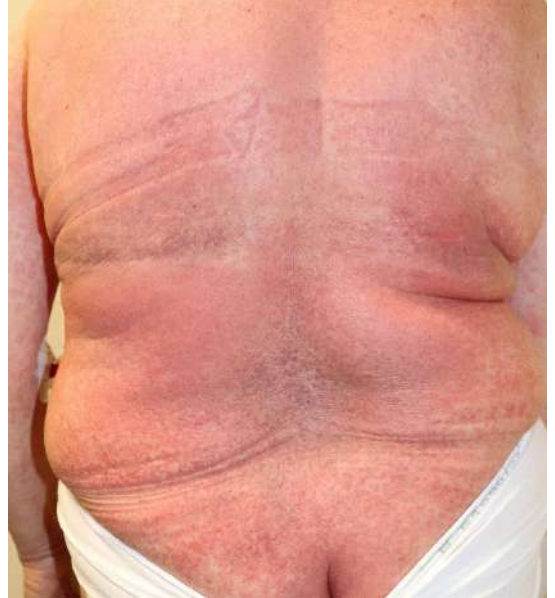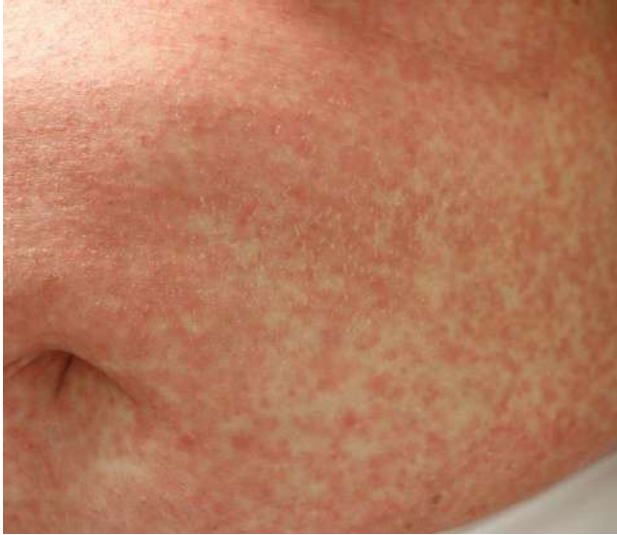## Bilateral axillary purpuric eruption

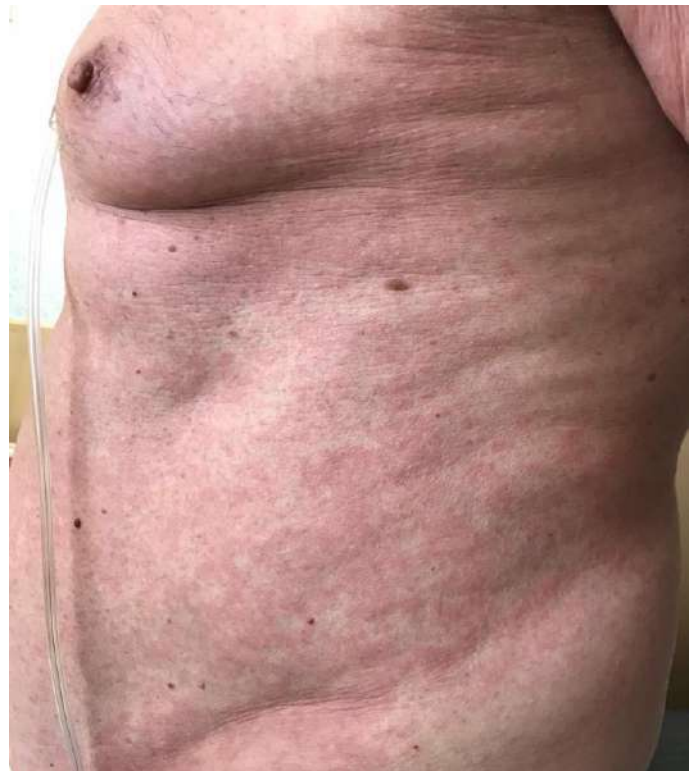
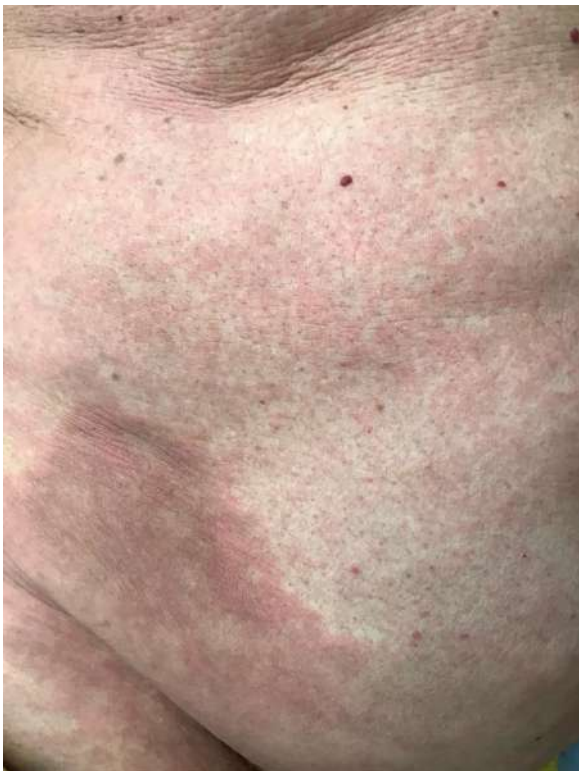
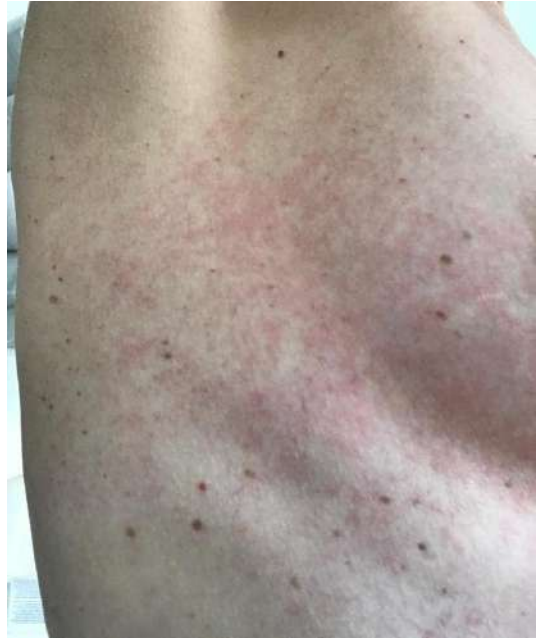
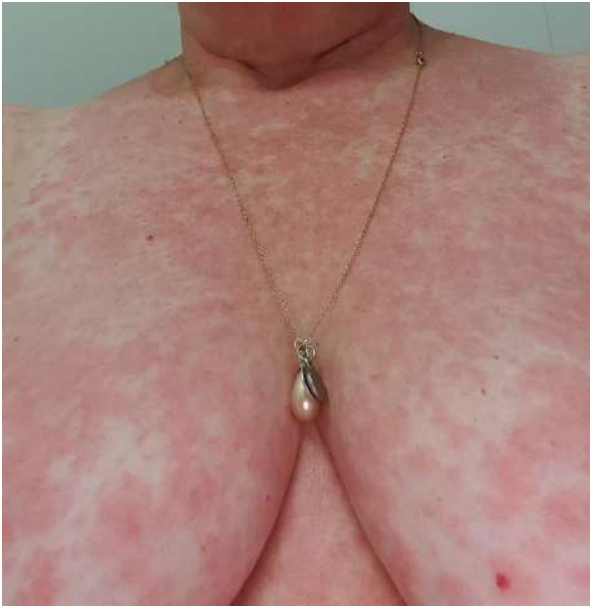
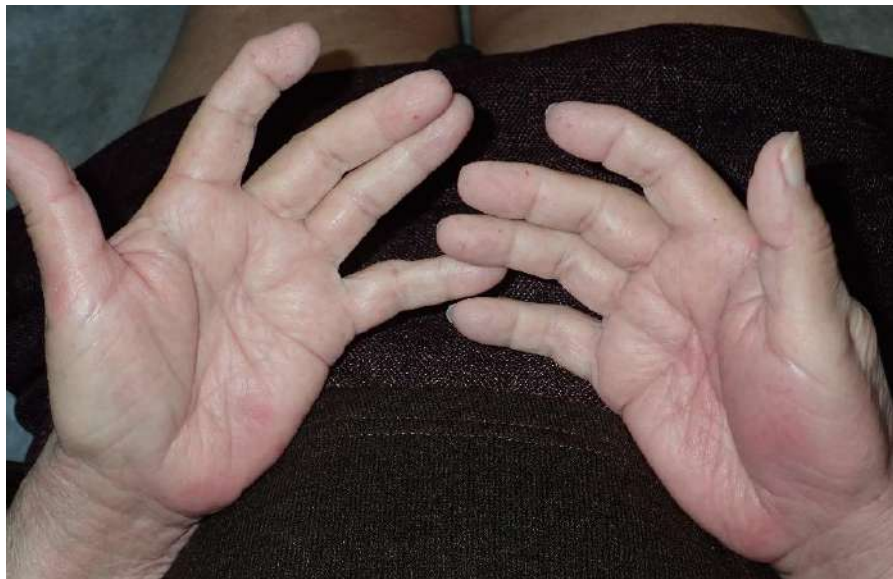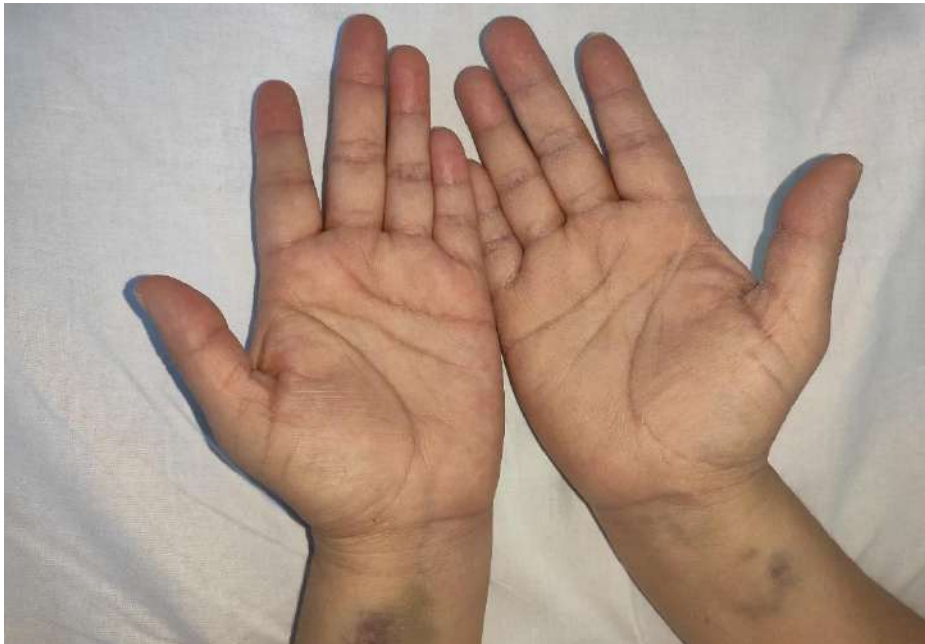## Morbilliform eruptions



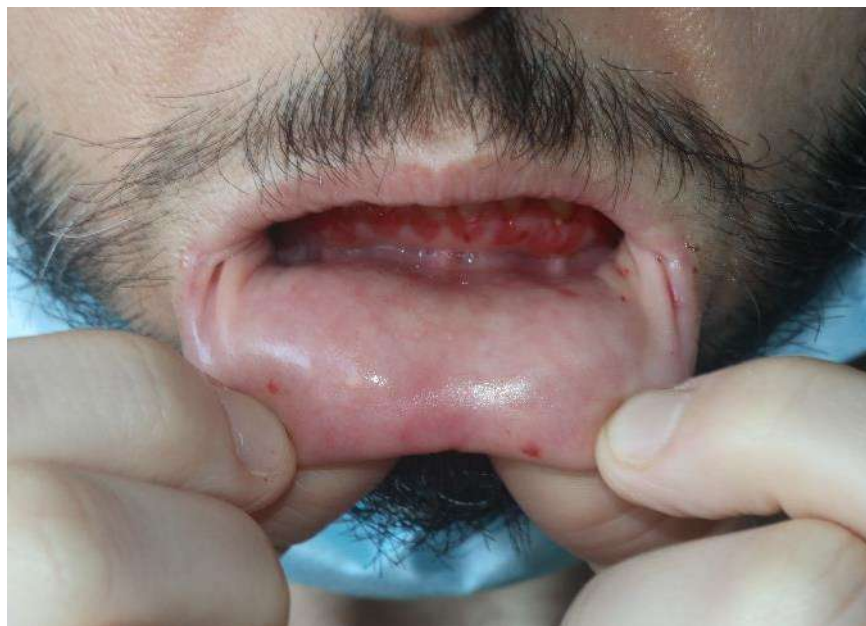
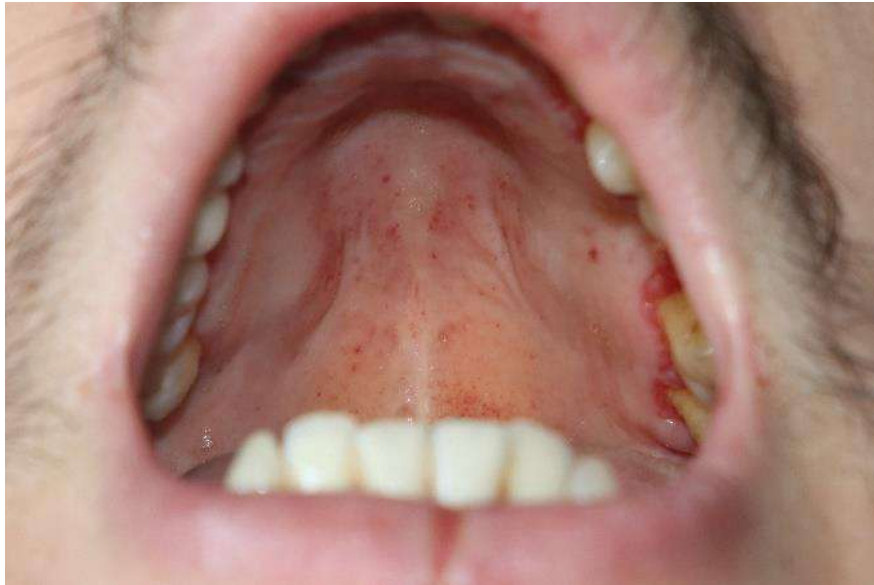


## Palmar erythema



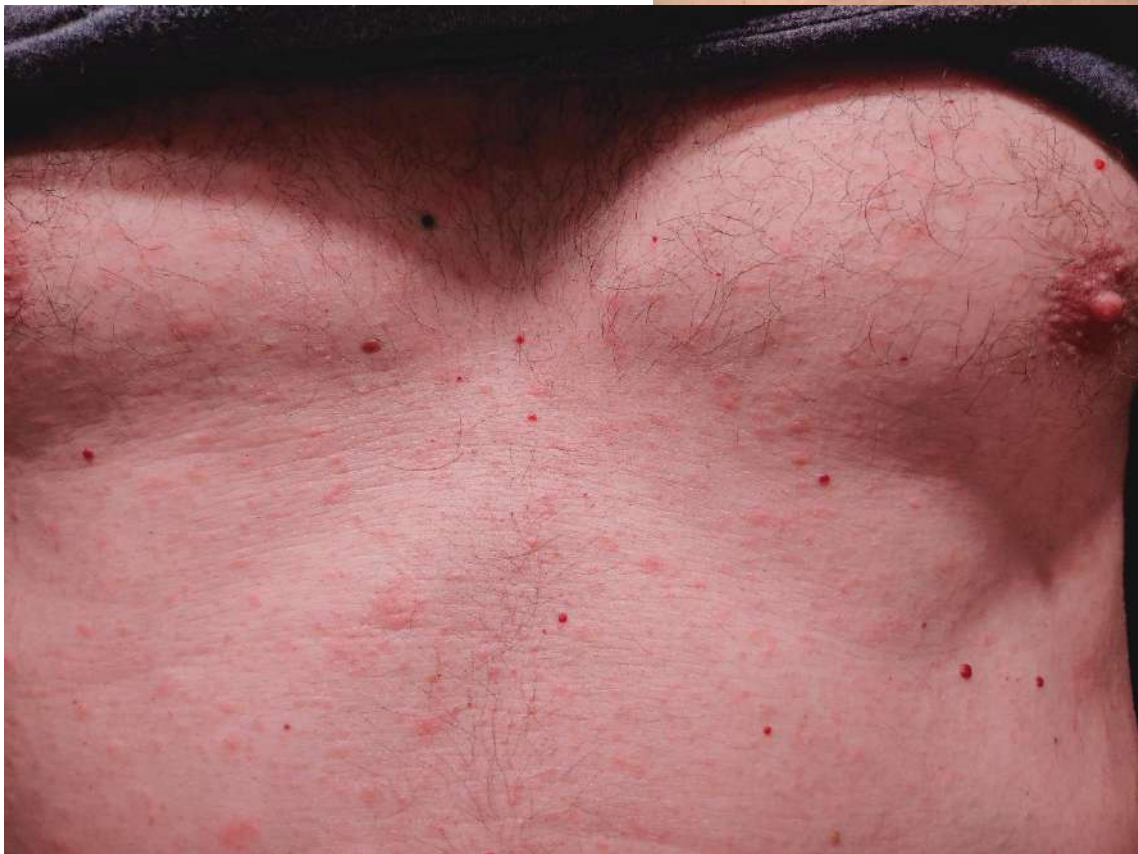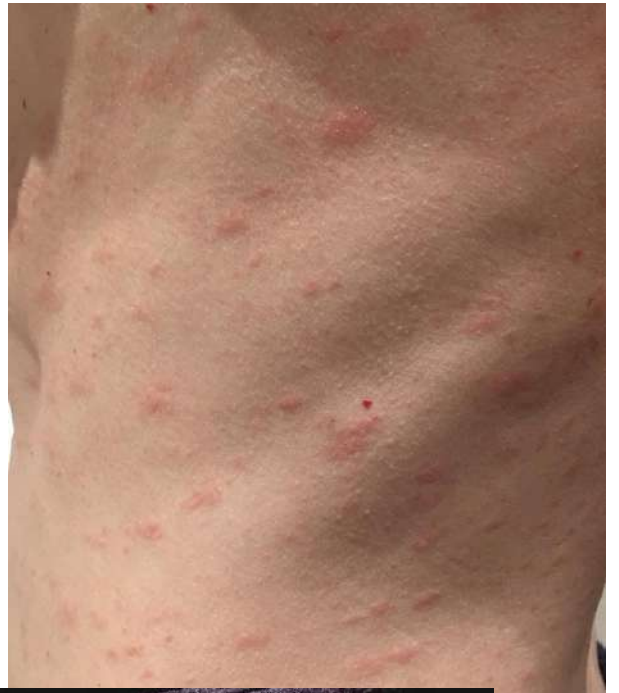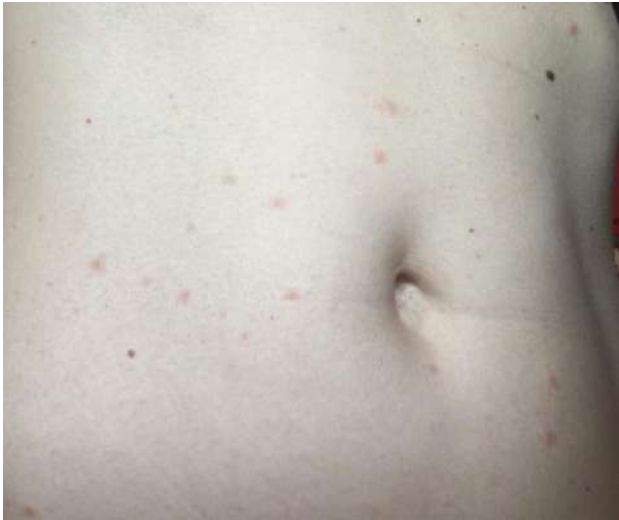## Enanthem

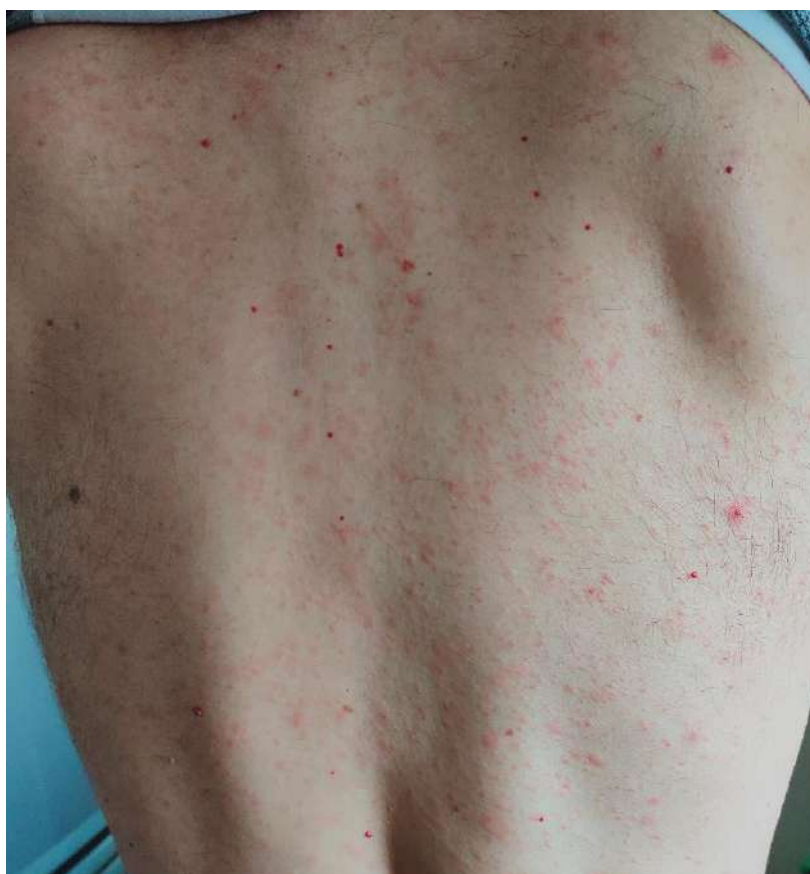
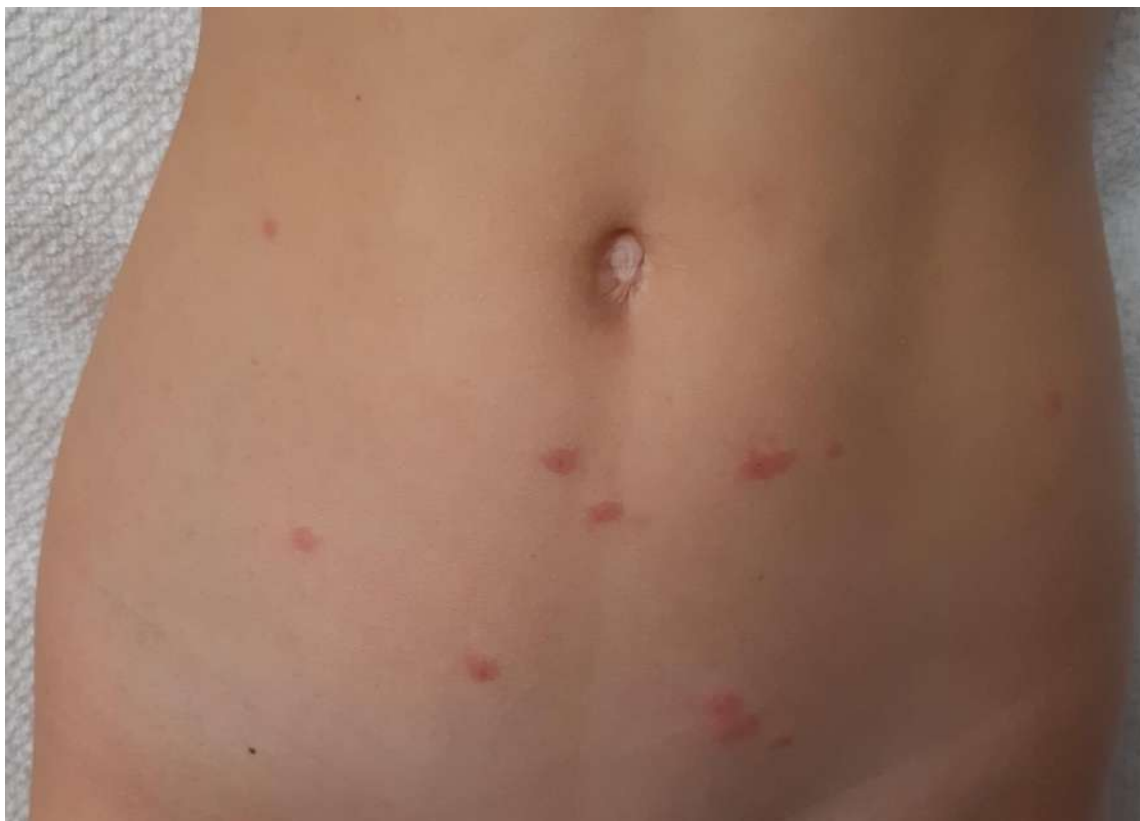


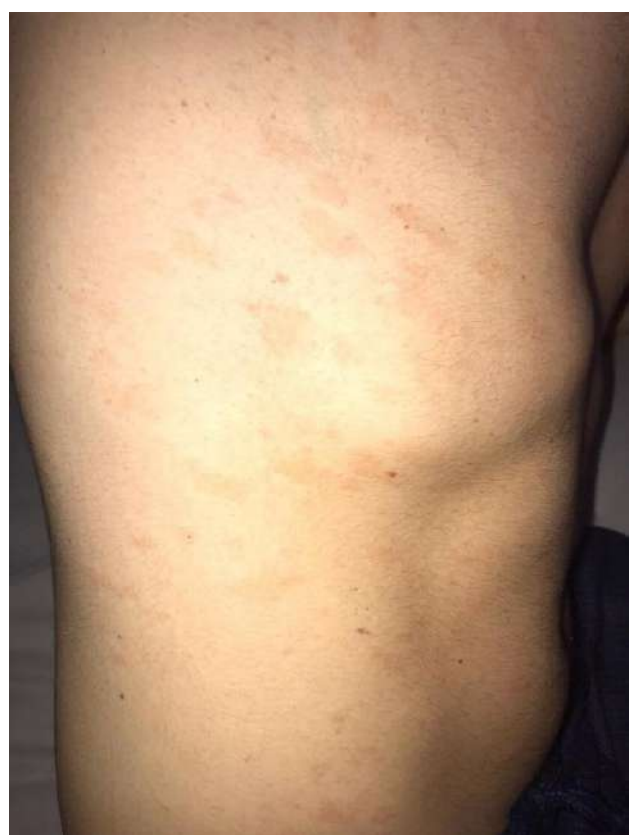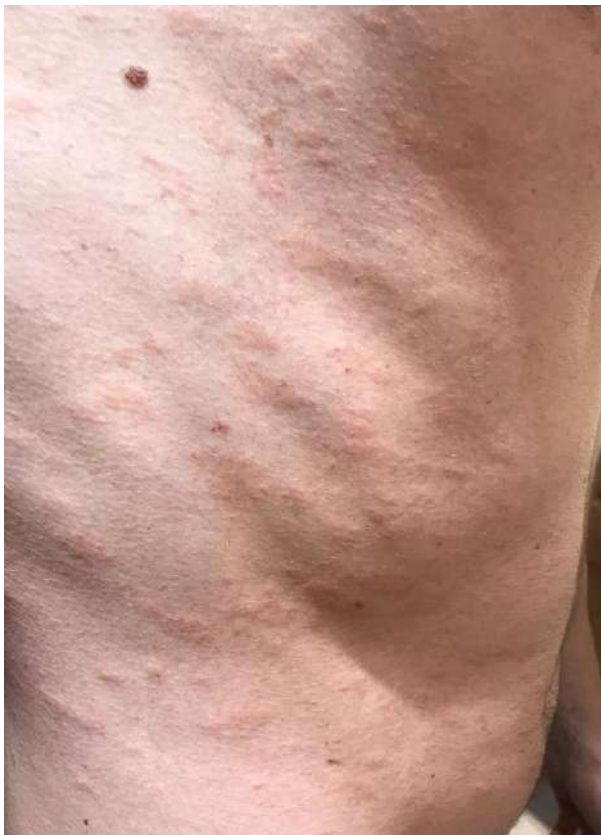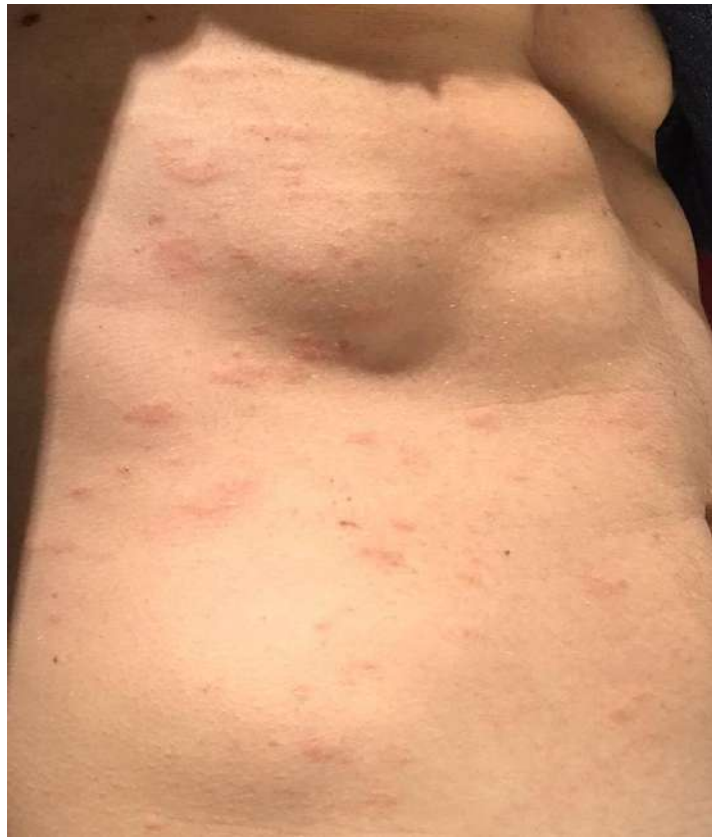## Maculopapular eruption – Suspected cases

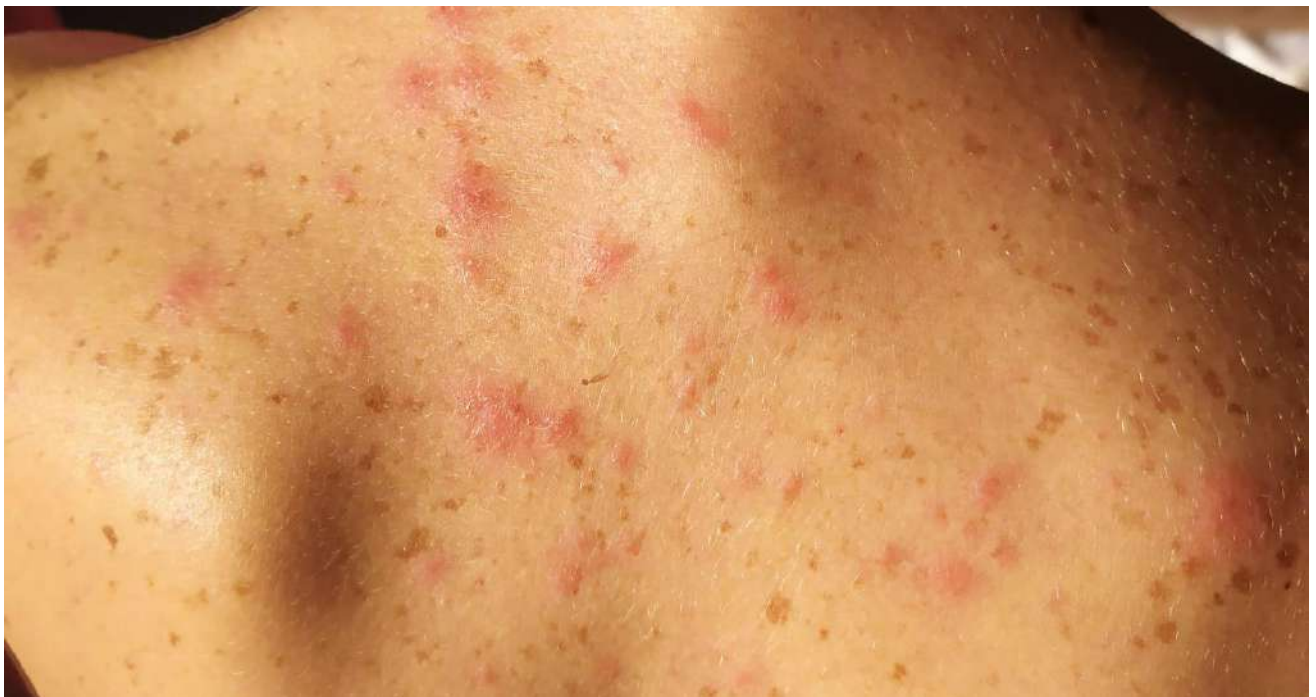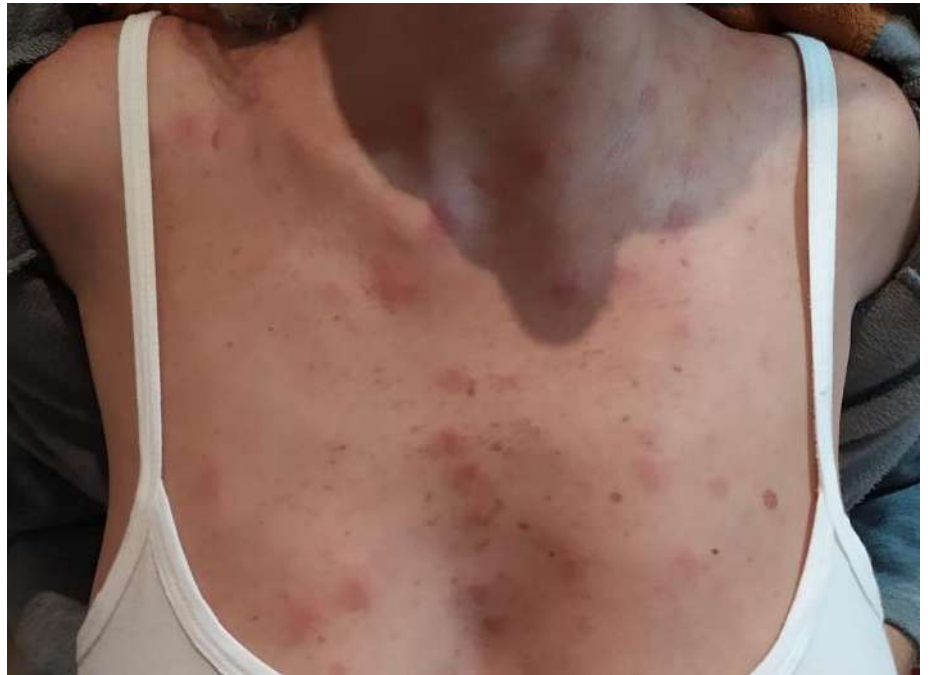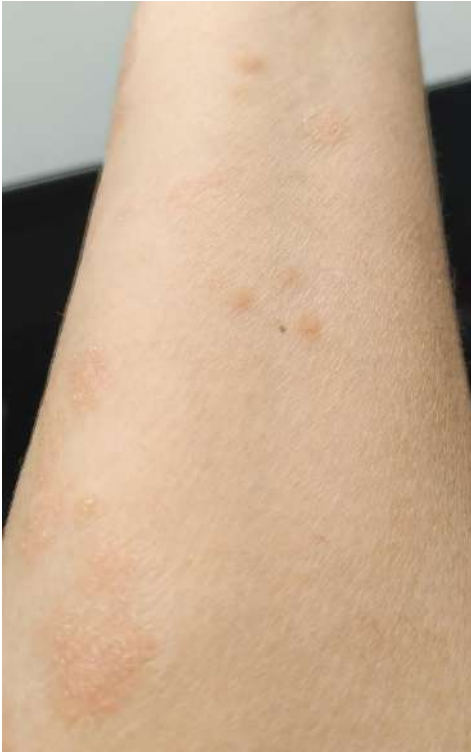Pytirisias rosea-like



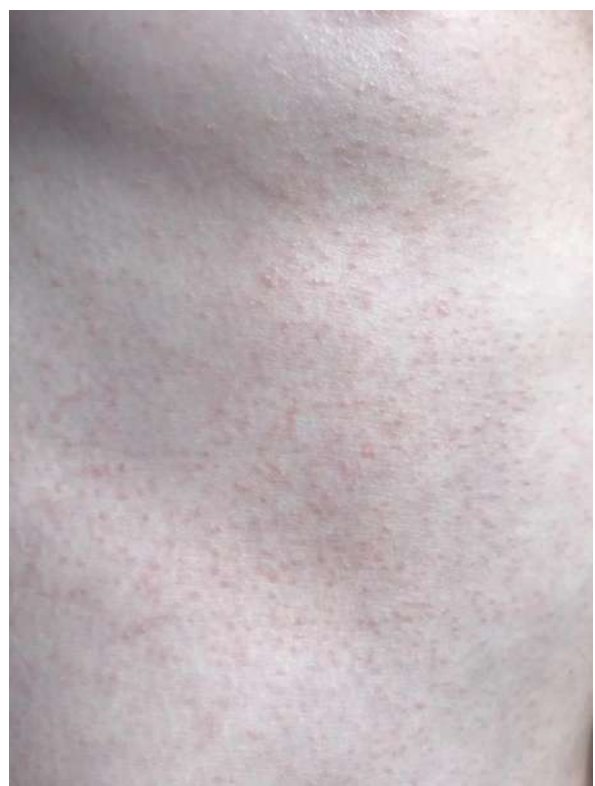
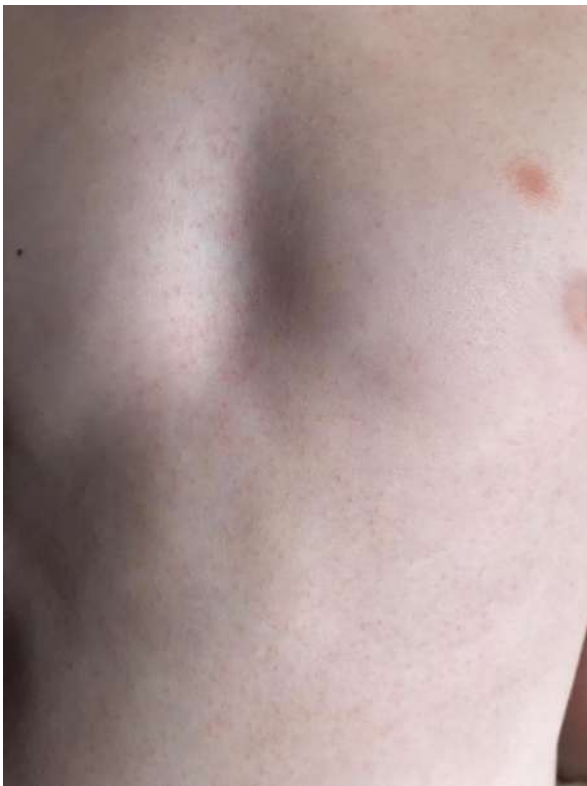
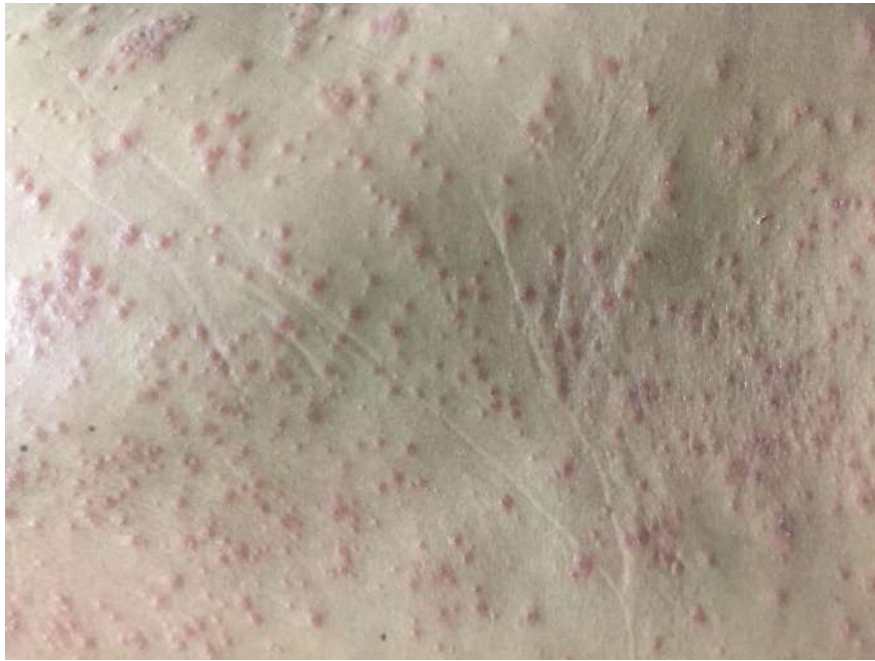


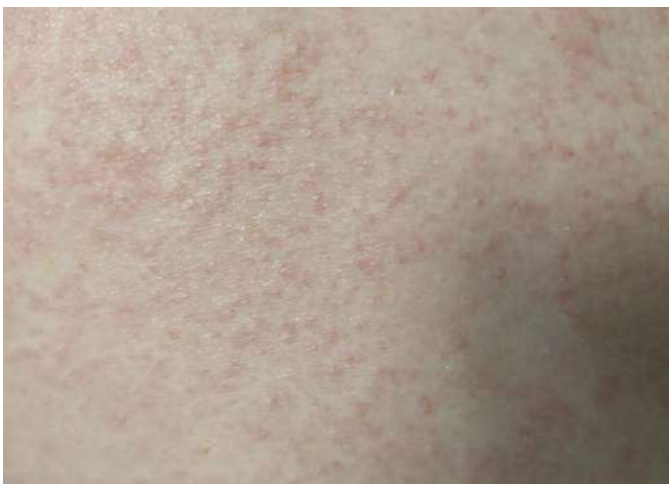
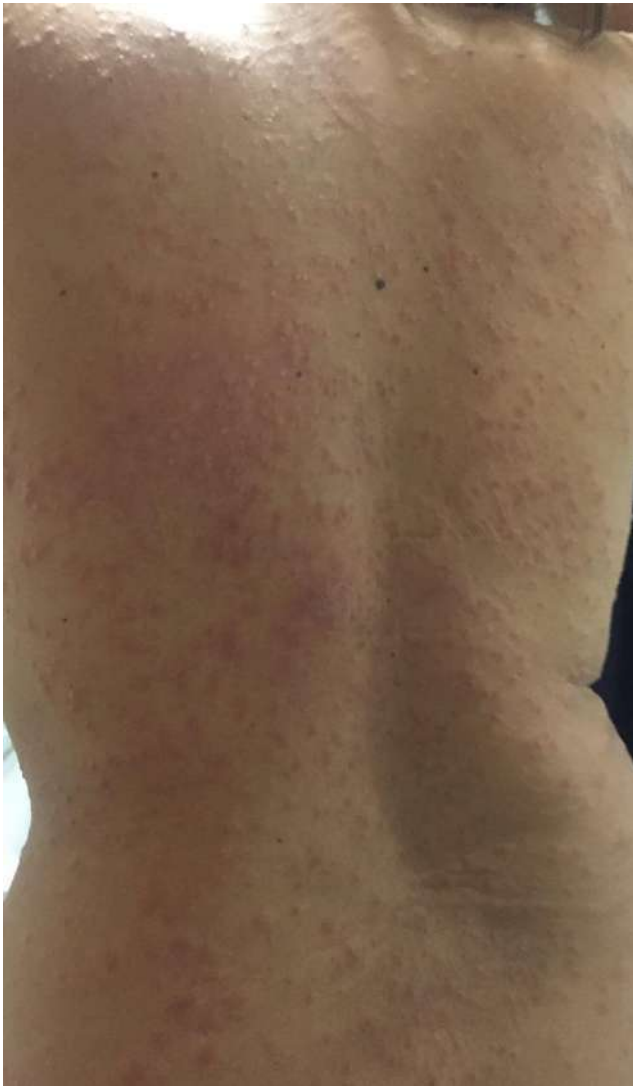

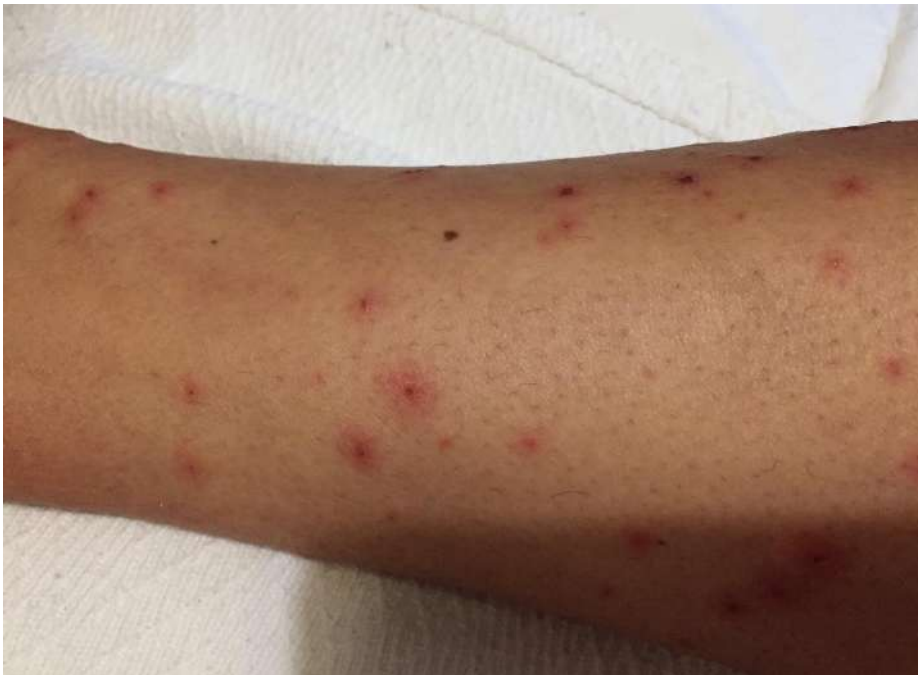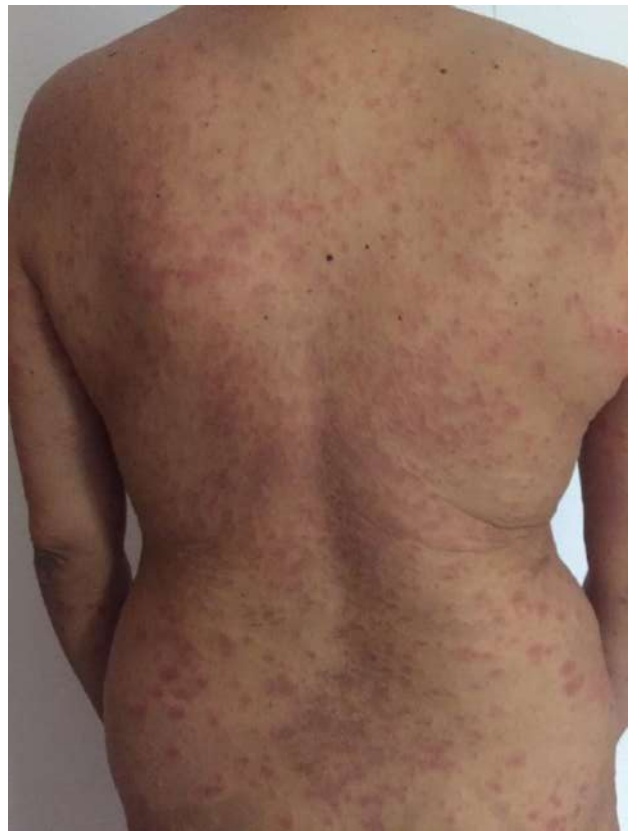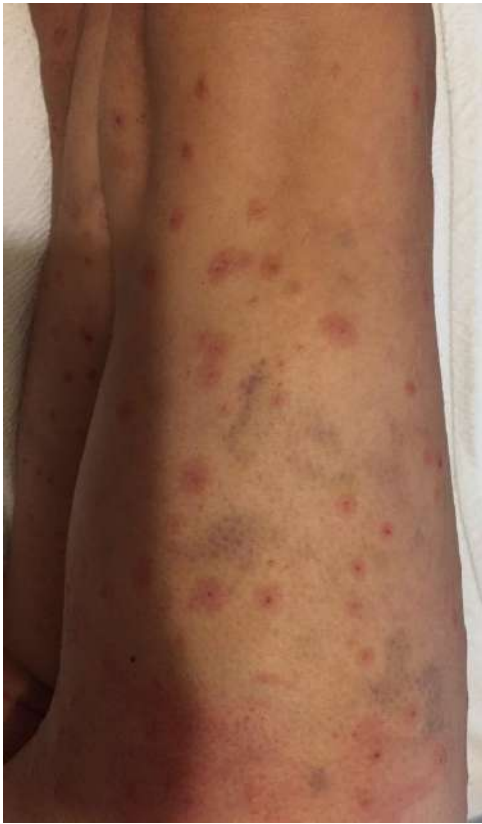## Perifollicular eruption

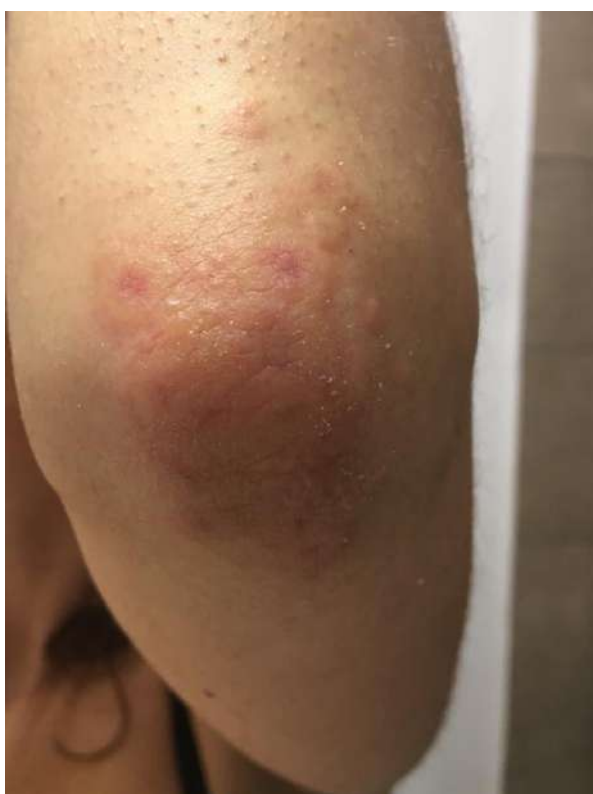
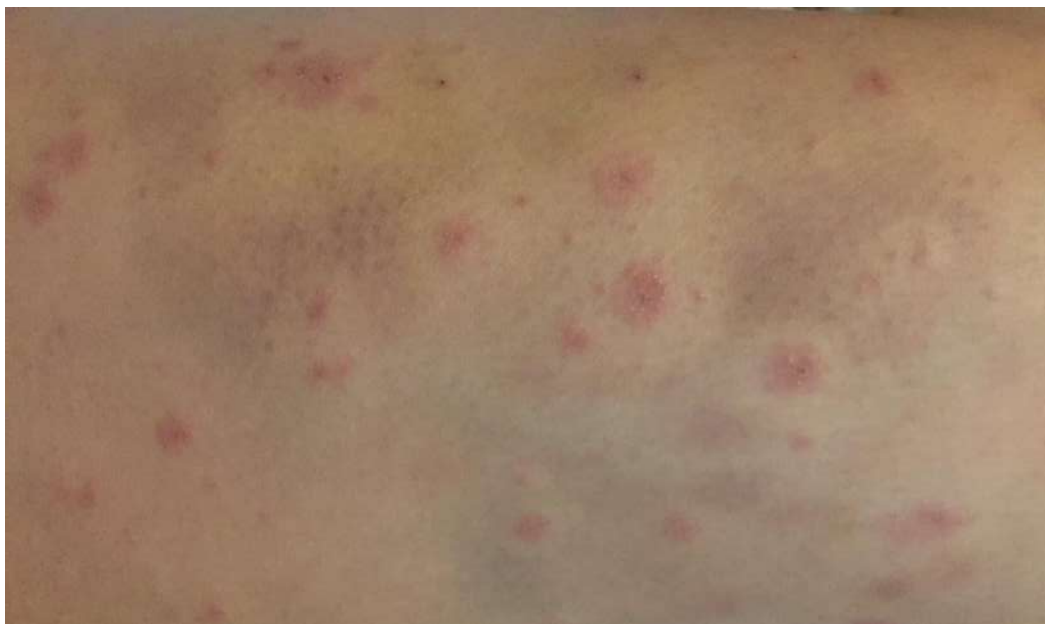


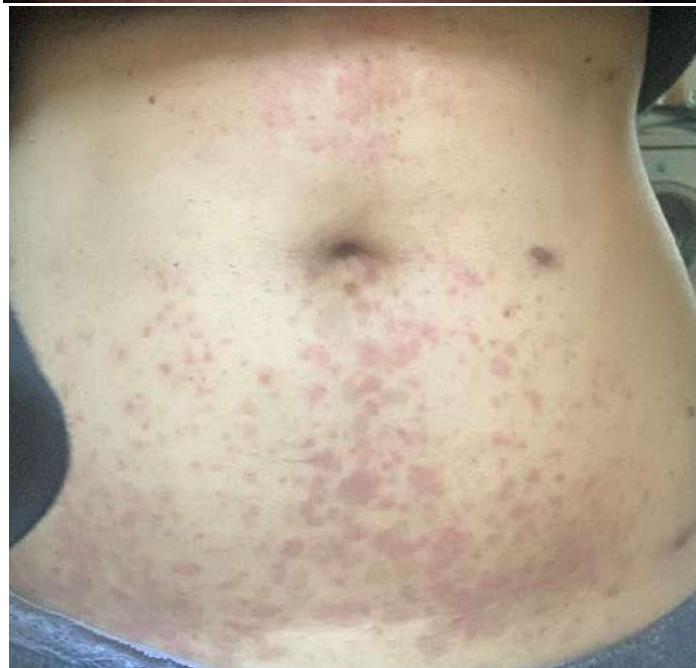
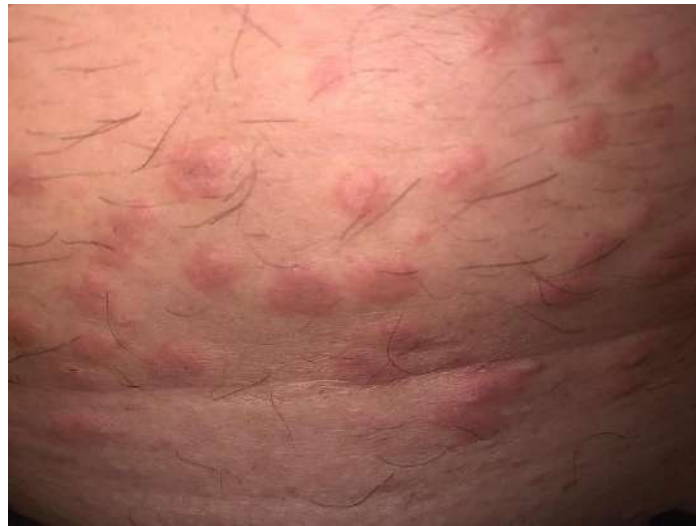
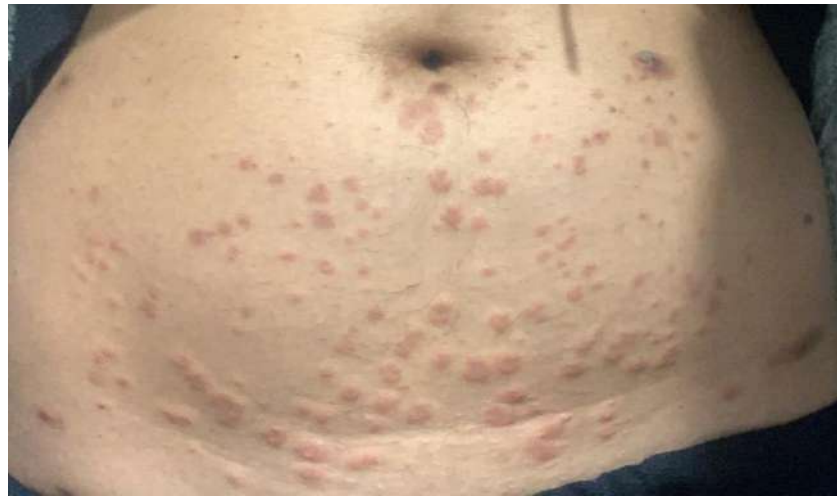Erythema multiforme-like

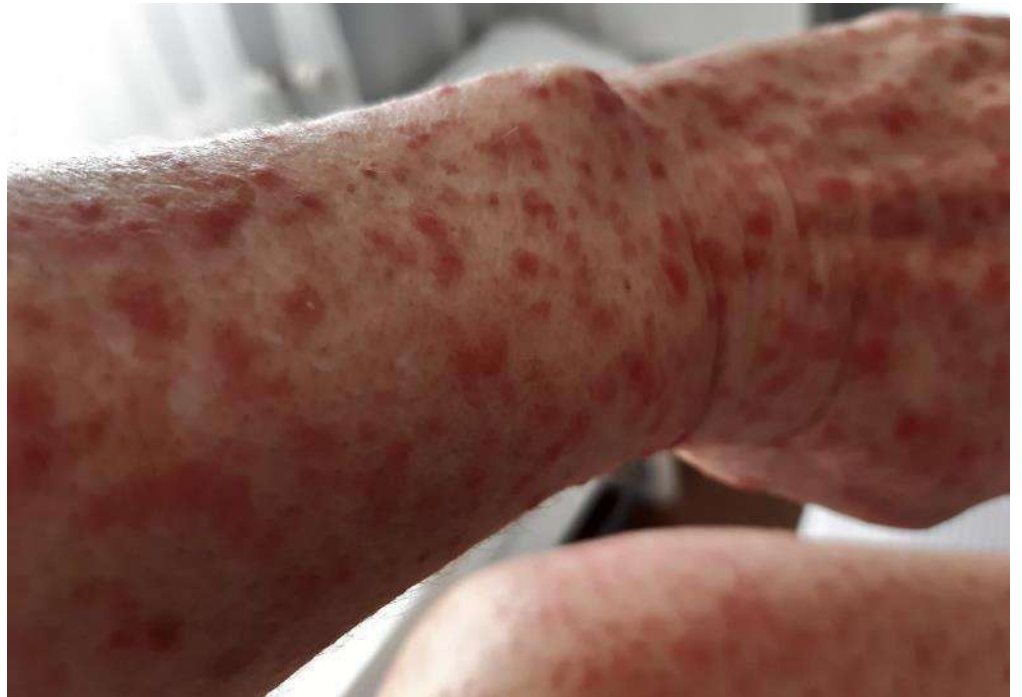
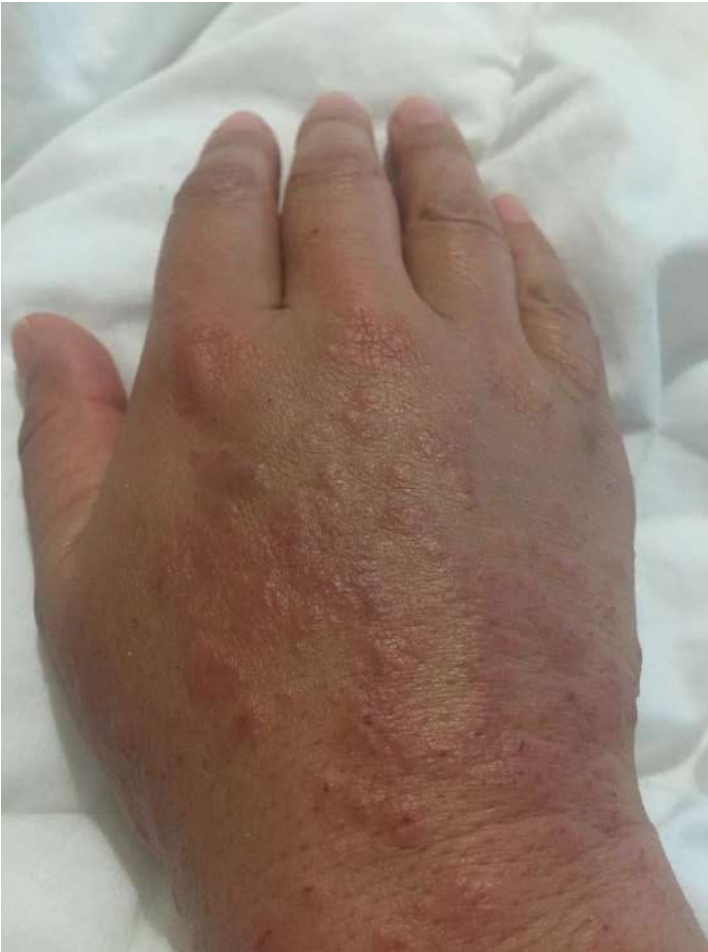


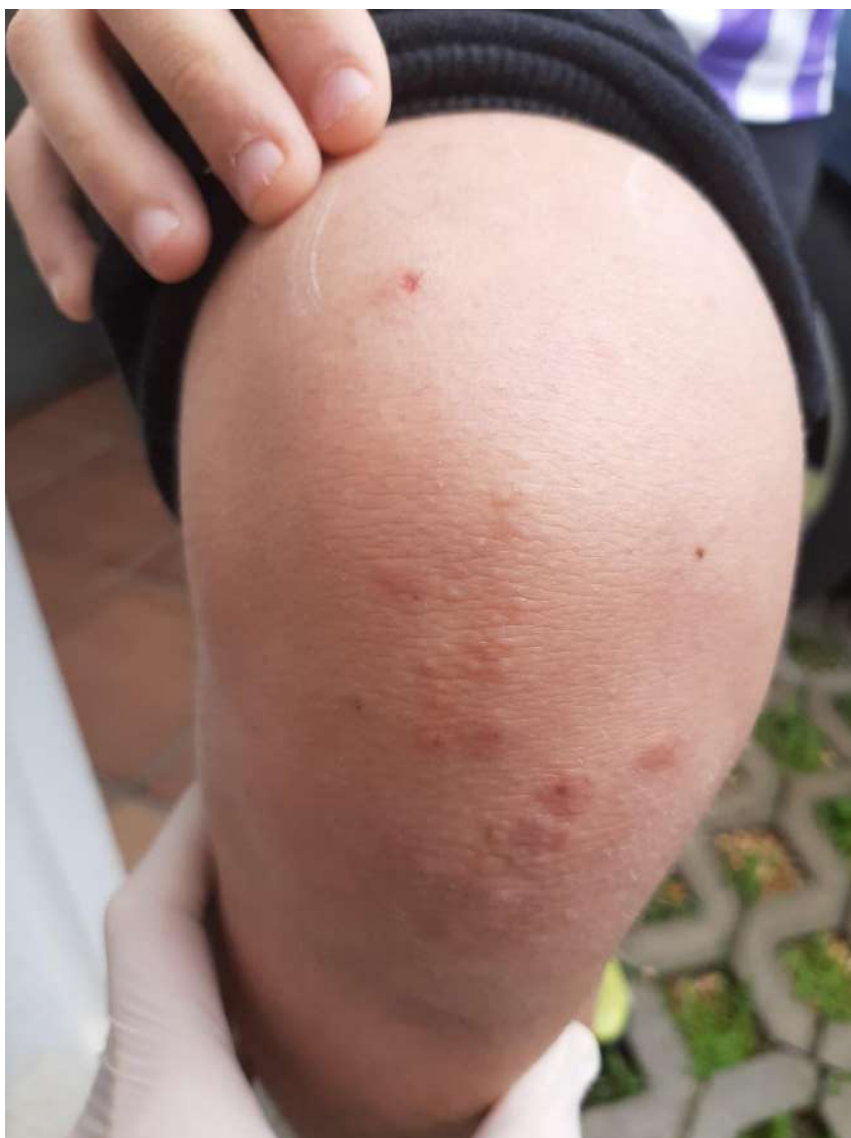


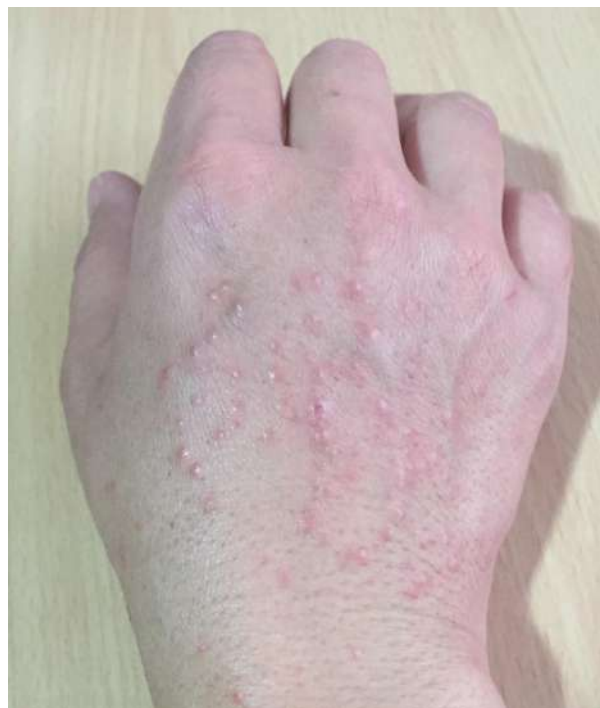
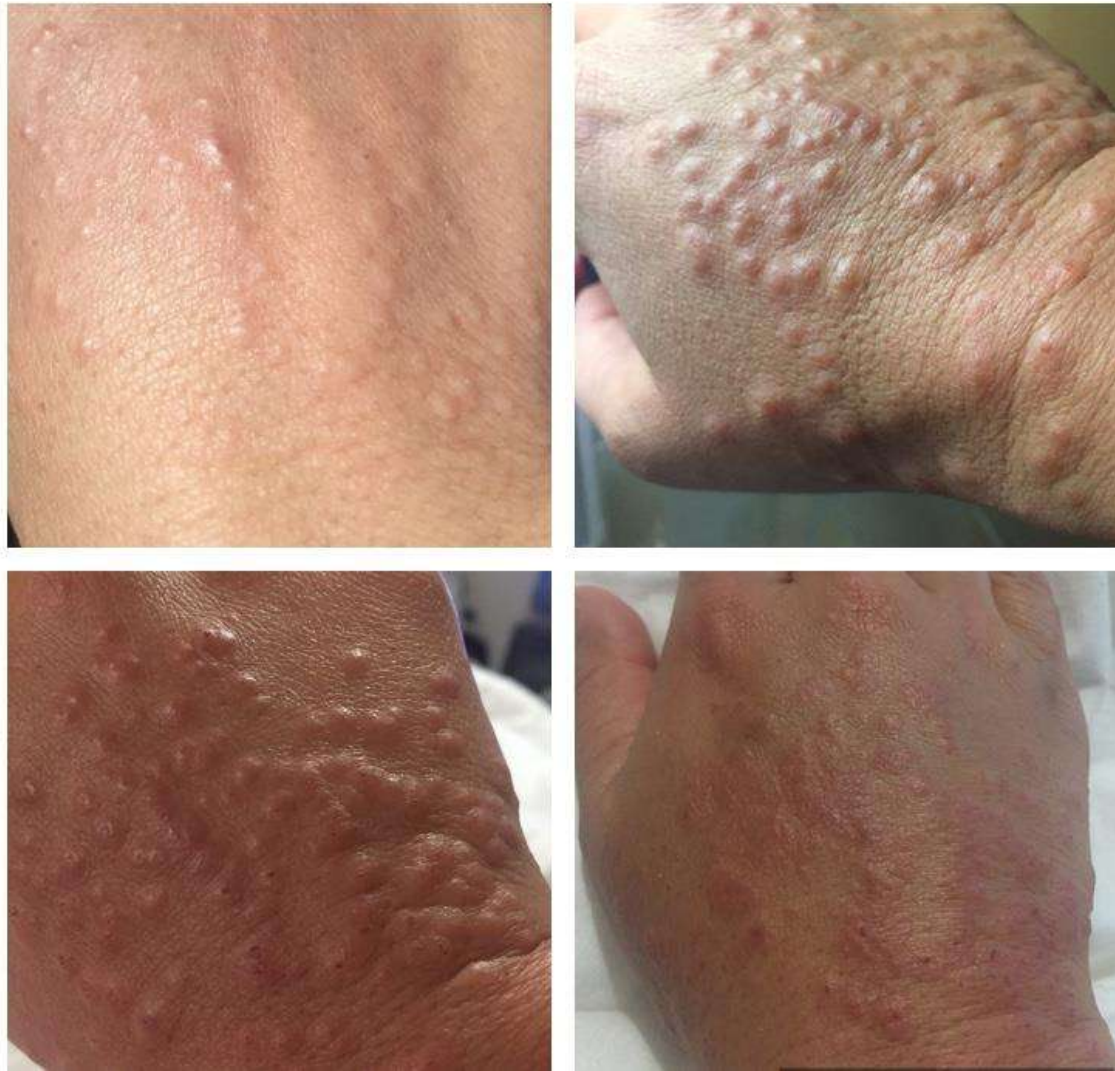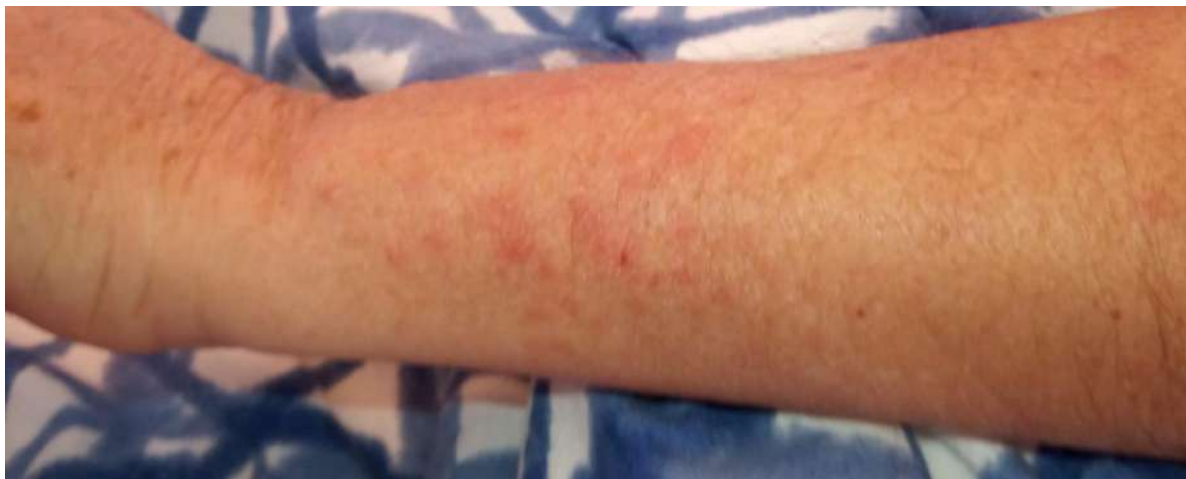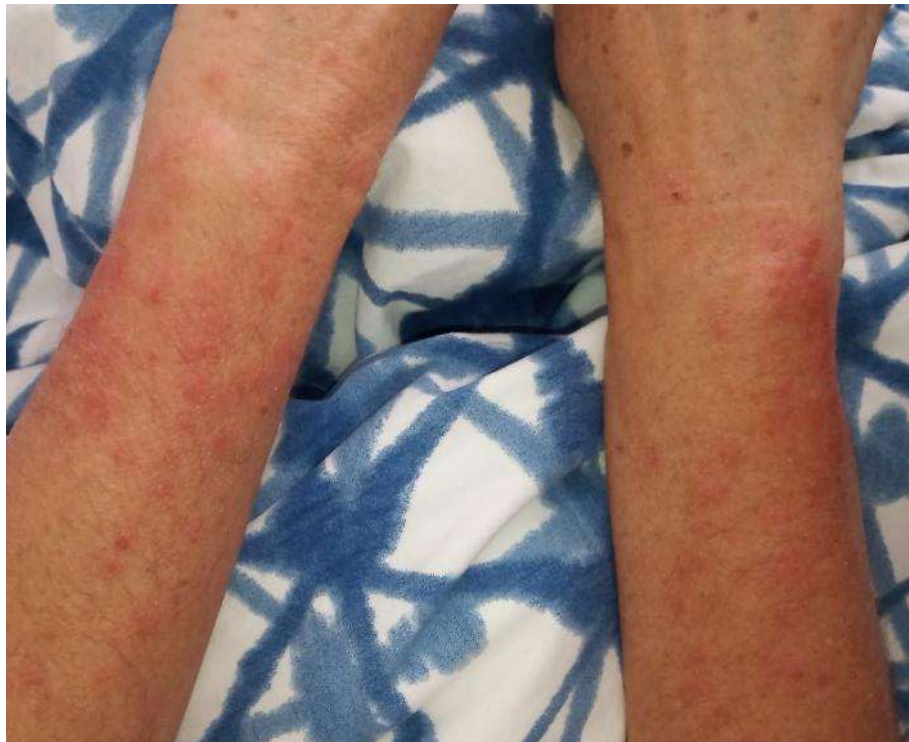Pseudovesicular or resembling erythema elevatum diutinum

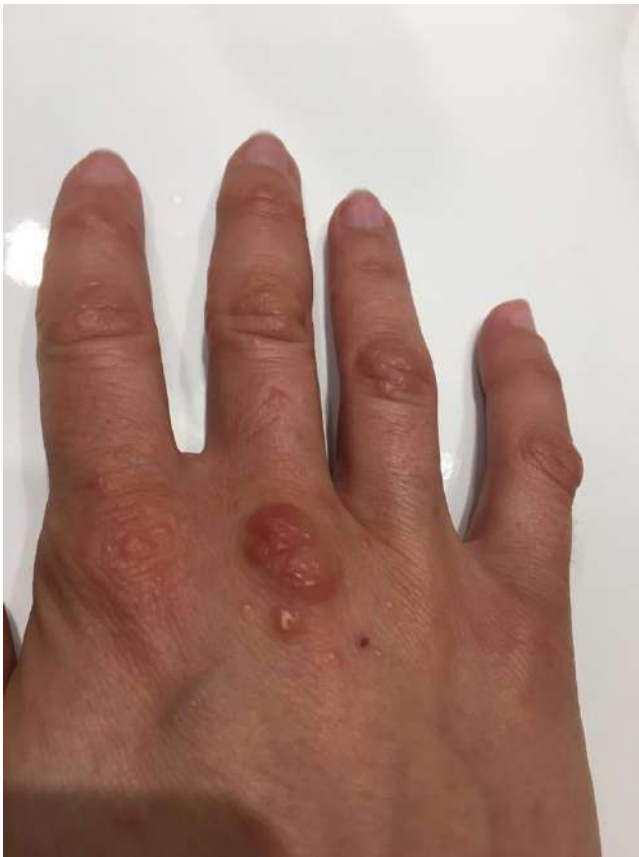
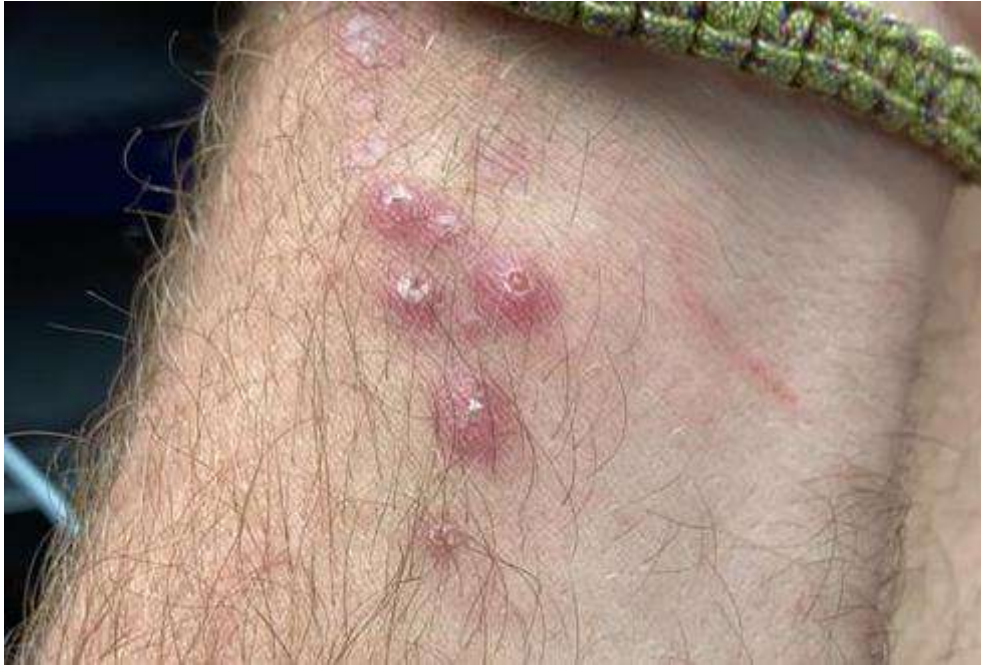


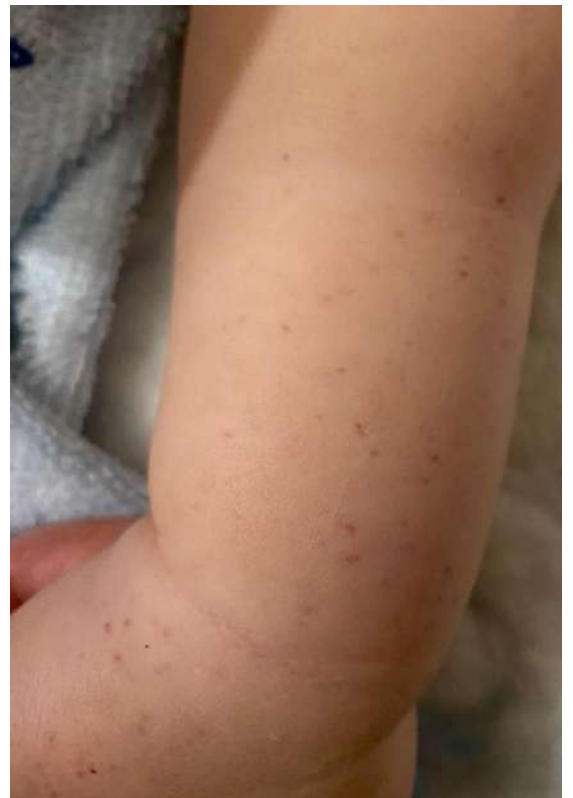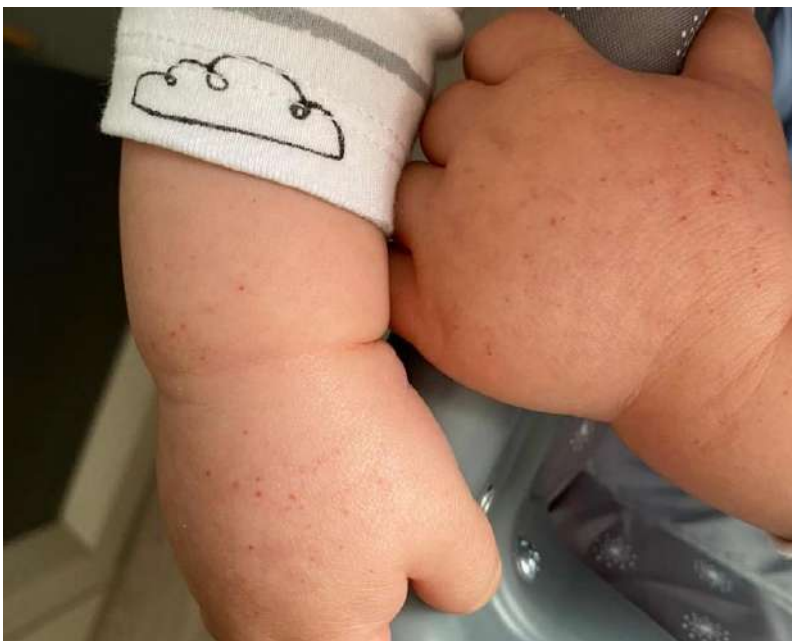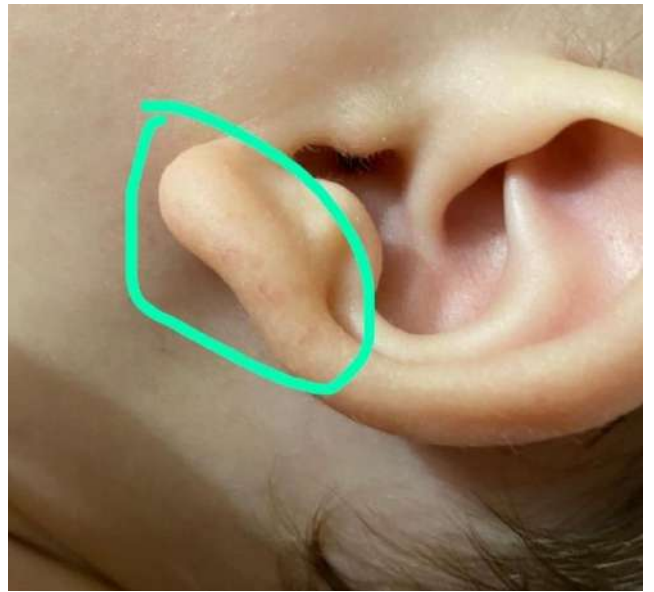




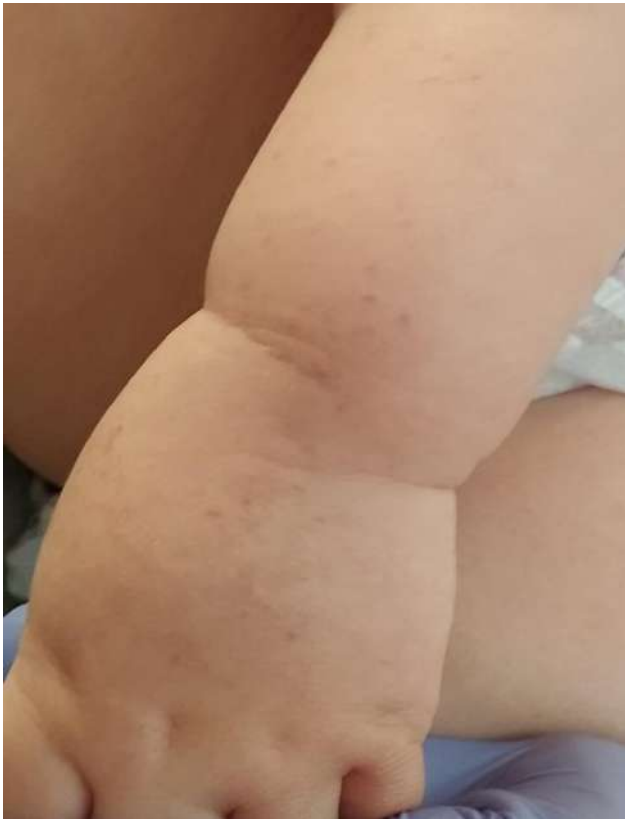



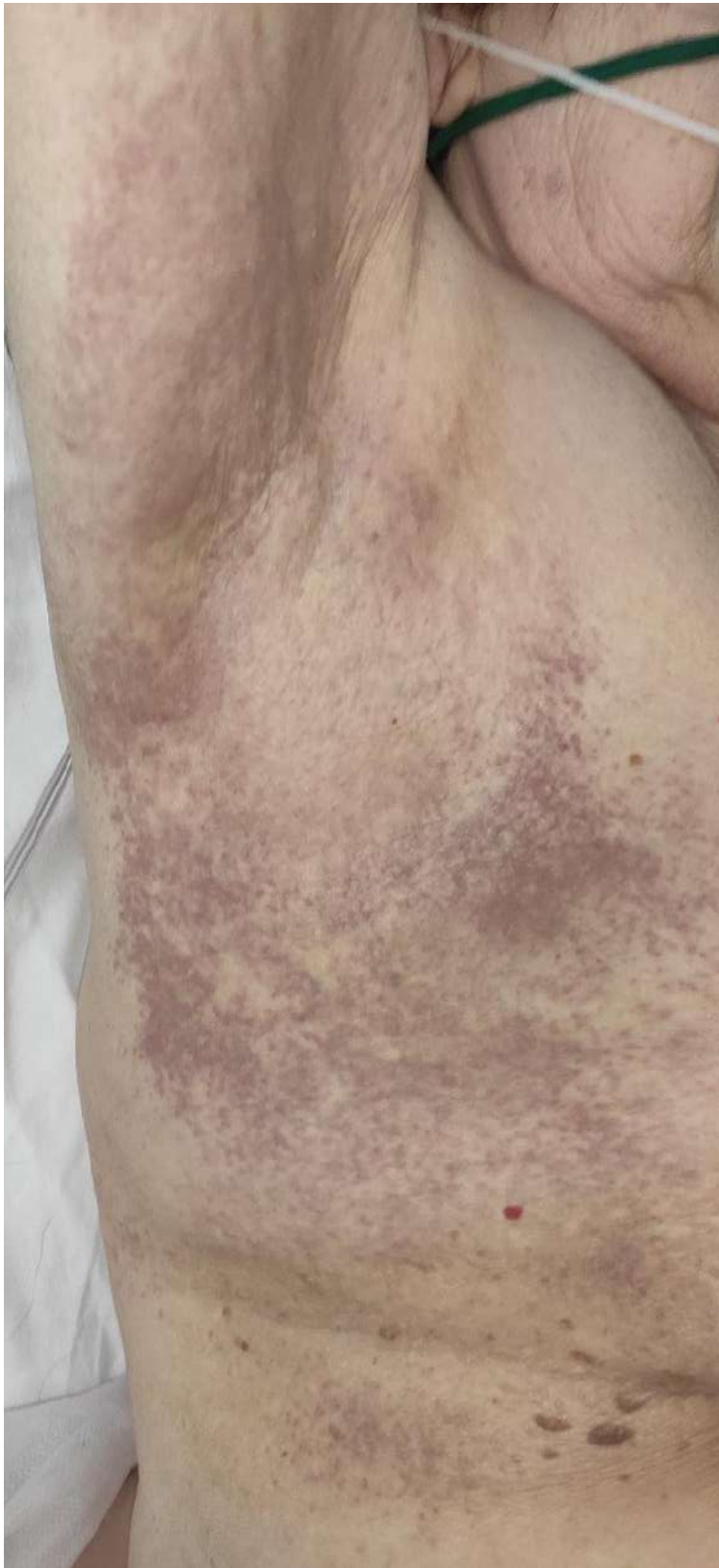Purpuric eruption

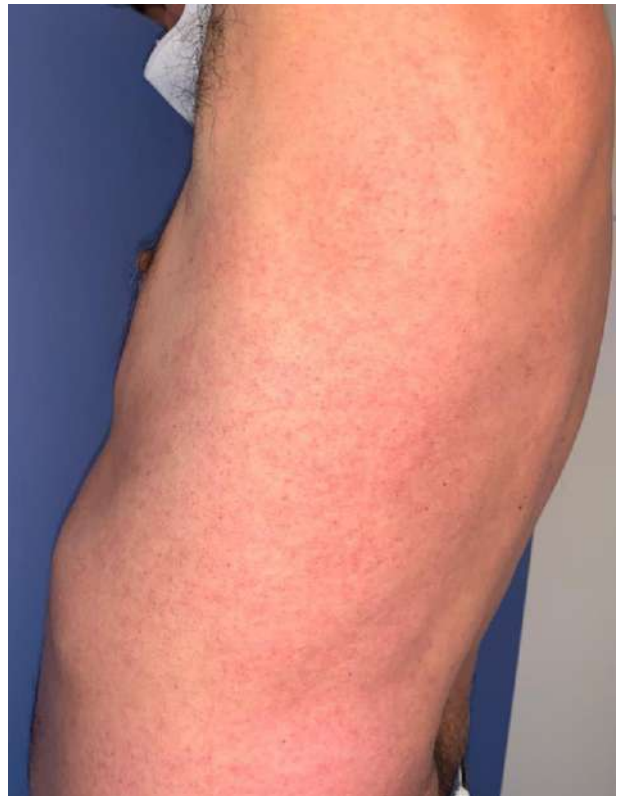
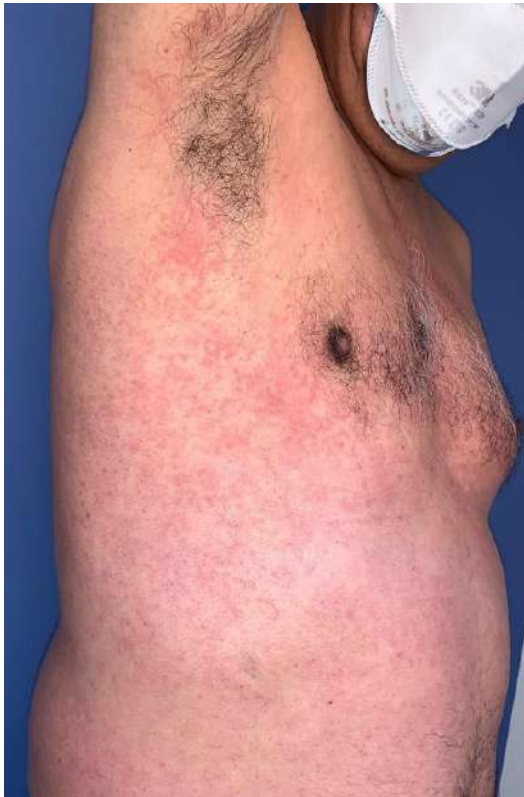
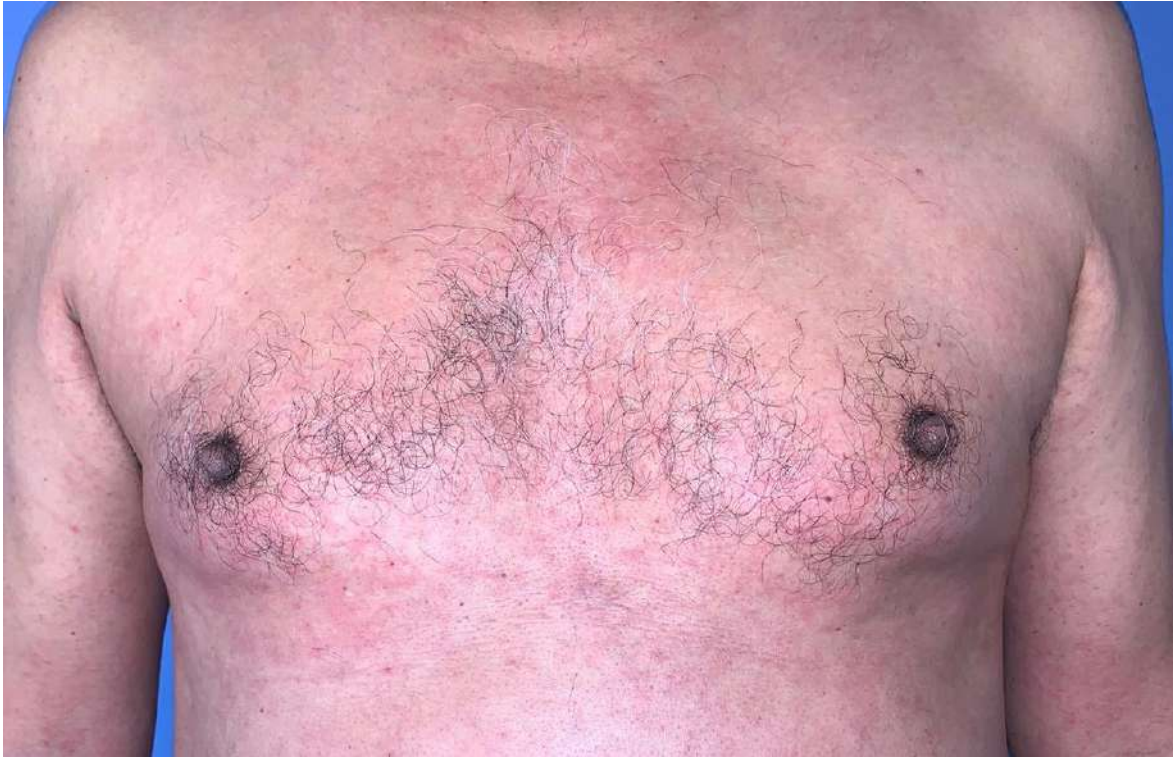

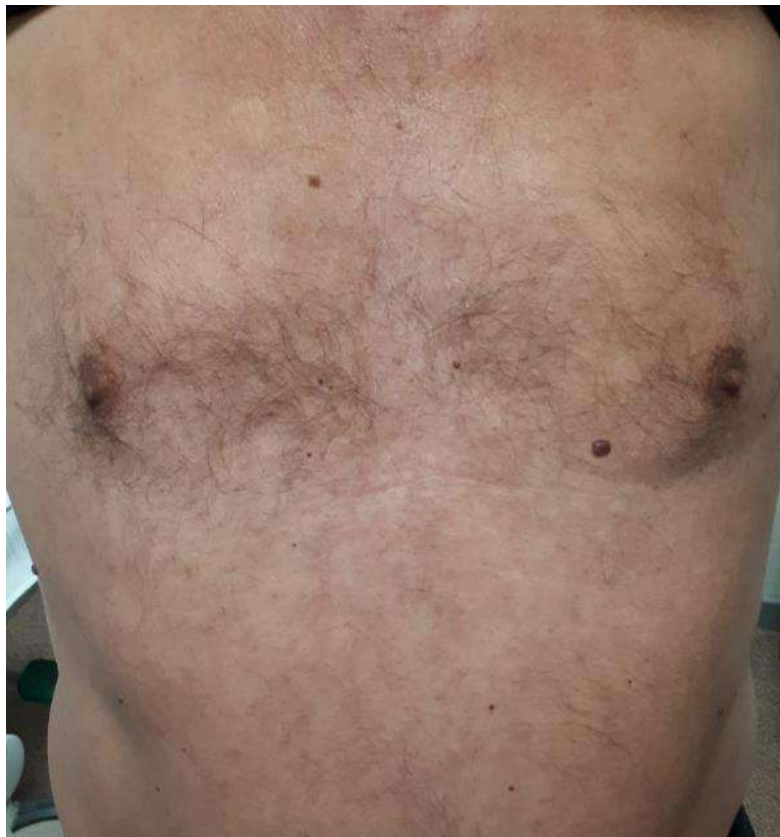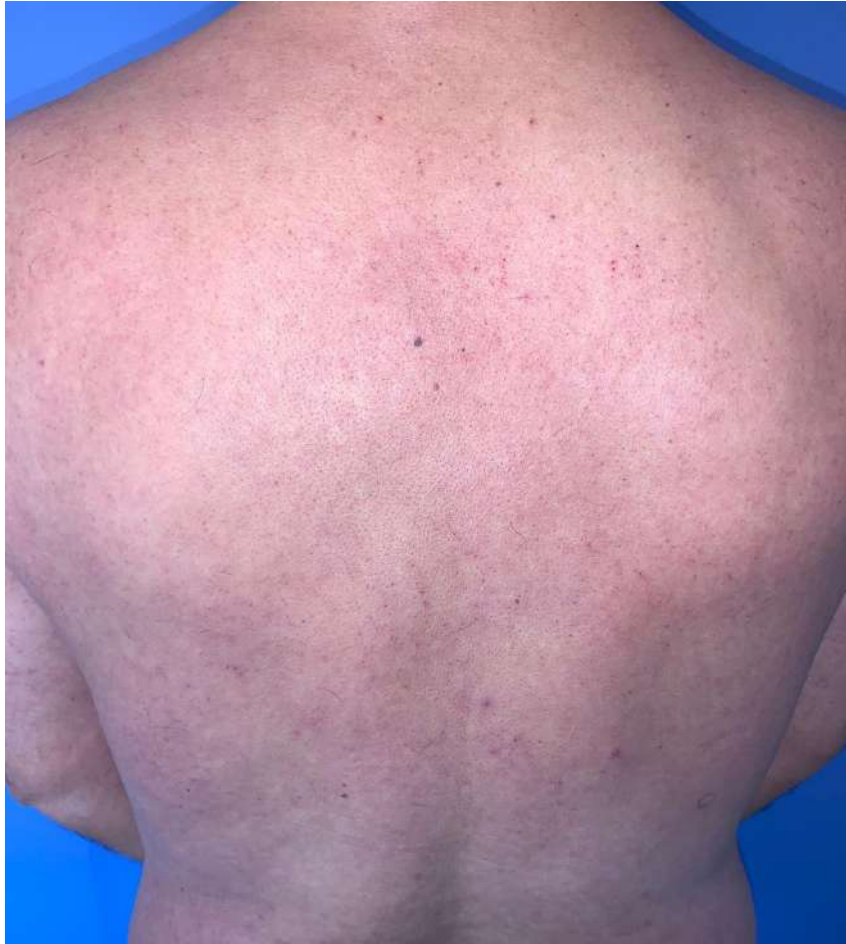## Bilateral axillary purpuric eruption



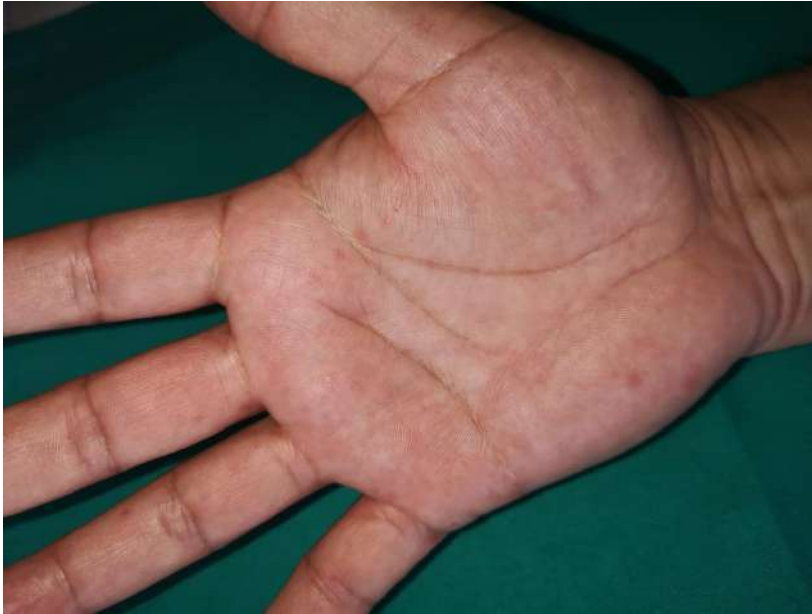## Morbilliform eruptions



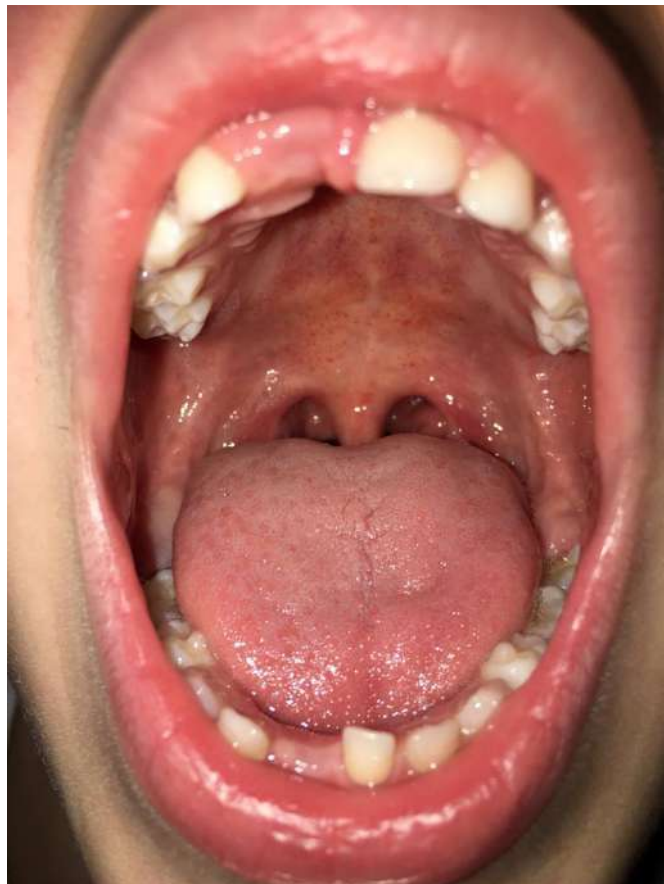
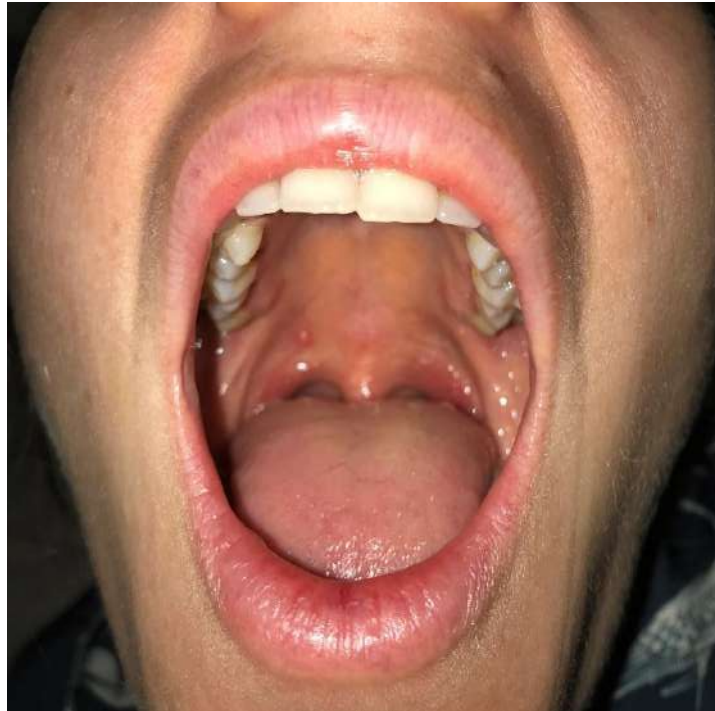


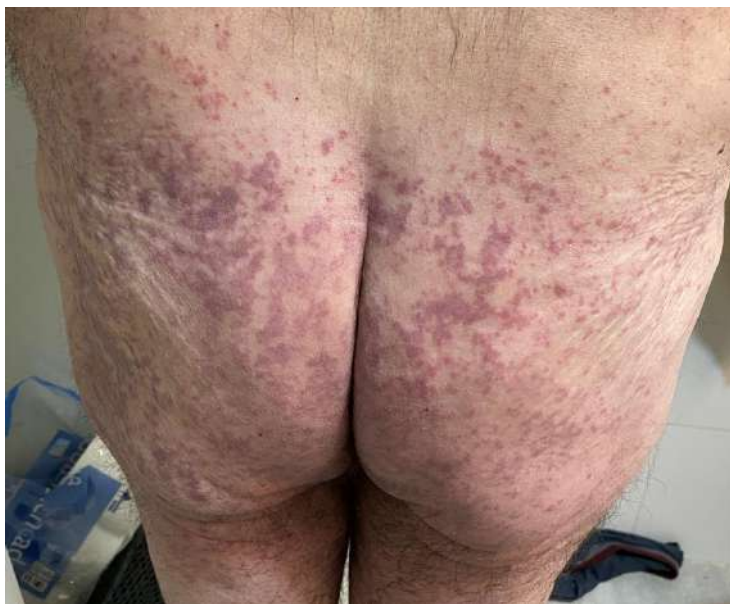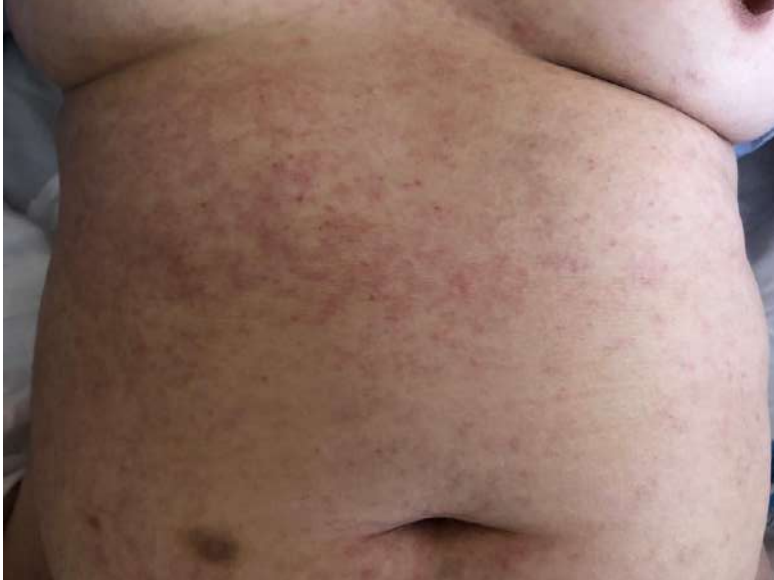## Palmar erythema



## Enanthem

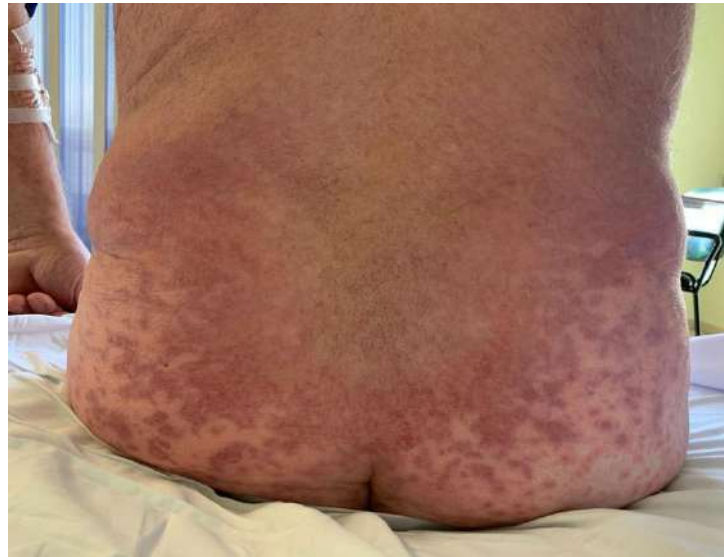
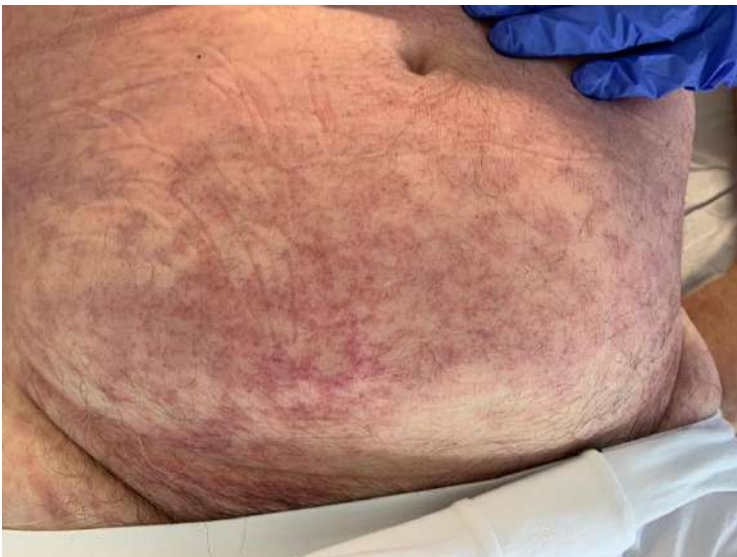
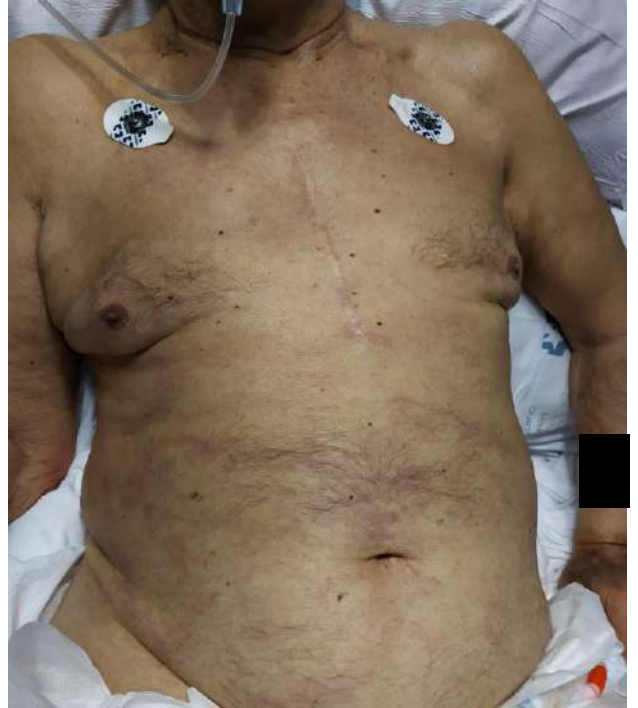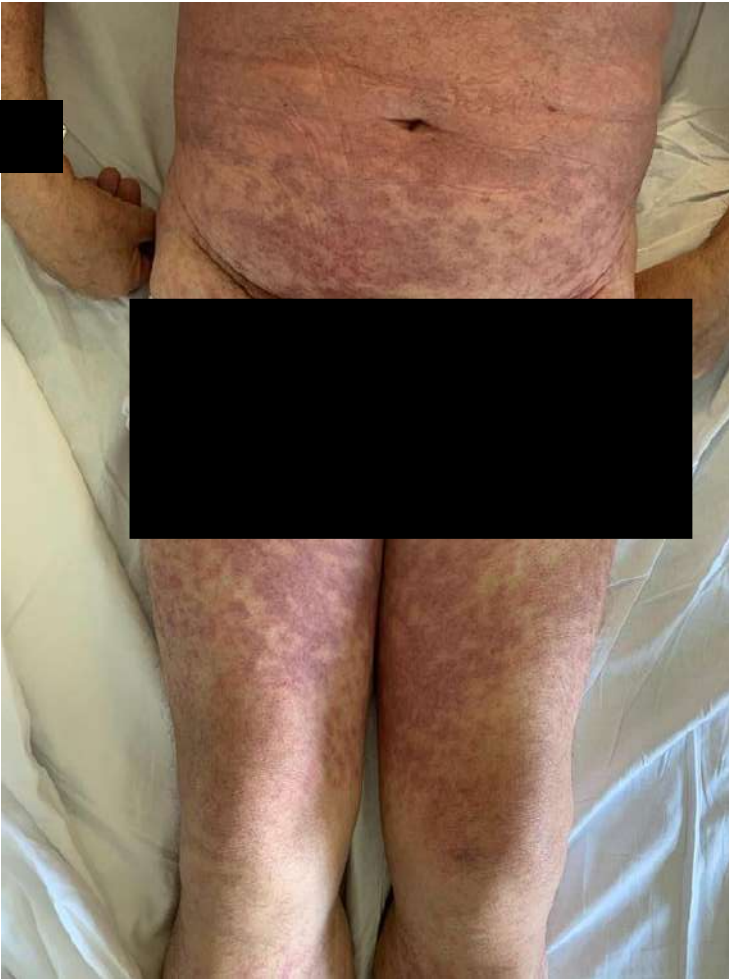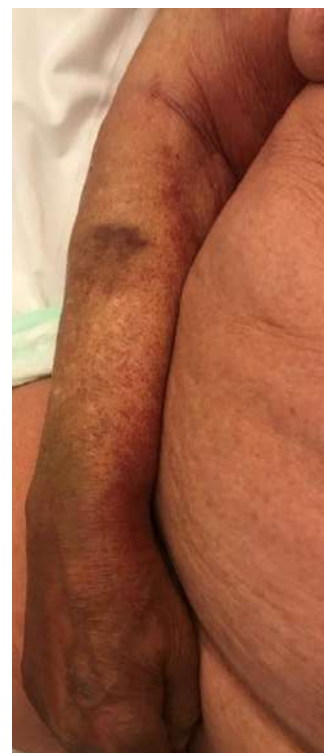
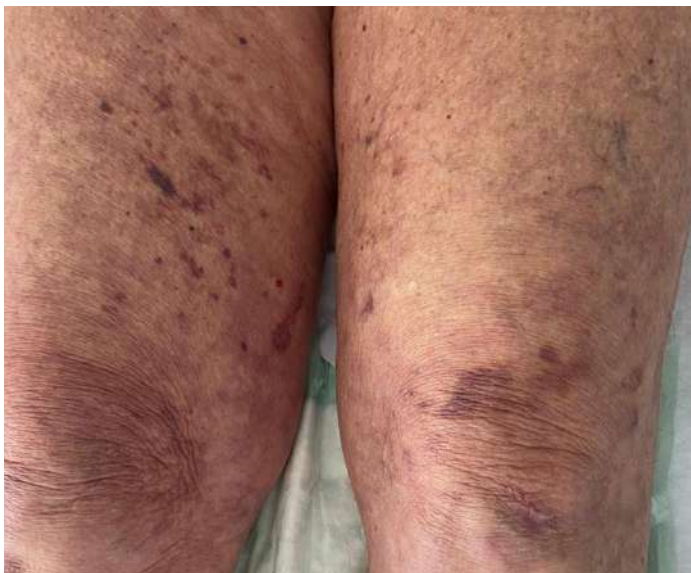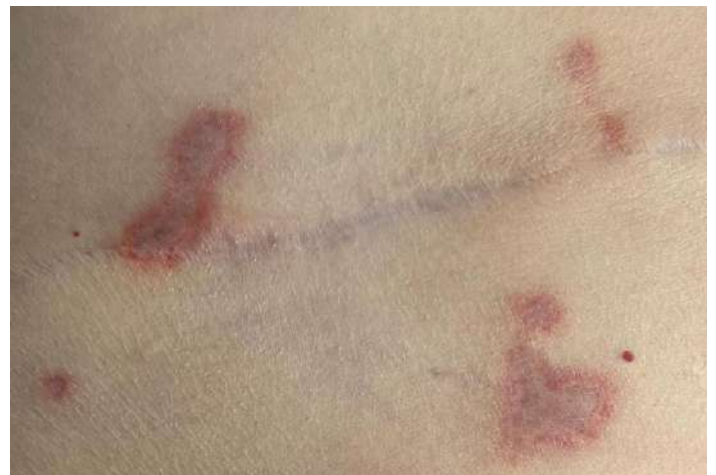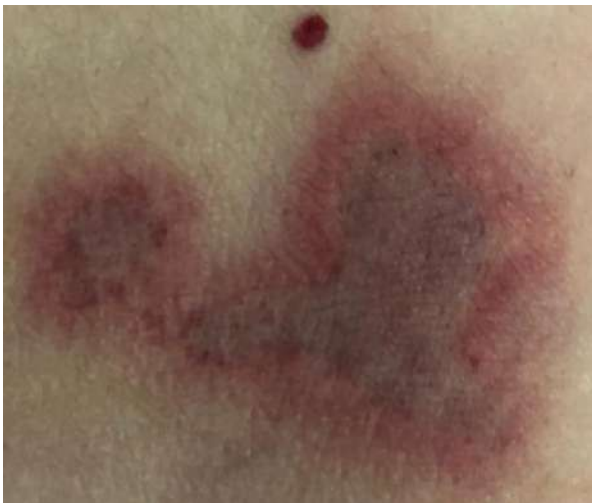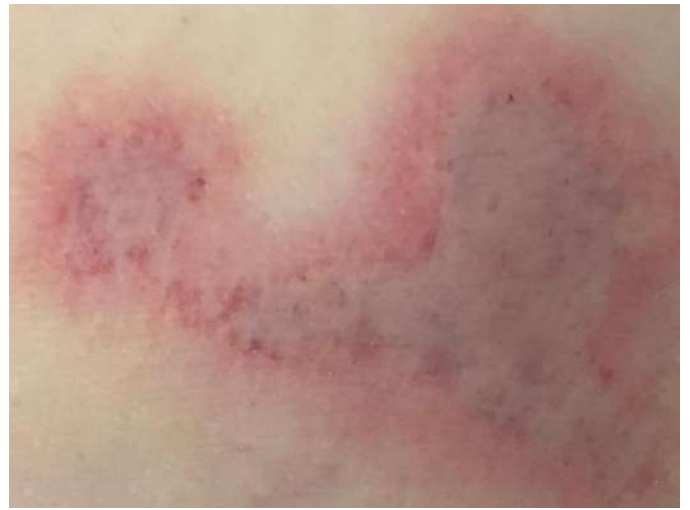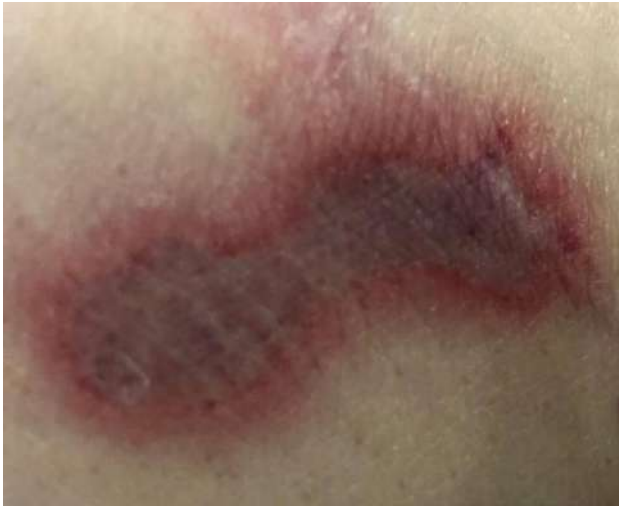## Livedoid or necrotic lesions - Confirmed cases



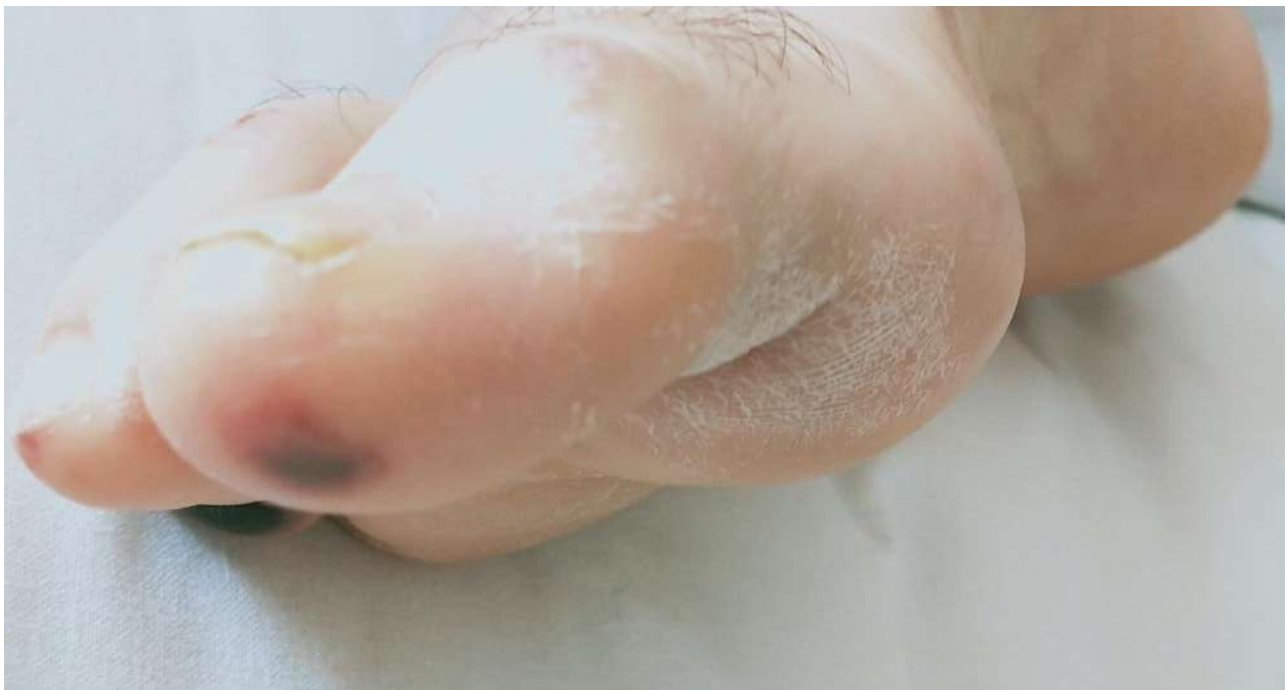
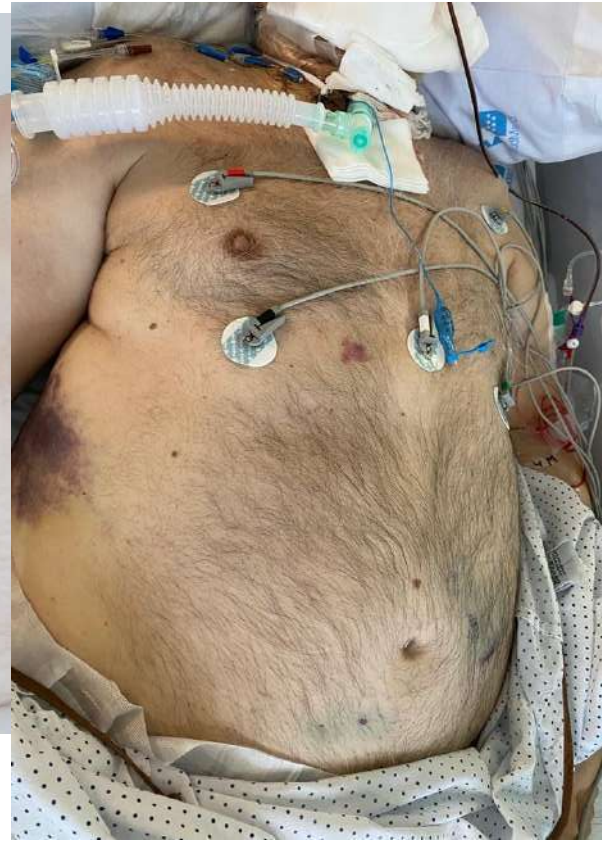
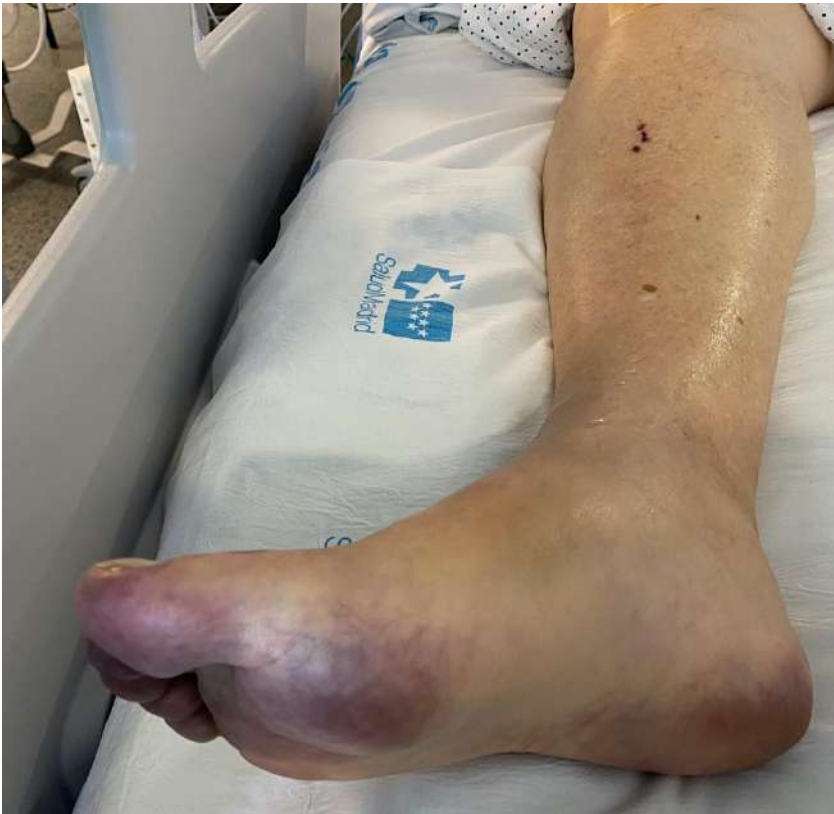use is forbidden



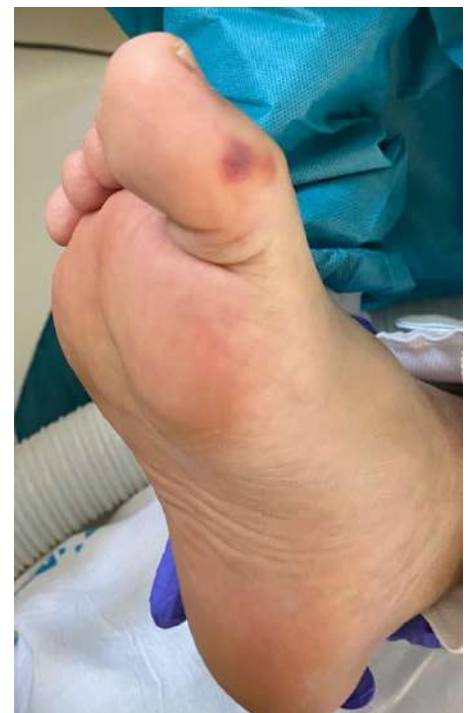
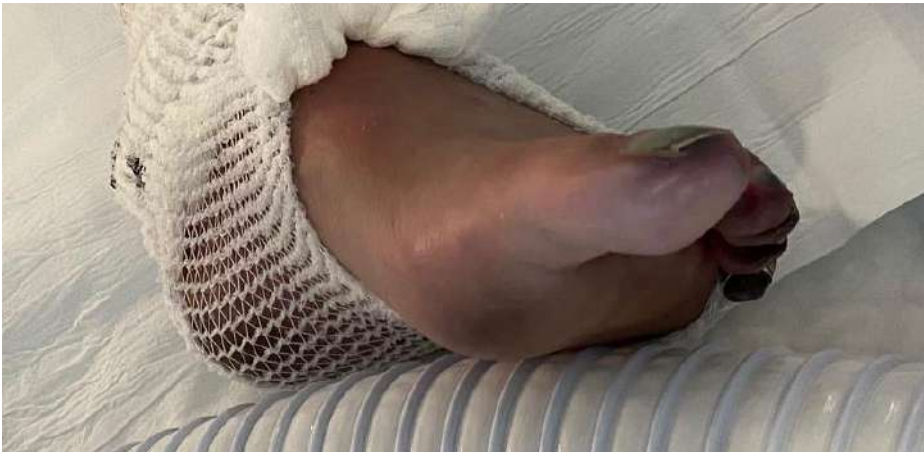
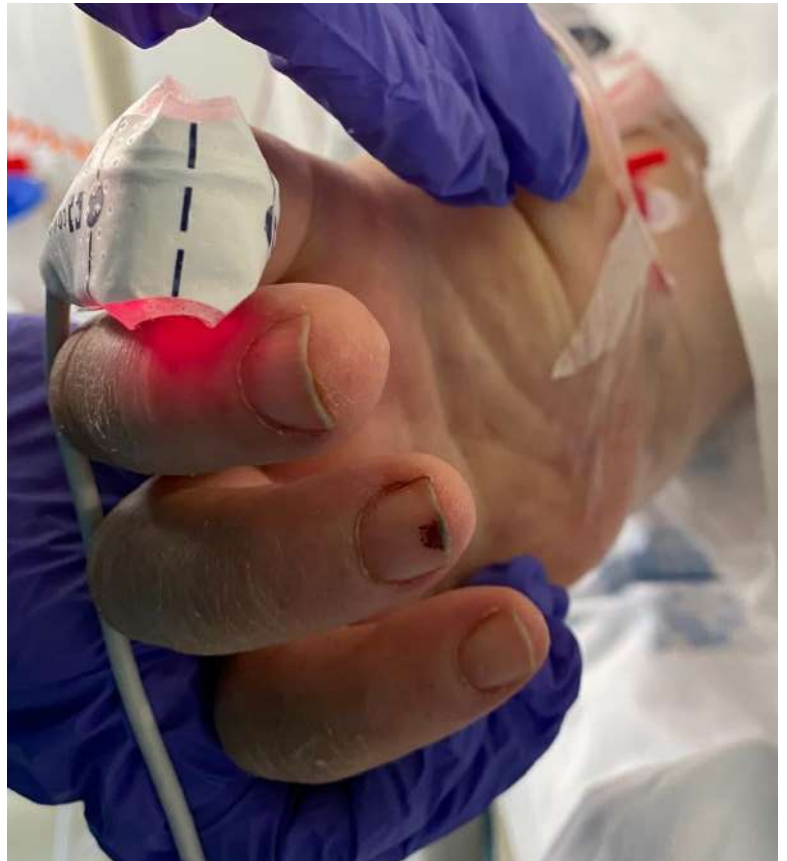
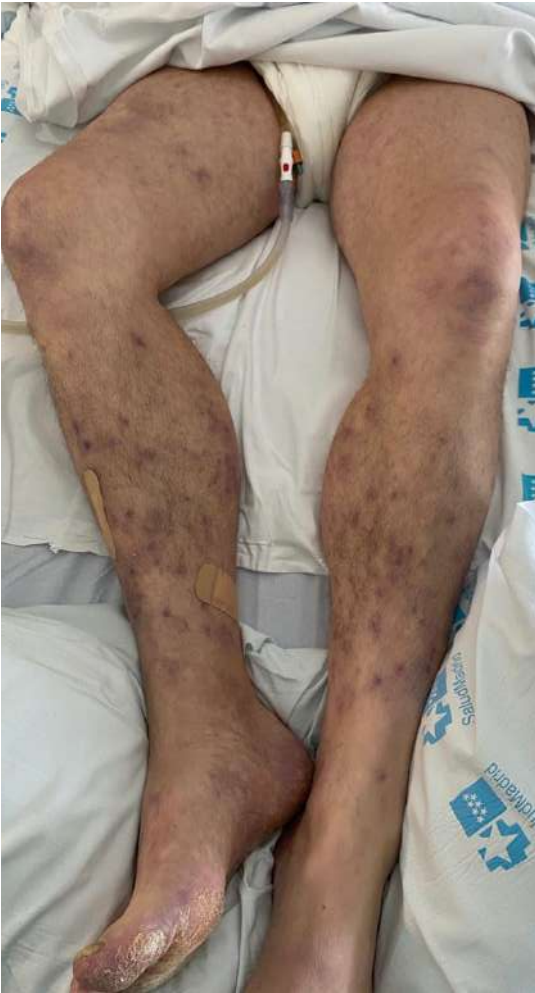


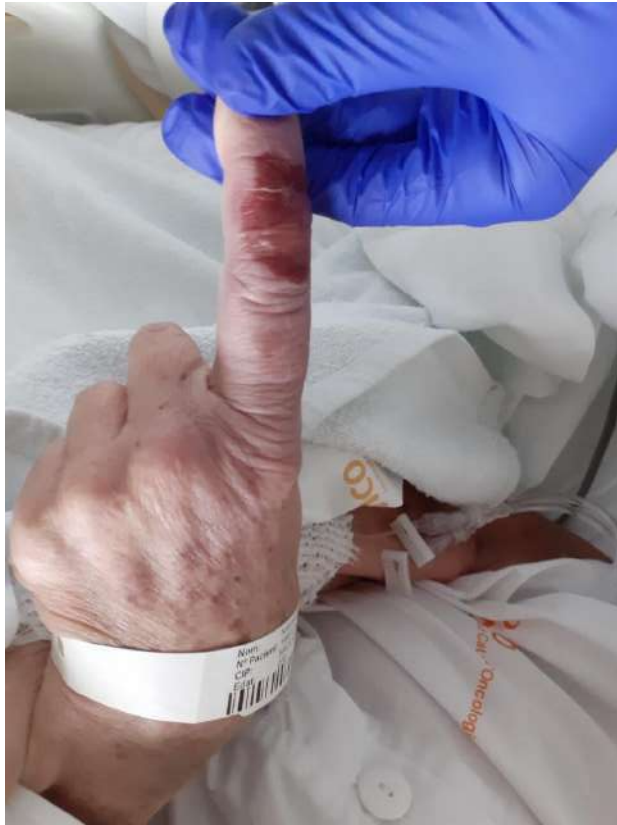

g. Any other use is forbidden.





## Livedoid or necrotic lesions - Suspected cases

